



Identification of Spinal Level Corresponding to Highest Point of Iliac Crest in Patients Undergoing Lower Lumbar Spinal Surgery- A Clinical, Radiological & Preoperative Observation

Authors

Dr Md. Sumon Rana¹, Dr Asifur Rahman², Dr Abu Saleh Mohammad Abu Obaida³,
Dr Robert Ahmed Khan⁴, Dr Md. Motasimul Hasan Shiplu⁵, Dr Ahsan Hafiz⁶,
Mohammad Shahnawaz Bari⁷, Muhammad Robiul Hoque⁸, Dr Md. Shafiqul Islam⁹,
Mohammad Afzal Hossain¹⁰

¹MBBS, MS(Neurosurgery), Assistant Professor, Department of Neurosurgery, Dhaka Medical College & Hospital, Dhaka

²MBBS, MS (Neurosurgery), Associate Professor, Department of Neurosurgery, Bangabandhu Sheikh Mujib Medical University, Dhaka

³MBBS, MS (Neurosurgery), Medical Officer, Department of Neurosurgery, Bangabandhu Sheikh Mujib Medical University, Dhaka

⁴MBBS, MRCS (ENG), MS (Neurosurgery), Medical Officer, Department of Neurosurgery, Bangabandhu Sheikh Mujib Medical University, Dhaka

⁵MBBS, MS (Neurosurgery), Assistant Professor, Department of Neurosurgery, Dhaka Medical College & Hospital, Dhaka

⁶MBBS, MS(Neurosurgery), Assistant Professor, Department of Neurosurgery, Uttora Adhunik Medical College & Hospital, Dhaka

⁷MBBS, MS(Neurosurgery), Medical Officer, Department of Neurosurgery, Bangabandhu Sheikh Mujib Medical University, Dhaka

⁸MBBS, Resident, Department of Neurosurgery, Dhaka Medical College & Hospital, Dhaka

⁹MBBS, MS (Neurosurgery), PHD, Associate Professor, Department of Neurosurgery, Dhaka Medical College & Hospital, Dhaka.

¹⁰MBBS, FCPS (Surgery), Professor & Ex Chairman, Department of Neurosurgery, Bangabandhu Sheikh Mujib Medical University, Dhaka

*Corresponding Author

Md. Sumon Rana

Abstract

Background: *The accurate identification of spinal level is a prerequisite for success and safety of spinal surgery. It may be done clinically by using anatomical landmarks or by using imaging techniques. Anatomical landmarks, including the scapula, ribs, highest point of iliac crest, and posterior superior iliac spine, have been used to assist in identifying specific vertebral levels in the spine. Race, sex, body mass index, height, posture greatly influence this relation. We usually use preoperative L/S spine X-ray to assess the spinal level corresponding to highest point of iliac crest. But after positioning for lower lumbar spinal surgery this spinal level usually changes. It is quite rational to assess the intercrystal line with its corresponding spinal level radiologically and preoperatively.*

Objective: *The aim of the study is to evaluate the changes in spinal level during surgery in comparison to preoperative radiological level.*

Method: *The cross-sectional study was carried out at the department of neurosurgery in Bangabandhu Sheikh Mujib Medical University from June 2013 till December 2014 among 45 patients. Study Population was including patients over 18 years of age undergoing lumbar region surgery.*

Results: *In our study, there were 31 (68.8%) males and 14 (31.2%) females. 26 (57.7%) patients had the age below 40 years and 19 (42.3%) patients had age above 40 years. Maximum patients (27%) were male and day labourer, having the disease in our study. Maximum patients (22) had spinal canal stenosis and only few patients (5) had PLID. Preoperative neurological problems like- sciatalgia, reflex changes, claudication, motor deficit, loss of sensation, sphincter dysfunction were found among patients which postoperatively recovered.*

Conclusion: *Selection of a high lumbar spinal level basically influence poor identification of the correct spinal level. The intercrestal line is connected with sex, height, weight, or BMI, although weight and BMI were found to have no correlation with the spinal level in this study. This research aided in lumbar spinal surgery by finding the spinal level that corresponds to the highest point of the iliac crest.*

Keywords: *Spinal level, Spinal surgery, Radiological level.*

Introduction

The accurate identification of spinal level is a prerequisite for success and safety of spinal surgery. It may be done clinically by using anatomical landmarks or by using imaging techniques. Spinal level identification by using anatomical landmarks is much more important when imaging techniques are not available. Tuffier's line has been the most popular and widely used landmark for rapid and easy identification of the lumbar intervertebral level. The line joining the superior aspect of the iliac crests posteriorly – variously described as the intercrestal, intercrystal, Tuffier's or Jacoby's line – is commonly stated to cross the midline at the L4 or L4–5 spinal level.

Race, sex, body mass index, height, posture greatly influence this relation. Specially in prone position in lumbar region surgery when we reduce the lumbar lordosis with hip flexion in different frames to gain easy excess to spinal canal this relation may be changed. Most of the study done in cadaver, in supine, sitting, lateral and prone position. Serial literature review shows that highest point of iliac crest with its corresponding spinal level determined by palpation is still not investigated in prone position and hip flexion posture, how we position the patient in lumbar spinal surgery.

We usually use preoperative L/S spine X-ray to assess the spinal level corresponding to highest point of iliac crest. But after positioning for lower

lumbar spinal surgery this spinal level usually change. Anatomical landmarks, including the scapula, ribs, highest point of iliac crest, and posterior superior iliac spine (PSIS), have been used to assist in identifying specific vertebral levels in the spine. (McGaugh et al., 2007). The line joining the superior aspect of the iliac crests posteriorly – variously described as the intercrestal (Kim et al. 2003b), intercrystal (Williams & Warwick, 1980), Tuffier's or Jacoby's line – is commonly stated to cross the midline at the L4 or L4–5 spinal level. This has been confirmed by several studies (Render 1996; Kim et al. 2003a, b; Jung et al. 2004) through analysis of lumbar spine images. Bony segmental levels at which Tuffier's line crosses the vertebral column are distributed in a normal fashion. However, palpating the upper iliac crests and drawing a line to join them seems to be an unreliable guide in determining the intervertebral space, with a tendency to be one or two spaces higher than assumed. (Jung et al., 2004)

Objective

To evaluate the changes in spinal level during surgery in comparison to preoperative radiological level.

Methods

Total Sample size based on above assumptions was 45 patients. Non- probability purposive sampling was done as per inclusion – exclusion

criteria. The cross sectional study will be carried out at the department of neurosurgery in Bangabandhu Sheikh Mujib Medical University from June 2013 till December 2014. Study Population include patients over 18 years of age undergoing lumbar spinal surgery admitted in the department of neurosurgery, Bangabandhu Sheikh Mujib Medical University during the above mentioned time. All patients will be admitted through outpatient department of Neurosurgery, Bangabandhu Sheikh Mujib Medical University will be included in the study after primary screening with inclusion and exclusion criteria.

History of the patient will be taken with demographic data. General examination with height, weight (for calculation of BMI) will be carried out preoperatively. Neurological examination will be carried out preoperatively. Preoperatively X-ray L/S Spine (A/P View in supine position) will be used to assess spinal level corresponding to highest point of the iliac crest (radiological correspondence) by drawing horizontal line across the superior aspects of both iliac crests. Spinal level will be identified by palpating highest point of iliac crest in prone position with hip flexion posture after induction of anesthesia & positioning and horizontal line with marker will be drawn with the help of scale followed by scratching with needle.

All data will be recorded in preformed data collection sheet. After ethical clearance for the study from the Department of Neurosurgery and Central Ethical Committee, Bangabandhu Sheikh Mujib Medical University, written informed consent will be taken from the patients and/or the legal guardian/responsible family members after completely explaining to them the procedure and the purpose of the study. Data will be processed and analyzed using IBM SPSS Statistics program (version 20.0). Statistical comparisons will be done using the following tests where p-value \leq 0.05 will be considered statistically significant.

Inclusion criteria

Adult patients between 20-80 years of age having following diseases in the lower lumbar spine

(L3to S1) admitted in BSMMU and private hospitals of Dhaka city needed surgery in prone position with hip flexion.

- PLID,
- Spinal tumor
- Spinal canal stenosis
- Arachnoid cyst

Exclusion criteria

The following patients was excluded from the study:

Lumber anatomy was potentially compromised by -

- Severe spinal scoliosis,
- Kyphosis
- Spondylolisthesis,
- Severe disc height reduction (disc height < 50% than above or below level)
- Sacralization,
- Lumbarization,
- Previous lower lumbar spinal surgery or
- Pot's diseases, Primary or secondary tumor of the vertebral body or osteoporosis with loss of vertebral body height.

Follow-Up

All patients were followed up at specific interval up to specific time period for individual disease for individual patient in OPD. Routine postoperative outpatient follow-up appointments were scheduled within one week, and then one month, three months, six months, and then every 1 year postoperatively.

Results

The patient's demographic characteristics are represented in the chart below (Table-1). There were 31 (68.8%) males and 14(31.2%) females. 26 (57.7%) patients had the age below 40 years and 19 (42.3%) patients had age above 40 years. History of the patients have been taken with the demographic data. And their general examination with height, weight (for calculation of BMI) have been carried out preoperatively. See the following table 1:

Table 1: Demographic data of the patients

Variables	Parameters	No of patients	Percentage
Age	<40	26	57.7%
	>40	19	42.3%
Sex	Male	31	68.8%
	Female	14	31.2%
BMI	Under Weight (<18)	7	15.5%
	Normal (18-24)	15	33.3%
	Over Weight (25-29)	12	26.7%
	Obesity G-I (30-34)	7	15.5%
	Obesity G-II (35-39)	3	6.7%
	Obesity G-III (>40)	1	2.3%
Surgical approaches	Bilateral fenestration and discectomy	6	13.3%
	Unilateral fenestration and discectomy	12	26.7%
	Laminectomy and discectomy	9	20%
	Laminectomy	7	15.5%
	Laminectomy and removal of tumour	8	17.7%
	Laminectomy and marsupialization of arachnoid cyst	3	6.7%

Figure 1 shows the distribution of occupation among the patients. Here, maximum patients (27%) were male and day labourer. In addition, a

high number of patients (20%) were service holders. And, maximum female patients (16%) were housewife.

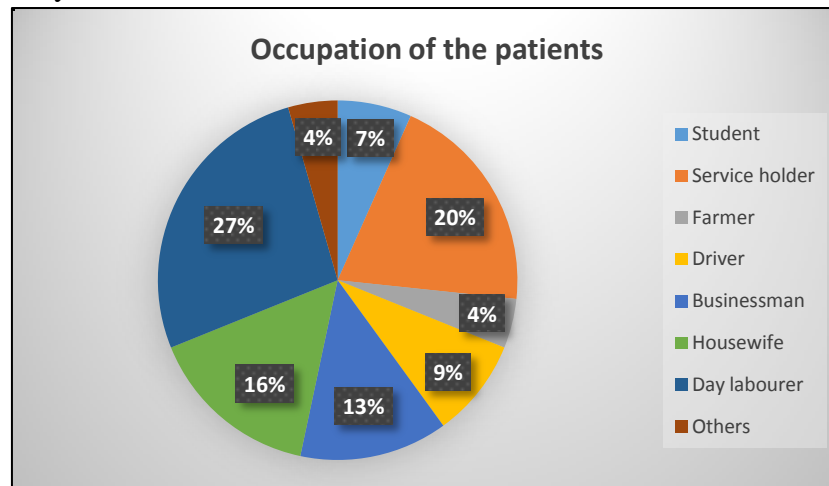


Figure 1: Distribution of occupation among patients.

The diagnosis report of the patients is shown in figure 2. In our study, maximum patients (22) had

spinal canal stenosis and only few patients (5) had PLID. See figure 2-

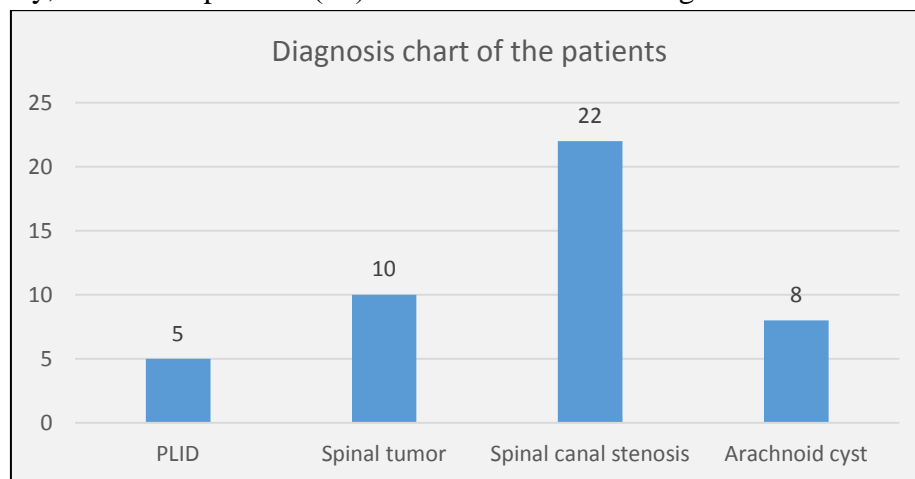


Figure 2: Diagnosis report of the patients.

In the table 2, the chart shows pre and postoperative neurological problems (sciatalgia, reflex changes, claudication, motor deficit, loss of sensation, sphincter dysfunction) found among total patients. Postoperatively maximum patients recovered from their neurological problems. See table 2-

Table 2: Preoperative and postoperative neural problems of the patients

Neurological problems	Preoperative	Postoperative
Sciatalgia	24	6
Reflex changes	12	3
Claudication	26	5
Motor deficit	7	2
Loss of sensation	18	4
Sphincter dysfunction	2	1

Discussion

Though it is well established that intercrestal line usually corresponds with L4 spine or L4/5 interspace but that was with imaging. Through palpation, the L3 spinous process and L3–4 interspinous spaces are most frequently identified at the level of highest point of iliac crest. But recent studies show that there is a remarkable variability in this relation. In prone position in lumbar spinal surgery when we reduce the lumbar lordosis with hip flexion in different frames to gain easy excess to spinal canal this relation may be changed. Most of the study done in cadaver, in supine, sitting, lateral and prone position. Serial available literature review shows that highest point of iliac crest with its corresponding spinal level determined by palpation is still not investigated in prone position and hip flexion posture, how we position the patient in lumbar spinal surgery. We usually use preoperative L/S spine X-ray to assess the spinal level corresponding to highest point of iliac crest. But after positioning for lower lumbar spinal surgery this spinal level usually change. We asseses the age to see any relation between the age changes and spinal level corresponding to highest point of iliac crest both in L/S spine radiograph and preoperatively, sex to see the variations in spinal level corresponding to highest point of iliac crest

with sex. And the BMI to see variation and spinal level with BMI, the preoperative X-ray L/S Spine (A/P View), spinal level corresponding to highest point of the iliac crest (radiological correspondence).

In our perspective, many times we used to do lower lumbar spinal surgery, specially discectomy without the help of peroperative x-ray or c-arm and wrong level surgery sometimes happen. So in our perspective, it is quite rational to assess the inter crestal line with its corresponding spinal level radiologically and peroperatively, how we estimate spinal level peroperatively in patients in prone position with hip flexion by palpating highest point of iliac crest. In the clinical situation, however, using palpation of bony landmarks as a guide, it has been demonstrated that identification of the exact spinal level is frequently inaccurate (Van Gessel et al., 1993, Broadbent et al., 2000) Furness et al. 2002). The inability to consistently identify specific levels in the lumbar spine may be due, in part, to the fact that the location of iliac crest reference line is quite variable between subjects. (McGaugh et al., 2007)

Following study shows there is wide variations of corresponding spinal level considering highest point of iliac crest in respect to age, sex, height, weight, obesity, BMI, race. Tuffier's line, which joins the iliac crests, was an unreliable guide in determining the level of needle insertion into the vertebral column and attributed this to the bony abnormalities or deformities likely in their elderly patients. (Van Gessel et al., 1993). Adult females who have more percentage body fat for equivalent BMIs, different fat distribution and who develop progressively greater waist to hip ratios with age than adult males were found to have proportionately more higher levels identified on palpation (Gallagher et al., 1996). The iliac crest reference line was more inferior in female subjects when compared to males, and more superior in older subjects when compared to younger subjects. (McGaugh et al., 2007) A palpated intercrestal line at L2-3 was more likely in tall and male individuals (Pysyk et al., 2010)

Because the clinical use of Tuffier's line requires palpation through a variable amount of subcutaneous fat, the landmark will be even more variable than that found by x-ray and dissection, and high placement is especially likely in the obese (Hogan, 1994). Factors that have been shown to influence poor identification of the correct spinal level include selection of a high lumbar spinal level and obesity (Broadbent et al. 2000; Furness et al. 2002). The level of the intercrestal line is associated with sex, height, weight or BMI and was found that weight and BMI had no correlation with the intercrestal line (Snider et al., 2008). Further inaccuracies in identification of the correct spinal level might be expected if there were sacralization or lumbarization of the lower spine (prevalence 8–15%) (Horduna and Legaye, 2008), spondylolisthesis (prevalence up to 6%) (Beutler et al., 2003), lumbar scoliosis or loss of vertebral height. A strict relation was observed between this projection of the intercrestal line and the sagittal pelvic anatomical angles. The greater the pelvic incidence, the higher the intercrestal line was projected, all the more in patients with spondylolysis with a listhesis or a disc narrowing. (Horduna and Legaye, 2008)

Conclusion

In this study, we found that selection of a high lumbar spinal level basically influence poor identification of the correct spinal level. The intercrestal line is connected with sex, height, weight, or BMI, although weight and BMI were found to have no correlation with the spinal level in this study. This research aided in lumbar spinal surgery by finding the spinal level that corresponds to the highest point of the iliac crest. Further research can help to find more factors relating to this evaluation of correct spinal levels.

Conflict of Interest

There is no potential conflict of interest relevant to this research.

Financial Disclosure

No specific funding was provided for this research.

Patient Consent

This study obtained patient consent directly from the patient.

Author's Contributions

The author's contributions include manuscript preparation and editing. The manuscript has been prepared and approved by all the authors to be submitted and published.

References

1. BEUTLER, W. J., FREDRICKSON, B. E., MURTLAND, A., SWEENEY, C. A., GRANT, W. D. & BAKER, D. 2003. The natural history of spondylolysis and spondylolisthesis: 45-year follow-up evaluation. *Spine (Phila Pa 1976)*, 28, 1027-1035
2. BROADBENT, C. R., MAXWELL, W. B., FERRIE, R., WILSON, D. J., GAWNE-CAIN, M. &
3. RUSSELL, R. 2000. Ability of anaesthetists to identify a marked lumbar interspace. *Anaesthesia*, 55, 1122-6.
4. FURNESS, G., REILLY, M. P. & KUCHI, S. 2002. An evaluation of ultrasound imaging for identification of lumbar intervertebral level. *Anaesthesia*, 57, 277-80.
5. GALLAGHER, D., VISSER, M., SEPULVEDA, D., PIERSON, R. N., HARRIS, T. & HEYMSFIELD, S. B. 1996. How useful is body mass index for comparison of body fatness across age, sex, and ethnic groups? *Am J Epidemiol*, 143, 228-39.
6. HOGAN, Q. H. 1994. Tuffier's line: the normal distribution of anatomic parameters. *Anesth Analg*, 78, 194-5.
7. HORDUNA, M. & LEGAYE, J. 2008. Influence of the sagittal anatomy of the pelvis on the intercrestal line position. *Eur J Anaesthesiol*, 25, 200-5.

8. JUNG, C. W., BAHK, J. H., LEE, J. H. & LIM, Y. J. 2004. The tenth rib line as a new landmark of the lumbar vertebral level during spinal block. *Anaesthesia*, 59, 359-63.
9. KIM, J. T., BAHK, J. H. & SUNG, J. 2003a. Influence of age and sex on the position of the conus medullaris and Tuffier's line in adults. *Anesthesiology*, 99, 1359-63.
10. MCGAUGH, J. M., BRISMEE, J. M., DEDRICK, G. S., JONES, E. A. & SIZER, P. S. 2007. Comparing the anatomical consistency of the posterior superior iliac spine to the iliac crest as reference landmarks for the lumbopelvic spine: a retrospective radiological study. *Clin Anat*, 20, 819-25.
11. PYSYK, C. L., PERSAUD, D., BRYSON, G. L. & LUI, A. 2010. Ultrasound assessment of the vertebral level of the palpated intercrystal (Tuffier's) line. *Can J Anaesth*, 57, 46-9.
12. RENDER, C. A. 1996. The reproducibility of the iliac crest as a marker of lumbar spine level. *Anaesthesia*, 51, 1070-1.
13. SNIDER, K. T., KRIBS, J. W., SNIDER, E. J., DEGENHARDT, B. F., BUKOWSKI, A. & JOHNSON, J. C. 2008. Reliability of Tuffier's line as an anatomic landmark. *Spine (Phila Pa 1976)*, 33, E161-5.
14. VAN GESSEL, E. F., FORSTER, A. & GAMULIN, Z. 1993. Continuous spinal anesthesia: where do spinal catheters go? *Anesth Analg*, 76, 1004-7.
15. Williams PL, Warwick R (Eds) (1980) *Gray's Anatomy*, 36th Edn. Edinburgh: Churchill Livingstone.