



Study of Perineural Invasion in Prostatic Carcinoma

Authors

Dr Alvin Vincent¹, Dr Sankar S², Dr Sheeja S³

¹Junior Resident, Department of Pathology, Government Medical College, Kottayam, Kerala, India

²Professor and HOD, Department of Pathology, Government Medical College, Kottayam, Kerala, India

³Associate Professor, Department of Pathology, Government Medical College, Kottayam, Kerala, India

Abstract

Background: Prostatic carcinoma is the most common cancer in elderly men and 75-80% occur in peripheral zone. It is diagnosed by architectural, nuclear, cytoplasmic and intraluminal features. Perineural invasion is one of the pathognomonic histological features of adenocarcinoma and its significance was studied.

Objectives

Primary Objective

1. To describe perineural invasion in prostatic carcinoma.
2. To identify proportion of patients with perineural invasion having metastatic prostatic carcinoma.
3. To find out the association of perineural invasion and metastatic prostatic carcinoma.

Secondary Objective

1. To describe the use of S100 expression in enhancing detection of perineural invasion by demonstration of nerves.

Methods:

Study Design : Cross sectional analytical study

Study Population: Study sample includes all the cases of prostatic carcinoma biopsy specimens received in the Department of Pathology during the study period.

Sample Size : 155

Sampling Procedure : Continuous sampling

Results and Discussion: The mean age of the study population was 68.72 years. The predominant Gleason score was 7 in 40.5% of cases, 4+3 and 3+4 respectively. Perineural invasion was found in 46% cases. PNI was seen in 57% of Gleason scores 8-10 and 35% in Gleason score 7. PNI and its association with metastatic prostate carcinoma had weak positive relationship between the two variables. 51% of cases showed PNI by S100 immunohistochemistry.

Conclusion: In the present study, perineural invasion was found in 46% of the biopsy specimens and was associated with higher grade prostatic carcinomas. The significance of PNI in metastatic prostate carcinoma could not be proved as there was only weak positive relationship between PNI and metastatic prostatic carcinoma. Our data showed 5% increase in detection of PNI which suggested that detection of perineural invasion may be enhanced by S100 immunohistochemistry.

Keywords: Prostatic carcinoma, Perineural invasion, metastasis, Gleason score, PSA, S100.

Introduction

Prostatic carcinoma is the most common cancer in 84 countries¹. Perineural invasion (PNI) is a major mechanism of prostate cancer extension from prostatic parenchyma to periprostatic soft tissue,

perineural invasion extensive enough to be sampled on needle biopsy may signal an increased likelihood of extraprostatic extension of cancer or ultimately of cancer recurrence². Prostatic carcinoma with perineural invasion had

significantly more core specimens involved with tumor and higher biopsy Gleason scores than those without invasion³. For many of the malignancy, PNI is a marker of poor outcome and a harbinger of decreased survival⁴.

For a pathologist diagnosis of prostatic adenocarcinoma is often a diagnostic dilemma when biopsy bits are small. PNI has been a time honoured morphological criteria. Gleason Grade and Sum, since their introduction in 1993, have been used by pathologists to grade adenocarcinoma of prostate and prognosticate its treatment. It is based on glandular architecture only. PNI has been a hallmark in making diagnosis⁵. According to review, clinicians currently have few factors that help to predict recurrence, prognosis or bone metastasis in men with prostate cancer. In addition to Gleason score, some research has suggested that PNI in the prostate specimen may indicate a potential for metastasis of the disease⁶.

The serum level of PSA is related to prognosis in prostatic carcinoma, as an indirect indicator of tumor volume, tumor extension and response to therapy⁷.

In the study conducted by Alexandre de la Taille et al PNI was identified in 24% of the patients and concluded that PNI is an important preoperative predictor of pathological stage and should be reported when adenocarcinoma is diagnosed on prostate needle biopsies⁸.

In the study conducted by Kevin A Kurtz et al, S100 stained slides were especially useful for finding nerves with small diameters embedded within the tumor. In comparison with careful examination of H&E slides for perineural invasion, reviewing S100 stained sections may be easier and more detectable. The primary reason for enhanced detection was the sharp contrast between S100 stained nerves and the hematoxylin counter stain allowing low power detection of perineural invasion⁹.

Objectives

Primary Objective

1. To describe perineural invasion in prostatic carcinoma
2. To identify proportion of patients with perineural invasion having metastatic prostatic carcinoma.
3. To find out the association of perineural invasion and metastatic prostatic carcinoma.

Secondary Objective

1. To describe the use of S100 expression in enhancing detection of perineural invasion by demonstration of nerves.

Methodology

Type of Study: Cross sectional analytical study

Study Period: 18 months (December 2017-June 2019)

Study Setting: Department of Pathology, Govt. Medical College, Kottayam.

Sample Size: 155

Study Population: All prostatic core needle biopsies diagnosed as prostatic carcinoma in Department of Pathology, Government medical college, Kottayam during study period.

Inclusion Criteria

All prostatic needle biopsies diagnosed as prostatic carcinoma.

Exclusion Criteria

Radical prostatectomy specimens, TURP specimens.

Study Tools

1. Instruments to take bits of tissues to be studied.
2. Reagents for tissue processing.
3. Instruments for making paraffin blocks and cutting thin sections from it.
4. Gleason score
5. Eosin- Haematoxylin staining.
6. S100 for immunohistochemical study
7. Detailed Proforma for each case

Study Procedure

Clinical and pathological details of each cases will be recorded as in the profoma. All specimens will be fixed in formalin & embedded in paraffin. Sections will be taken from paraffin embedded blocks and stained with H&E for routine examination. IHC will be performed using S100 on prostatic biopsies and will be evaluated. Only histopathologically proven cases of prostatic carcinoma will be taken for IHC. Written informed consent from each patient will be taken before collecting details, scan reports.

Data Management and Analysis

The data was entered in Microsoft excel and results were expressed as mean, frequency, proportions, Correlation between different variables and association between PNI and metastatic prostatic cancer.

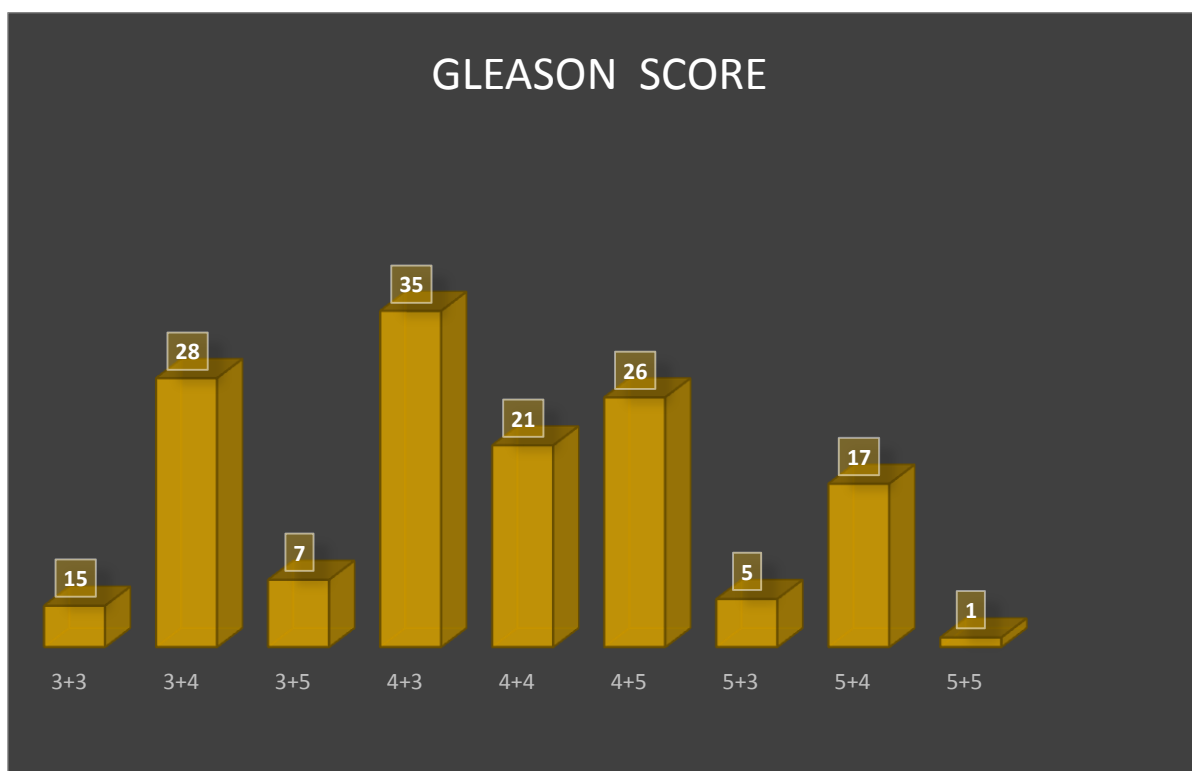
Results

The total number of prostatic biopsies studied during the period of 18 months was 155.

Gleason Score

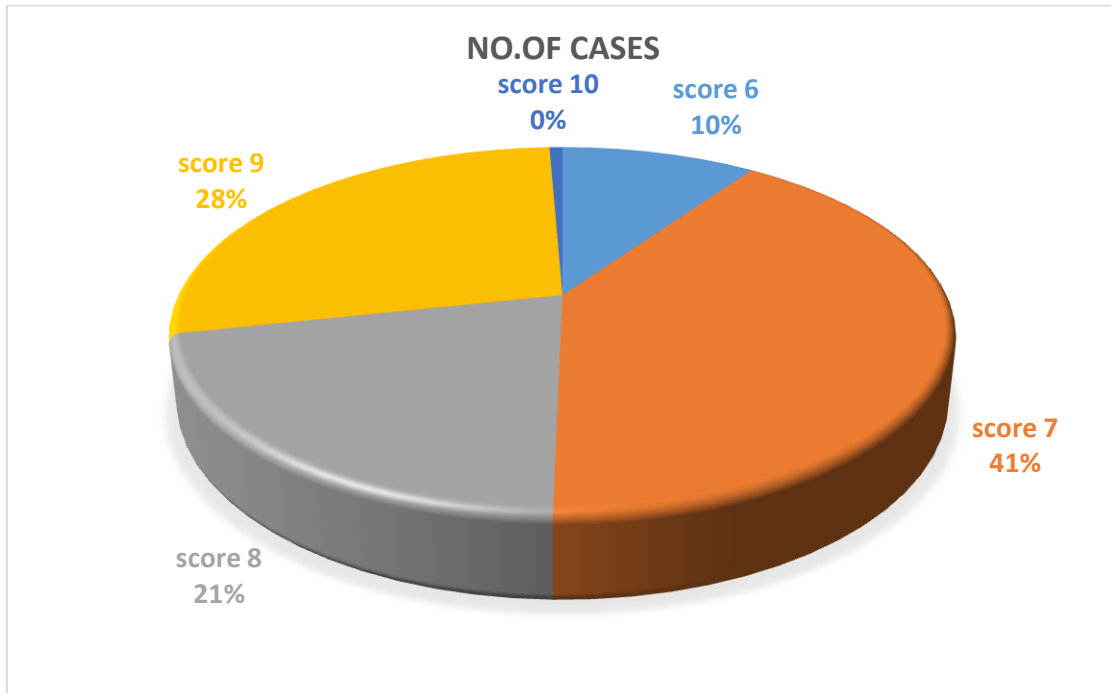
Distribution of various Gleason scores

Gleason score pattern	No. of patients	Percentage (%)
3+3	15	10
3+4	28	18
3+5	7	4.5
4+3	35	22.5
4+4	21	13.5
4+5	26	17
5+3	5	3
5+4	17	11
5+5	1	0.5
Total	155	100%



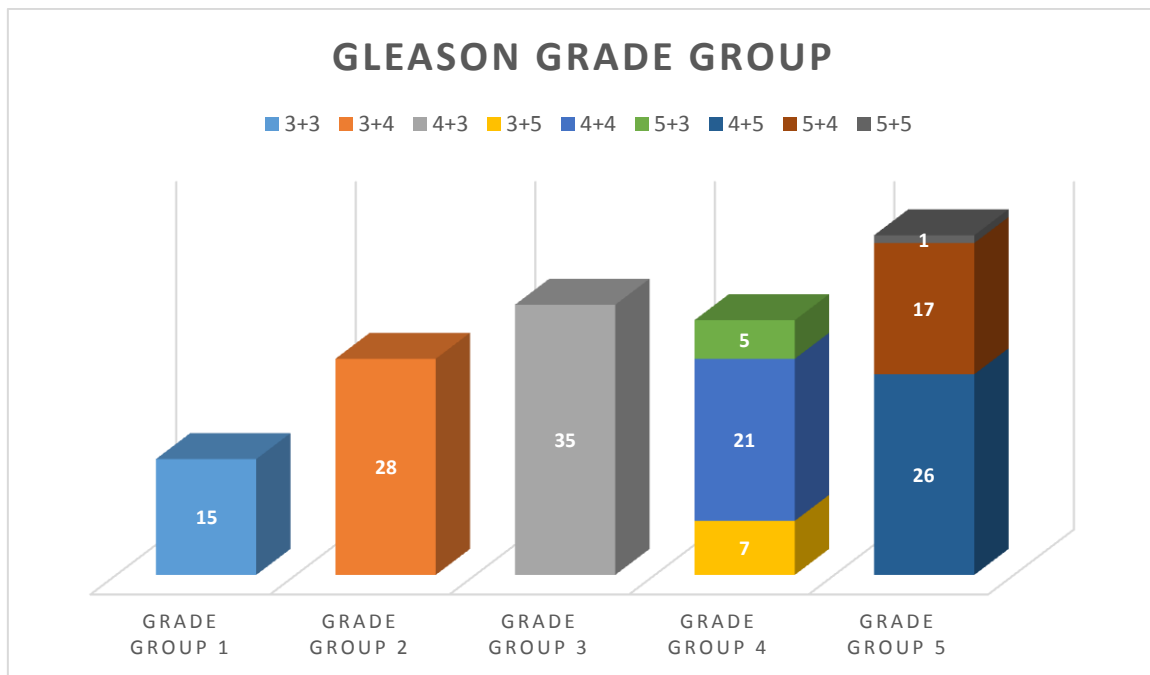
Distribution of study group according to Gleason patterns

The predominant pattern is 4+3 followed by 3+4 that is score 7 predominates which are 22.5% and 18% respectively followed by score 9 and score 8.

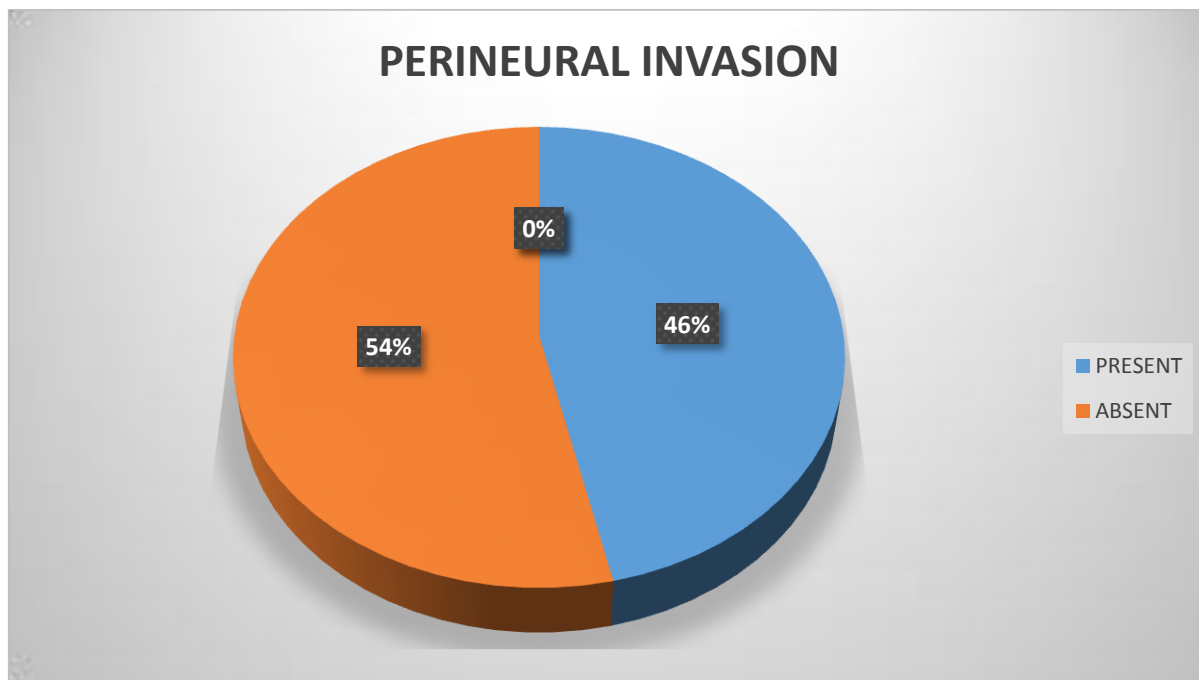


**Gleason grade group
Distribution of 5 grade groups**

Grade group	frequency	Percentage
1	16	10%
2	28	18%
3	35	23%
4	33	21%
5	44	28%
Total	155	100%

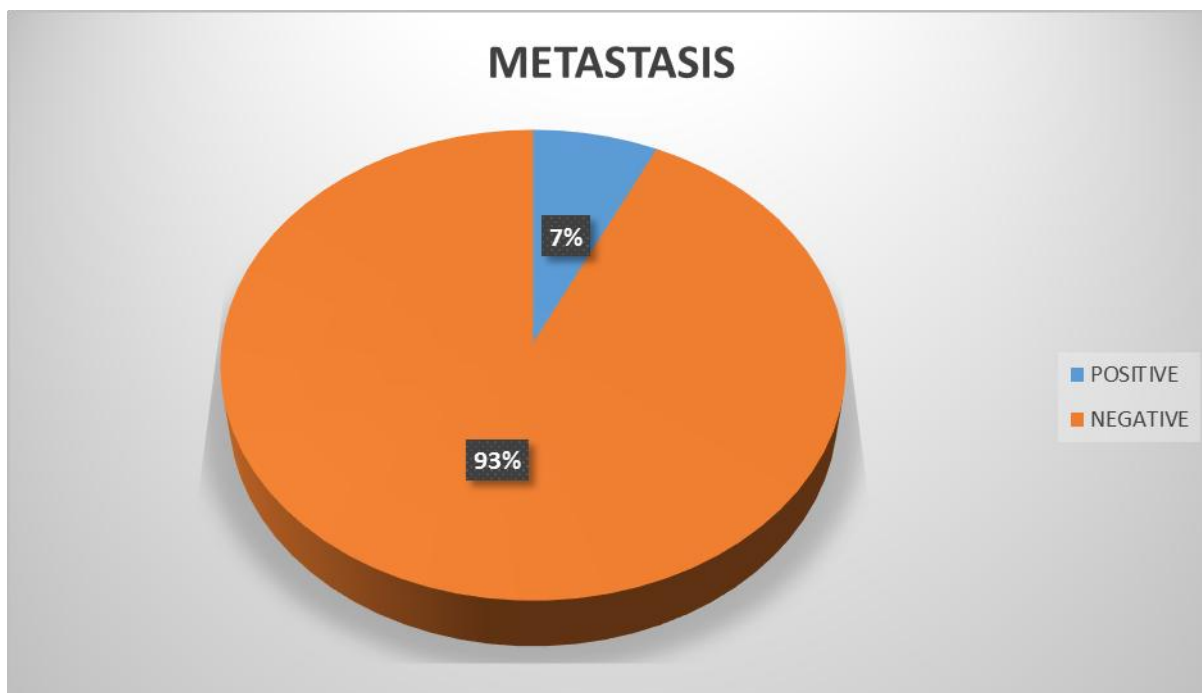


Perineural Invasion

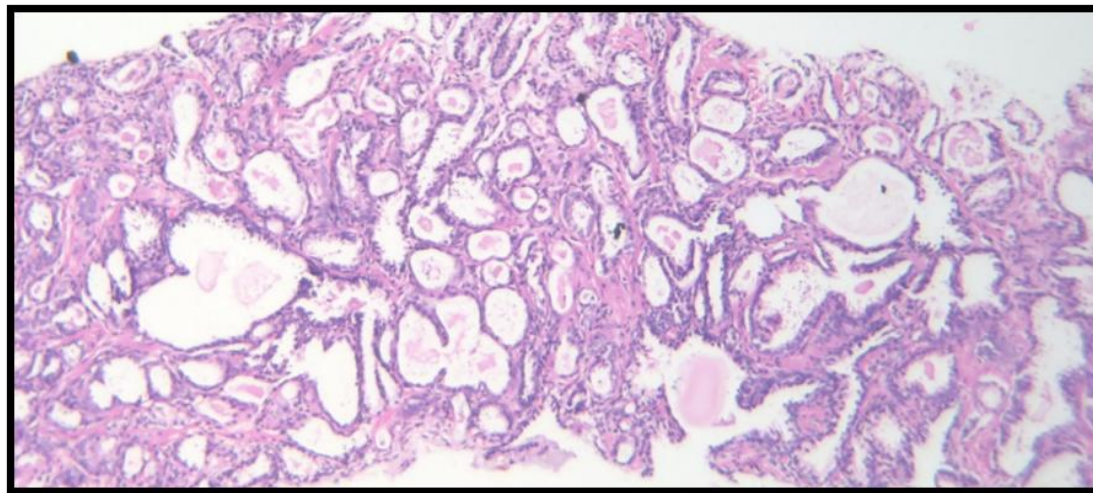
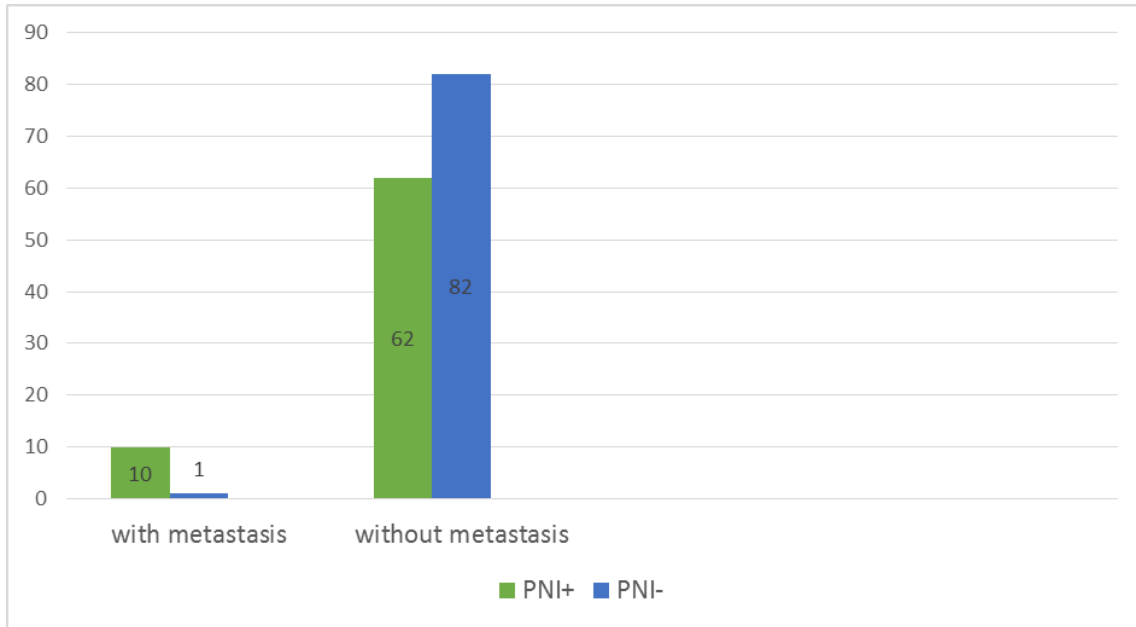


Distribution of PNI in study population

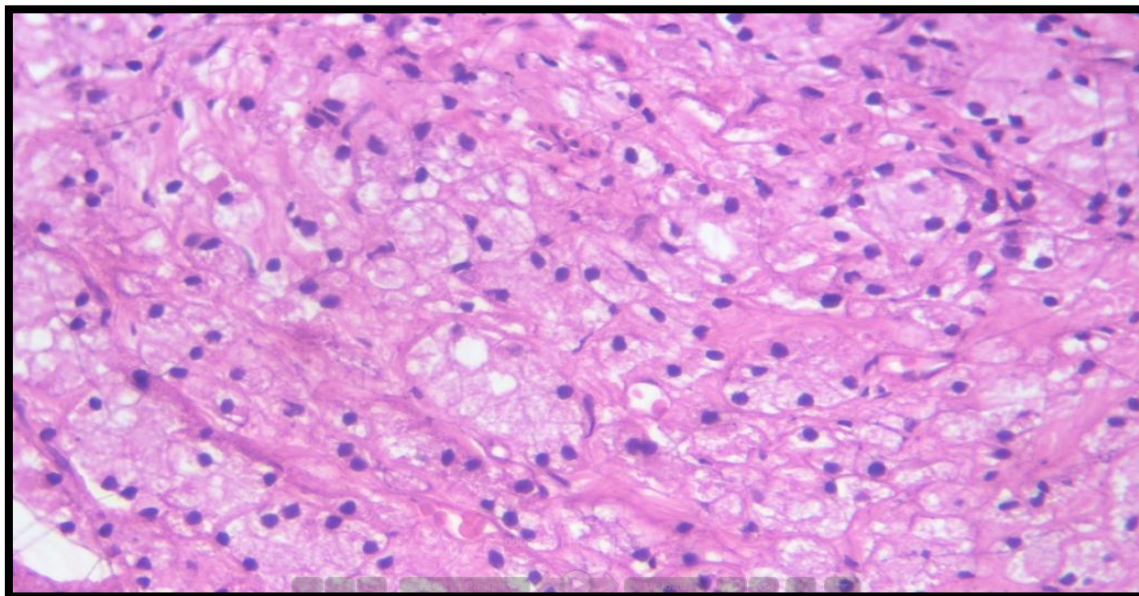
Prostatic Carcinoma Patients with Metastasis



Correlation between Metastatic Prostatic Carcinoma Patients and Perineural Invasion



Gleason score 7(4+3)-H&E-100X



Foamy gland variant-H&E-400X

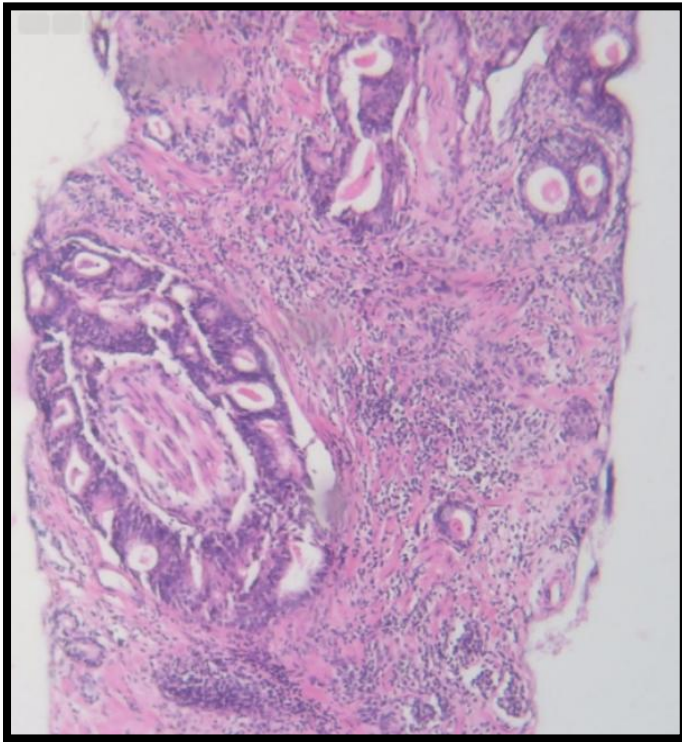


Figure 25: Perineural invasion-H&E-100X

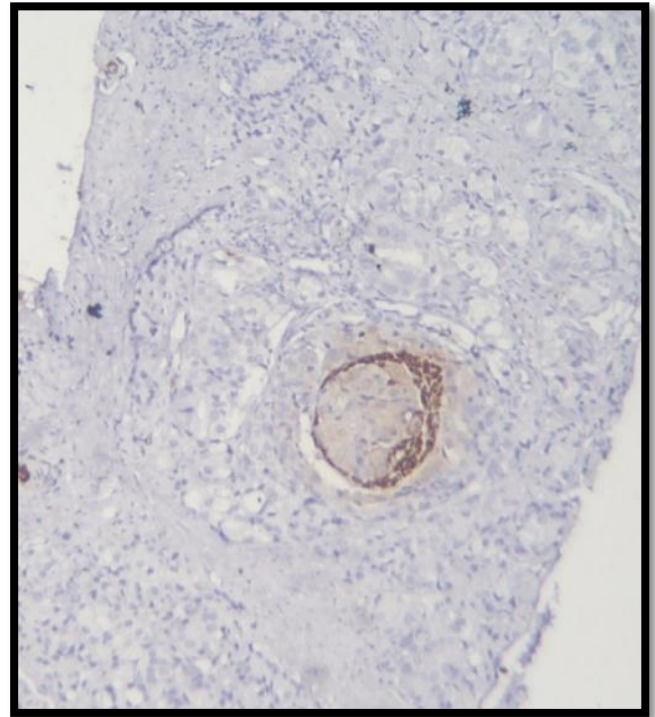


Figure 27: S100 immunostaining demonstrating Perineural invasion-H&E-100X

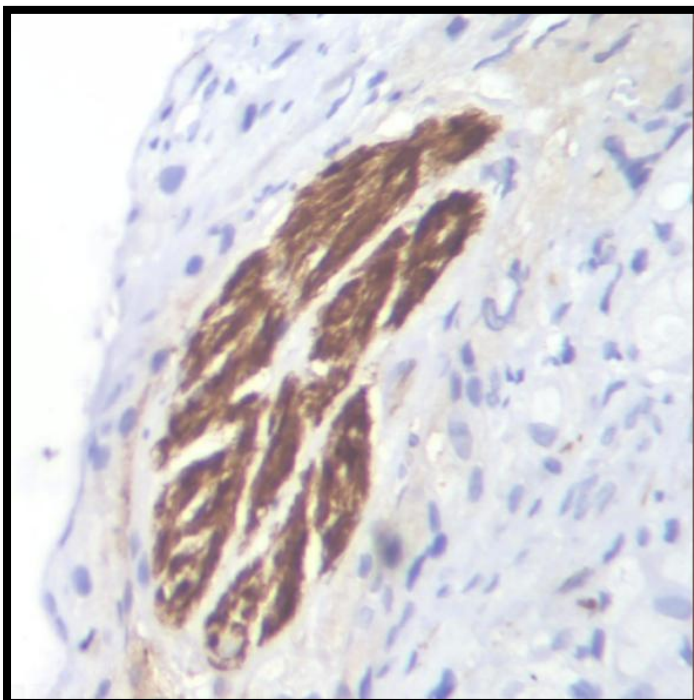

Figure 26: S100 immunostaining of nerves-H&E-400X

Discussion

Prostatic needle biopsies play a central role in the diagnosis of prostate cancer and prediction of outcome.

This study was undertaken to evaluate various clinical presentations, Gleason score and perineural invasion in prostate cancer. The present study was conducted on 155 cases of prostatic carcinoma whose needle biopsy specimens was received in the Department of Pathology, Government medical college Kottayam.

Clinical Presentation

Prostate cancer incidence and mortality rates are strongly related to the age with the highest incidence being seen in elderly men (> 65 years of age).

The age of the patients in our study ranged from 41 years to 93 years with predominant affected population belonging to age groups between 61-70 years and 71-80 years accounting for about 39.4% and 36% respectively. The mean age of our study was 68.72 years and is comparable to study conducted by Garget al¹⁰ and Barakzai et al.¹¹

In the present study, 93% patients had urinary symptoms and 7% had other non specific symptoms such as low backache.

Histopathology

In the present study, 155 cases of prostatic adenocarcinoma were studied which included only acinar type. In the study conducted by Baig et al, the major proportions of prostate carcinomas are acinar adenocarcinoma, although several rare histologic variants coexists¹² The architectural features studied included normal benign glands, crowding of small neoplastic glands, fused glands and poorly formed glands along with neoplastic cells forming sheets.

Cellular features include nuclear enlargement, nuclear pleomorphism, prominent nucleoli and cytoplasmic amphophilia.

PSA Values

The general cut off value for PSA is 4.0ng/ml. A higher PSA level may relate to a greater likelihood of positive tissue diagnosis, a higher Gleason score, and a greater likelihood of bone metastasis.¹³

In the present study, majority of the cases showed PSA values above 25ng/ml that is about 85% (47% had PSA>100 and 37% had values between 25-100) while 11% cases had values between 10.1 and 25, 4% cases with values between 4.1 and 10 and 1% cases with PSA value <4ng/ml. Only 1% cases had values less than normal cut off range.

Our study had 11 cases of metastatic prostatic adenocarcinoma, 10 cases had PSA values above 100ng/ml and one case below 100ng/ml.

Gleason Score

Gleason grading system is the most widely used system for grouping prostatic adenocarcinoma.

In the present study, Gleason score of 7(4+3 and 3+4) was seen predominantly constituting about 22.5% and 18% respectively. According to the study conducted by Ian Hosein et al, moderately differentiated tumours that is score of 7 was the most common accounting for about 45.6%.¹⁴A

score of 9 showed 28%, score of 8 was 21%, score 10 was 0.5% and score 6 (well differentiated) constituted 10% of the cases. Many other studies also highlight score 7 as the predominant score.¹⁵

Based on ISUP grade grouping, our study showed that the predominant grade group was grade group 5 followed by grade group 3 and grade group 4 constituting 28%,23% and 21% respectively.

Perineural Invasion

Perineural invasion is one of the prominent histological feature in prostatic adenocarcinoma. The presence of PNI varies from 20% to 38% in prostate needle biopsy specimens.

In our study PNI was found in 46% of the total cases which is comparable with the study conducted by Garg¹⁰ et al that is 42.5% and study by Ravery³ et al showed PNI in 47% of the cases. A few of the other studies showed lower incidence of PNI in biopsies like Bastacky¹⁶ et al and Sara O Vargas³ et al which was 20% and 16.8% respectively which was less than our present study.

In the present study, perineural invasion is associated with score 7 in 35%, score 9-10 in 33%, score 8 in 24% and score 6 in 8%. Thus PNI is associated with higher grade prostatic carcinoma which is similar to the study conducted by Sara o Vargas et al.³

Distribution of perineural invasion in different grades of prostatic carcinoma by tumour differentiation

PNI is significantly associated with high grade prostatic carcinoma that is 57% in scores 8-10 (poorly differentiated) and 35% in score 7 (moderately differentiated) cancers which is comparable to the study by Sara O Vargas et al where PNI in the biopsy specimen was significantly associated with a higher gleason score and had a mean gleason score value of 6.8.³

Correlation between PNI and PSA

In our study, 83% (60 cases) of cases with PNI had PSA>25ng/ml, 11% of cases had PSA between 10.1-25ng/ml, 4% of cases had PSA between 4-10ng/ml and 2% of cases had PSA

value less than 4ng/ml. Thus 17% (12 cases) of the cases had PSA<25ng/ml.

Proportion of cases with PNI having metastasis

Among 72 cases with PNI, 10 cases(13.8%) had metastasis while 86.2% cases had no metastasis. Since our study is a cross sectional study and less number of cases, the significance of PNI in mPCa (metastatic prostatic carcinoma) could not be studied in detail. The study by Zhao J et al also concluded that the prognostic role of PNI differed among different prognostic groups which was conducted on 515 cases with de-novo bone metastatic PCa and the study population was classified into 3 prognostic groups-favourable, intermediate and poor-risk group. Multifocal PNI could independently predict the survival outcomes of favourable/intermediate risk group but was not a risk factor for poor risk group. Thus PNI should be routinely described to avoid the potential chance of disease underestimation of these patients.¹⁷

Association between Perineural invasion and metastasis

Table 15: Metastasis*Perineural invasion Cross tabulation

	PNI+	PNI-	Total
With metastasis	10	1	11
Without metastasis	62	82	144
Total	72	83	155

From the cross tabulation matrix, we can see that metastatic prostatic carcinoma patients is likely to have an association with perineural invasion as 91% of the cases with metastasis had PNI. This association was evaluated by chi square test.

The association between metastatic prostate carcinoma and PNI was checked using Chi square test. The test gave a chi square value of 9.408 and p value 0.0021. Since our chi square value is 9.408 which exceeded the table value of 3.84 at 1 degree of freedom and one of our observed value is 1(that is less than 5),we performed Fisher's exact test. This test gave a p value 0.0029.Since p value was less than 0.05, it can be stated that both variables are associated. But in our study, cases

with metastases is less, that is, only 11 cases and 43% of the cases without metastasis had PNI, the association of PNI could not be proved. The strength of association was further assessed by Phi statistics. The Phi statistics obtained was 0.246 and thus observed that there is only weak positive relationship between metastasis and PNI.

Comparison of Detection of PNI by Demonstration of Nerves Using S100 Immunohistochemistry in Other Studies

In the present study, 79 cases (51%) showed PNI which was detected by S100 staining while the remaining 76 cases(49%) had no PNI.

Nerves were defined as bundles of at least several S100 positive cells with fascicular configuration while scattered individual S100 positive cells were excluded as they may represent dendritic cells.¹⁸

By routine H&E 46% of cases that is 72 out of total 155, showed PNI. Thus using S100 increase the detection of PNI by 5% which is similar to the study conducted by Aufranc et al.¹⁹ But several other studies by Zhou M et al did not show enhanced detection of PNI by S100.¹⁸

Limitations of the Study

1. The study population was comparatively low.
2. The identification of PNI in H&E slides can be subject to interobserver variation.

Conclusion

- In our study, Perineural invasion was found in 46% of the biopsy specimens diagnosed as prostatic carcinoma.
- Among 72 cases with PNI, only 10 cases (13.8%) had metastases while 86.2% cases had no metastasis.
- PNI is seen in 57% in cases with Gleason scores 8-10(poorly differentiated) and 35% in Gleason score 7(moderately differentiated) cancers. Thus PNI is associated with higher grade prostatic carcinoma.

- In the present study, we observed that there is only weak positive relationship between metastatic PCa and PNI. So, the significance/association of PNI in metastatic PCa could not be proved.
- 51% of cases showed PNI which was detected by S100 immunohistochemistry. So our data showed there is 5% increase in detection of PNI which suggested that the detection of PNI may be enhanced by using S100 immunohistochemistry.

Acknowledgement

I express my sincere gratitude to my guide Dr.Sankar.S, Professor and Head of Department of Pathology, for his valuable guidance, motivation and help during this study and throughout my course. I also thank Kerala University of Health Science for giving me the opportunity to do this thesis.

References

1. Holger Moch, Peter A Humprey, Thomas M Ulbright, Victor E Reuter WHO Classification of Tumors of the Urinary System and Male Genital Organs 4TH edition Lyon 2016 :138-140.
2. Steven R Potter, MD, Alan W Partin, MD, PhD The significance of Perineural invasion found on needle biopsy of the prostate: Implications for definitive therapy Reviews in Urology 2000 Spring;2(2):87-90.
3. Sara O.Vargas MD, Michael Jiroutek MS, et.al Perineural Invasion in Prostate Needle Biopsy Specimens American Journal of Clinical Pathology 1999;111:223-228.
4. Catherine Liebeg MD, Gustavo Ayala MD, Jonathan a Wilks MD, David H Berger MD and Daniel Albo MD PhD Perineural Invasion in Cancer American Cancer Society 2009:3379-3391.
5. Abhishek Kumar, Nisha J Marla, Hilda Fernandes, Praseena Kallingal Usefulness and significance of morphological criteria with regard to Gleason grade in the diagnosis of adenocarcinoma prostate Muller Journal of Medical Sciences and Research 2015 (6) :147-153.
6. Leah Lawrence Perineural Invasion Linked with prostate cancer bone metastasis Cancer network home of the ONCOLOGY journal 2015.
7. Juan Rosai, Rosai And Ackerman's Surgical Pathology 10th edition Missouri 2011 :1295-1310.
8. Alexandre de la Taille, Aaron Katz, Emilia Bagiella, Carl A Olsson, Kathleen M O Toole, Mark A Rubin Perineural invasion on prostate needle biopsy:an independent predictor of final pathologic stage Urology December 1999(54) : 1039-1043.
9. Kevin A Kurtz,;Henry T Hoffman,; M Bridget Zimmerman; Robert A Robinson, Perineural and Vascular Invasion in Oral cavity Squamous Carcinoma Arch Pathol Lab Med, March 2005(129):354-359.
10. Garg M, Kaur G, Malhotra V, Garg R. Histopathological spectrum of 364 prostatic specimens including immunohistochemistry with special reference to grey zone lesions. Prostate International. 2013;1(4):146-151
11. Barakzai MA, Mubarak M, Kazi JI. Histopathological lesions in transrectal ultrasound guided biopsies of prostate in patients with raised serum prostate specific antigen: a preliminary report. Nephro-Urol Mon. 2011;3:186-90.
12. Baig F, Hamid A, Mirza T, Syed S. Ductal and Acinar Adenocarcinoma of Prostate: Morphological and Immunohistochemical Characterization. Oman Medical Journal. 2015;30(3):162-166.
13. Lojanapiwat B, Anutrakulchai W, Chongruksut W, Udomphot C. Correlation and diagnostic performance of the prostate-specific antigen level with the diagnosis, aggressiveness, and bone metastasis of prostate cancer in clinical

- practice. Prostate International. 2014;2(3):133-139.
14. Hosein I, Sukhraj R, Goetz L, Rambarran N, Persaud S. A Clinicopathological Profile of Prostate Cancer in Trinidad and Tobago. *Advances in Urology*. 2016;2016:1-5.
 15. Coard KC, Freeman VL. Gleason grading of prostate cancer: level of concordance between pathologists at the University Hospital of the West Indies. *Am J ClinPathol* 2004;122:373-6.
 16. Bastacky SI, Walsh PC, Epstein JI. Relationship between perineuraltumor invasion on needle biopsy and radical prostatectomy capsular penetration in clinical stage B adenocarcinoma of the prostate. *Am J SurgPathol*. 1993;17:336-41.
 17. Zhao* J, Chen J, Zhang M, Tang X, Sun G, Shen P et al. The clinical significance of perineural invasion in patients with metastatic prostate cancer. *Journal of Urology*. 2019;201.
 18. Zhou M, Patel A, Rubin M. Prevalence and Location of Peripheral Nerve Found on Prostate Needle Biopsy. *American Journal of Clinical Pathology*. 2001;115(1):39-43.
 19. Aufranc S, Rosen S, Li T, et al. Unrecognized perineural invasion in prostate needle biopsies is revealed by staining for S-100 protein. *Mod Pathol*. 2000;13:92A.