



Ultrasonographic Evaluation of Thyroid Nodules Using ACR-TIRADS

Authors

Deba Kumar Chakrabartty¹, Md Imdadul Islam²

^{1,2}Department of radiology, Silchar Medical College, India

Abstract

Background: *This was a prospective study to evaluate thyroid nodules and differentiate benign from malignant nodules using ACR-TIRADS classification.*

Materials and Methods: *In our prospective study of 30 patients with thyroid nodules were evaluated using ACR-TIRADS categories. The risk of malignancy for each category were calculated and correlated with FNAC/Histopathology.*

Results: *We have studied 30 patients with thyroid nodules, Out of 30 lesions, 22 were found to be benign and 8 lesions were malignant. The risk of malignancy for ACR-TIRADS1, TIRADS2 and TIRADS 3 were 0%, TIRADS 4 and TIRADS 5 lesions had 28.6%, and 85.7% risk of malignancy respectively. In our study papillary carcinoma was the most common malignant pathology and colloid nodule was the most common benign entity.*

Conclusions: *ACR TI-RADS is more accurate in differentiating malignant thyroid nodules from benign nodules, and more reliable in recommending thyroid nodules for FNA. By using ACR-TIRADS, unnecessary FNAC can be avoided.*

Keyword: *Thyroid nodules, ACR-TIRADS (American College of Radiology Thyroid Imaging Reporting and Data System), FNAC (fine needle aspiration cytology).*

Introduction

Thyroid nodule is a commonly encountered lesion, discovered by palpation in 4%-8% of the adult population¹. Ultrasound (US) is accurate in the detection of thyroid nodules and differentiating solid from cystic nodules, but it has a relatively low diagnostic performance for the differentiation between benign and malignant nodules.^{2,3,4}

The ultrasound-based thyroid imaging reporting and data systems (TIRADS) classifications have been developed to stratify the risk for malignancy by conventional ultrasound features⁵. The

American College of Radiology TI-RADS (ACR TI-RADS) is a classification system predicting the probability of malignancy in TNs using a scoring system based on multiple ultrasound parameters and higher scores are given for more suspicious features. According to the American Thyroid Association guidelines, no definite US feature alone or in combination has outstanding sensitivity or specificity to identify all malignant nodules.⁶ Histopathological diagnosis remains the gold standard for diagnosing thyroid lesions. The aim of the ACR-TIRADS classification is to reduce unnecessary FNAC.

This study was performed to prospectively evaluate the efficacy of the TI-RADS classification system in differentiating benign and malignant lesions by stratifying the risk of malignancy for each TI-RADS categories.

Materials and Methods

The present study “**Ultrasonographic Evaluation of Thyroid Nodules Using ACR-TIRADS**” was conducted in the Department of Radiology, Silchar Medical College and Hospital, Silchar, Assam following institutional Ethical Committee approval. The hospital is situated in Cachar district of Barak Valley in the state of Assam, India. It is the tertiary and referral centre for the patients of different districts of Barak Valley of Assam and nearby north-eastern states.

Study Design: It was a prospective study.

Period of Study: The present study was conducted from July 2019 to June 2020 for a period of one year after taking approval from the Ethical Committee.

Source of data: The main source of data for this study were patients referred to the Department of Radiology from the Department of Surgery, Department of Otorhinolaryngology, Department of Medicine, and other Departments with thyroid swelling. The patients included in the study were interviewed to elicit the clinical history and to do a physical examination, the findings were recorded in a proforma. Informed consent was obtained from the subjects before commencing the investigation.

Sample Size: 30 patients.

Inclusion Criteria

- Physical examination suggestive of palpable thyroid nodule.
- Patients who were referred for thyroid ultrasonography and detected thyroid nodule.

Exclusion Criteria

- Neck swelling other than thyroid.
- Diffuse thyroid disease.
- Patients who did not give consent.

Methods

In all cases, thorough history taking and physical examination were done based on the proforma attached. Informed consent was obtained from the subjects before the commencement of the investigations. The patients were then subjected to Ultrasonographic examinations as a part of imaging evaluation. Follow up of the patients was done by taking details of investigations, FNAC/histopathological results and treatment done on the patients.

USG Evaluation

The ultrasound scans were performed using SAMSUNG RS80A ultrasonography machine with a L3-12A linear array transducer.

Technique

The procedure was explained to the patient and consent was taken. Thyroid ultrasound performed with patients in supine position with neck slightly extended. On USG nodules were evaluated for characteristics like composition, shape, echogenicity, margins, and echogenic foci as those used in the ACR lexicon⁷ and Points were assigned for each nodule to separate categories according to ACR-TI-RADS guidelines.

Table 1: ACR TIRADS categories and scores

CATEGORY	POINTS	SUSPICION
TR1	0	Benign
TR2	2	Not suspicious
TR3	3	Mildly suspicious
TR4	4-6	Moderately suspicious
TR5	7 or more	Highly suspicious

Collected data was entered into a Microsoft Excel data sheet and were analysed using the SPSS software. The p values were measured using Fischer exact test and $p < 0.05$ was taken to indicate statistical significance.

Results

In our study 30 patients were studied, 22 patients had benign pathology and 8 patients had malignant disease. The age range of patients presenting with thyroid nodules were from 17 years to 70 years. In our study the mean age of the population was 49.2 years. Those in the malignant groups having mean age of 47.2 years and those in the benign groups having mean age of 49.9 years.

Nodules were predominantly found in females (4:1), for benign and malignant lesions sex ratio (F: M) were 4.5:1 and 3:1 respectively. Most of the nodules in our study were located in the right lobe (60%). Benign lesions accounted for 73.3% of patients and malignant lesions for 26.7%.

The most common benign pathology in our study was colloid nodule. The descending order of occurrence of benign lesions were colloid nodule (77.3%), Adenomatoid nodule (18.1%) and follicular adenoma (4.6%). Amongst the malignancy, papillary carcinoma was the most common malignancy detected in our study. The descending order of occurrence of malignant lesions were papillary carcinoma (50%), follicular carcinoma (25%), medullary carcinoma (12.5%) and anaplastic carcinoma (12.5%).

Table2: Age distribution

Age	Benign	Malignant	Total no of cases	Percentage of age distribution
<30	1	1	2	6.7
30-40	2	2	4	13.3
41-50	10	1	11	36.7
>50	9	4	13	43.3
TOTAL	22	8	30	100

Figure 1: Pie chart representation of age distribution

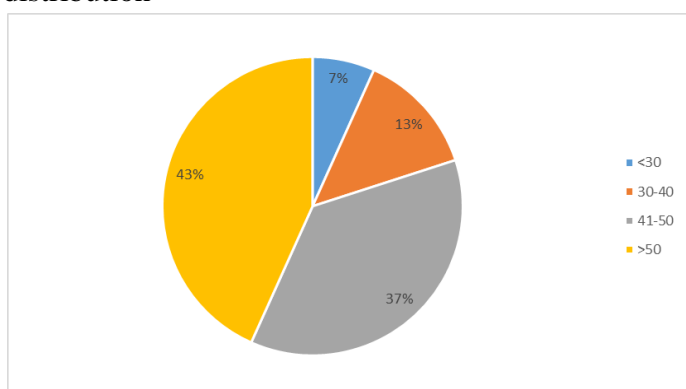


Table 3: Gender distribution of benign and malignant lesions

Sex	Benign	Percent of benign lesions	Malignant	Percent of malignant lesions
Male	4	66.7	2	33.3
Female	18	75	6	25

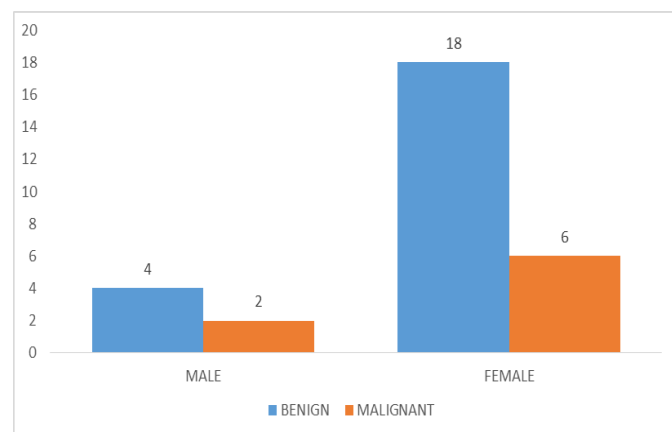


Figure 2: Gender distribution of benign and malignant lesions

On ultrasound, features such composition, echogenicity, shape, margin and echogenic foci were taken into account and they were classified according to ACR TI-RADS scoring system. TIRADS 1 includes benign Sonographic features, TIRADS 2 includes features that were not suspicious. TIRADS 3, TIRADS 4 and TIRADS 5 lesions were mildly suspicious, moderately suspicious, and highly suspicious for malignancy respectively.

Table 4: Risk of malignancy in individual features categories

Ultrasound features		benign	malignant	total	Risk of malignancy (%)
composition	solid	15	8	23	34.7
	cystic	1	0	1	0
	mixed	4	0	4	0
	spongiform	2	0	2	0
echogenicity	anechoic	1	0	1	0
	hypoechoic	4	6	10	60
	Markedly hypoechoic	0	1	1	100
	isoechoic	13	1	14	7.14
shape	hyperechoic	4	0	4	0
	Taller than wide	1	2	3	66.7
margin	Wider than tall	21	6	27	22.2
	smooth	18	4	22	18.2
Echogenic foci	ill-defined	3	0	3	0
	Lobulated/irregular	1	2	3	66.7
	Extrathyroid extension	0	2	2	100
	None	15	2	17	11.8
Echogenic foci	Comet tail	3	0	3	0
	Macrocalcification	2	1	3	33.3
	Rim calcification	1	1	2	50
	Punctate echogenic foci	1	4	5	80

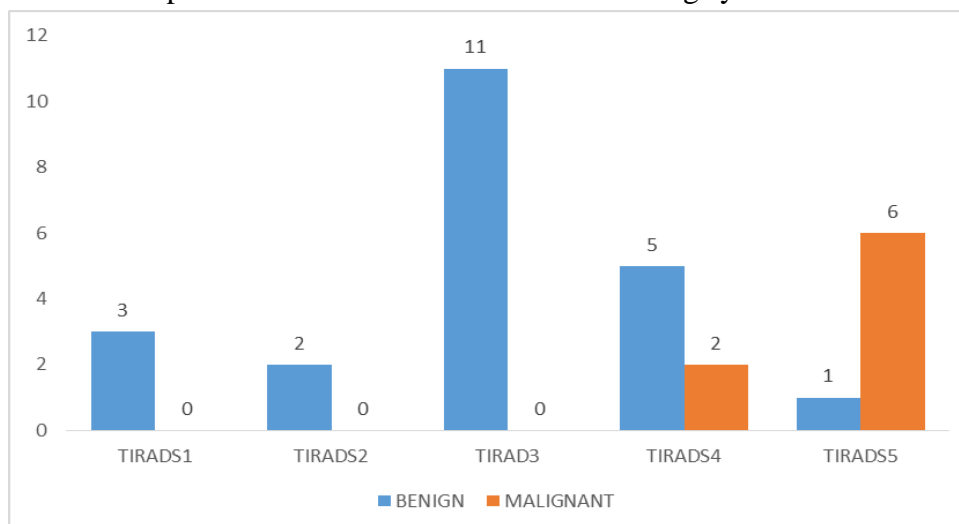
Table5: TIRADS scoring in correlation with cytology

ACR TIRADS	Benign	Malignant	Frequency	Percentage
1	3	0	3	10
2	2	0	2	6.7
3	11	0	11	36.7
4	5	2	7	23.3
5	1	6	7	23.3
TOTAL	22	8	30	100

Table 6: TIRADS categories and risk of malignancy

ACR-TIRADS	Risk of malignancy (%)
TR1,TR2,TR3	0
TR4	28.6
TR5	85.7

Figure 3: Distribution of FNAC proven lesions based on TIRADS scoring system



Discussion

In our study the mean age of the population was 49.2 years. Those in the malignant group having

mean age of 47.2 years and those in the benign groups having mean age of 49.9 years.

Study	Mean age of population	Mean age of benign lesions	Mean age of malignant lesions
Allen S Jabar et al(2019) ⁸	-	46.6	47.3
JayashreeMohanty et al(2019) ⁹	-	46	44.5
WD Middleton et al(2017) ¹⁶	54.4	-	-
Jenny K Hoang et al(2018) ¹⁷	52	54	46
Jing-liangRuan et al(2019) ¹⁰	-	47.7	40.7
Yi Zheng et al(2018) ¹¹	45.3	52	44
Present study	49.2	49.9	47.2

Most of the lesions (80%) were noted amongst the female population with a male to female ratio of 1:4.

Study	Male: Female ratio
Allen S Jabar et al(2019) ⁸	1 : 6.4
Jayashree Mohanty et al(2019) ⁹	1:4
WD Middleton et al (2017) ¹⁶	1:3.9
Wei-Bing Zhang et al (2020) ¹²	1:3.4
Present study	1:4

In our study solid nodules were the most common composition comprising of 76.7% of all nodules, next common composition was mixed solid-cystic 13.3%, spongiform 6.7%, and cystic 3.3% respectively.

All the malignant nodules were solid. Solid nodules had 34.7% risk of malignancy. All other nodules were benign and had 0% risk of malignancy.

Study	Risk of malignancy (%)			
	solid	Solid cystic	spongiform	cystic
Allen S Jabar et al(2019) ⁸	29.8	0	0	0
JayashreeMohanty et al(2019) ⁹	36	0	0	0
Luying Gao et al(2018) ¹⁴	25.9	14	-	-
WD Middleton et al(2017) ¹⁶	16.7	4	0.3	0
Jing-liangRuan et al (2019) ¹⁰	52	3.5	-	0
Yi Zheng et al (2018) ¹¹	41.5	2.8	-	-
Present study	34.7	0	0	0

On the basis of echogenicity, isoechoic nodules (46.7%) were the most common in our study, followed by hypoechoic nodules (33.3%) and hyperechoic nodules (13.4%). Anechoic and very hypoechoic nodules were 3.3% each.

Risk of malignancy was highest with very hypoechoic nodules (100%), followed by hypoechoic nodules (60%) and isoechoic nodules (7.14%). Anechoic and hyperechoic nodules carry 0% risk of malignancy.

Study	Risk of malignancy (%)				
	Hyper-echoic	Iso-echoic	hypoechoic	very hypoechoic	anechoic
JayashreeMohanty et al(2019) ⁹	4	11	47	100	0
WD Middleton et al(2017) ¹⁶	6.8	8.7	11.8	47	-
Allen S Jabar et al(2019) ⁸	6.3	6.3	66.6	100	0
Luying Gao et al(2018) ¹⁴	12.5	19.4	-	-	-
Jing-liangRuan et al (2019) ¹⁰	12.5	-	74.3	79.7	0
Yi Zheng et al (2018) ¹¹	2.78	-	34.62	50.85	-
Present study	0	7.14	60	100	0

Most of the nodules in our study were wider than taller (90%). Only 10% nodules were taller than wide. Taller than wide nodules had 66.7% risk of

malignancy and wider than taller nodules had 22.2% risk of malignancy.

Study	Risk of malignancy (%)	
	Wider than tall	Taller than wide
JayashreeMohanty et al(2019) ⁹	21.2	66.6
Allen S Jabar et al(2019) ⁸	16.9	60
Yi Zheng et al (2018) ¹¹	19.2	52.2
Luying Gao et al(2018) ¹⁴	17.6	50
Jing-liangRuan et al (2019) ¹⁰	30.6	84.7
Present study	22.2	66.7

On the basis of margins of the nodules, most of the nodules had smooth margin (73.3%), followed by ill-defined margin and lobulated/irregular margin (10%) each. Extrathyroidal extension

noted in 6.7% of cases. Highest risk (100%) of malignancy noted with extrathyroidal extension, followed by lobulated/irregular margin 66.7% and smooth margin 18.2%.

Study	Risk of malignancy (%)			
	smooth	Ill-defined	Lobulated/irregular	ETE
Allen S Jabar et al(2019) ⁸	6.8	20	42.8	0
Jayashree Mohanty et al(2019) ⁹	8.7	0	38.4	100
WD Middleton et al(2017) ¹⁶	2.9	-	44.7	-
Yi Zheng et al (2018) ¹¹	68	12	66.9	41.8
Jing-liang Ruan et al (2019) ¹⁰	3.6	-	90.4	-
Luying Gao et al(2018) ¹⁴	2.9	-	14.3	-
Present study	8.2	0	66.7	100

ETE: Extrathyroidal Extension

On the basis of echogenic foci, 56.7% of the nodules in our study had no echogenic foci, 16.7% had punctate echogenic foci, macrocalcification

and large comet tail artefact noted in 10% of cases each. Rim calcification noted in 6.6% cases.

Punctate echogenic foci had (80%), rim calcification (50%), and macrocalcification had

(33.3%) risk of malignancy. No echogenic foci associated with 11.8% risk of malignancy.

Study	Risk of malignancy (%)			
	Punctate echogenic foci	Rim calcification	Macro calcification	No echogenic foci
Jayashree Mohanty et al(2019) ⁹	50	50	42.8	13
Allen S Jabar et al(2019) ⁸	66.6	21.4	22.2	13.1
WD Middleton et al(2017) ¹⁶	35	20.2	11.8	9.7
Yi Zheng et al (2018) ¹¹	87.1	57.6	75	16.5
Jing-liang Ruan et al (2019) ¹⁰	90.6	46.7	26.1	18.4
Luying Gao et al(2018) ¹⁴	22.4	-	0	11.8
Present study	80	50	33.3	11.8

Out of the 30 patients with thyroid nodule, 3 lesions (10%) were categorized as TIRADS 1, 2 lesions (6.7%) were categorized as TIRADS 2 and 11 lesions (36.7%) were categorized as TIRADS 3; all of them turned out to be benign on FNAC, so the correlation is 100% for benign lesions based on TIRADS grading.

7 lesions (23.3 %) were categorized as TIRADS 4, of which 5 lesions (71.4%) were benign and the remaining 2 lesions (28.6%) were malignant. The benign lesions were, 4 colloid nodules and one lesion was follicular adenoma. The two malignant lesions were follicular carcinoma.

Another 7 lesions (23.3%) were categorized as TIRADS 5, out of which six lesions (85.7%) were malignant and one lesion (14.3%) turned out to be benign on FNAC, which was colloid nodule.

Thus based on the ACR-TIRADS scoring system none of the nodules with TIRADS1, TIRADS2 and TIRADS3 were malignant on histopathology, whereas TIRADS 4 lesions had 28.6 % risk of malignancy and TIRADS 5 lesions had 85.7% risk of malignancy. P value of ACR-TIRADS categories for risk of malignancy was 0.001.

Study	Risk of malignancy (%)				
	TR1	TR2	TR3	TR4	TR5
Allen S Jabar et al(2019) ⁸	0	0	6.9	29.2	80
JayashreeMohanty et al(2019) ⁹	0	0	0	40	56
Jing-liangRuan et al (2019) ¹⁰	0	2.1	3.1	40.4	90.6
Yi Zheng et al (2018) ¹¹	-	0	1.2	13	67.1
Luying Gao et al (2018) ¹⁴	-	0	0	18.4	26.7
Bernice L. Huang et al(2018) ¹⁵	0	0	0	16	47
Wei-Bing Zhang et al (2020) ¹²	0	2.4	2.7	34.4	90.1
Mohammad A Basha et al (2019) ¹³	-	0	1.2	58.3	73.6
Present study	0	0	0	28.6	85.7

Conclusions

ACR TI-RADS is more accurate in differentiating malignant thyroid nodules from benign nodules, and more reliable in recommending thyroid nodules for FNAC. By using ACR-TIRADS, unnecessary FNAC can be avoided.

References

1. Ezzat S, Sarti DA, Cain DR, Braunstein GD. Thyroid incidentalomas: prevalence

by palpation and ultrasonography. Archives of internal medicine. 1994 Aug 22;154(16):1838-40.

2. Iannuccilli JD, Cronan JJ, Monchik JM. Risk for malignancy of thyroid nodules as assessed by sonographic criteria: the need for biopsy. Journal of Ultrasound in Medicine. 2004 Nov;23(11):1455-64.
3. Hoang JK, Lee WK, Lee M, Johnson D, Farrell S. US Features of thyroid

- malignancy: pearls and pitfalls. *Radiographics*. 2007 May;27(3):847-60.
4. Moon HG, Jung EJ, Park ST, Ha WS, Choi SK, Hong SC, Lee YJ, Joo YT, Jeong CY, Choi DS, Ryoo JW. Role of ultrasonography in predicting malignancy in patients with thyroid nodules. *World journal of surgery*. 2007 Jul 1;31(7):1410-6.
 5. Russ G, Royer B, Bigorgne C, Rouxel A, Bienvenu-Perrard M, Leenhardt L. Prospective evaluation of thyroid imaging reporting and data system on 4550 nodules with and without elastography. *Eur J Endocrinol*. 2013 May 1;168(5):649-55.
 6. Cooper DS. American Thyroid Association (ATA) guidelines taskforce on thyroid nodules and differentiated thyroid cancer. Revised American Thyroid Association management guidelines for patients with thyroid nodules and differentiated thyroid cancer. *Thyroid*. 2009;19:1167-214.
 7. Tessler FN, Middleton WD, Grant EG, Hoang JK, Berland LL, Teefey SA, Cronan JJ, Beland MD, Desser TS, Frates MC, Hammers LW. ACR thyroid imaging, reporting and data system (TI-RADS): white paper of the ACR TI-RADS committee. *Journal of the American college of radiology*. 2017 May 1;14(5):587-95.
 8. Jabar AS, Koteshwara P, Andrade J. Diagnostic reliability of the Thyroid Imaging Reporting and Data System (TI-RADS) in routine practice. *Polish journal of radiology*. 2019;84:e274.
 9. Mohanty J. Role of ACR-TIRADS in risk stratification of thyroid nodules. *International Journal of Research in Medical Sciences*. 2019 Apr;7(4):1039.
 10. Ruan JL, Yang HY, Liu RB, Liang M, Han P, Xu XL, Luo BM. Fine needle aspiration biopsy indications for thyroid nodules: compare a point-based risk stratification system with a pattern-based risk stratification system. *European Radiology*. 2019 Sep 1;29(9):4871-8.
 11. Zheng Y, Xu S, Kang H, Zhan W. A single-center retrospective validation study of the American College of Radiology Thyroid Imaging Reporting and Data System. *Ultrasound quarterly*. 2018 Jun 1;34(2):77-83.
 12. Zhang WB, Xu HX, Zhang YF, Guo LH, Xu SH, Zhao CK, Liu BJ. Comparisons of ACR TI-RADS, ATA guidelines, Kwak TI-RADS, and KTA/KSThR guidelines in malignancy risk stratification of thyroid nodules. *Clinical Hemorheology and Microcirculation*. 2020 Jan 4(Preprint):1-4.
 13. Basha MA, Alnaggar AA, Refaat R, El-Maghraby AM, Refaat MM, AbdElhamed ME, Abdalla AA, Aly SA, Hanafy AS, Afifi AH, Harb O. The validity and reproducibility of the thyroid imaging reporting and data system (TI-RADS) in categorization of thyroid nodules: Multicentre prospective study. *European journal of radiology*. 2019 Aug 1;117:184-92.
 14. Gao L, Xi X, Wang J, Yang X, Wang Y, Zhu S, Lai X, Zhang X, Zhao R, Zhang B. Ultrasound risk evaluation of thyroid nodules that are "unspecified" in the 2015 American Thyroid Association management guidelines: A retrospective study. *Medicine*. 2018 Dec;97(52).
 15. Huang BL, Ebner SA, Makkar JS, Bentley-Hibbert S, McConnell RJ, Lee JA, Hecht EM, Kuo JH. A Multidisciplinary Head-to-Head Comparison of American College of Radiology Thyroid Imaging and Reporting Data System and American Thyroid Association Ultrasound Risk Stratification Systems. *The oncologist*. 2020 May;25(5):398.
 16. Middleton WD, Teefey SA, Reading CC, Langer JE, Beland MD, Szabunio MM,

Desser TS. Multiinstitutional analysis of thyroid nodule risk stratification using the American College of Radiology Thyroid Imaging Reporting and Data System. American Journal of Roentgenology. 2017 Jun;208(6):1331-41.

17. Hoang JK, Middleton WD, Farjat AE, Langer JE, Reading CC, Teefey SA, Abinanti N, Boschini FJ, Bronner AJ, Dahiya N, Hertzberg BS. Reduction in thyroid nodule biopsies and improved accuracy with American College of Radiology Thyroid Imaging Reporting and Data System. Radiology. 2018 Apr;287(1):185-93.