



Role of HRCT in Association between Age and PAH in COVID-19 Patients

Authors

Akshay B¹, P Venkata Srujana², Padala Karthik³

¹Associate Professor, Department of Radiodiagnosis, Konaseema Institute of Medical Sciences, Amalapuram, Andhra Pradesh, India

^{2,3}Junior Resident, Department of Radiodiagnosis, Konaseema Institute of Medical Sciences, Amalapuram, Andhra Pradesh, India

Introduction

In December 2019, novel corona virus (COVID-19), aka severe acute respiratory syndrome corona virus-2 (SARS-COV-2) infection has out break as an global pandemic with high number of reporting cases worldwide.

It is manifested by respiratory symptoms due to lung involvement.

The imaging features of COVID-19 pneumonia were well described as multifocal peripheral ground glass opacities with or without consolidation⁽¹⁾⁽²⁾.

However these are not specific and can be seen in other diseases like viral pneumonia, eosinophilic pneumonia or cryptogenic organizing pneumonia. There has been some literature evidences regarding microvascular damage of pulmonary arteries, cytokine release syndrome (CRS) and hypercoagulability due to proinflammatory state which leads to thromboembolic events, multiorgan complications.

Aims and Objectives

To determine the incidence of pulmonary artery hypertension in patients with COVID-19 infection

in old age was greater than in young age at our institution with the help of HRCT as modality

Material and Methods

This present study was done in Department of Radiodiagnosis, Konaseema Institute of Medical Sciences And Research Foundation, Amalapuram during the period of 21-07-2020 to 15-08-2020.

Study Design

Institution – based prospective study

Source of Data

All the patients with sign and symptoms of COVID-19 infection (fever, cough, myalgia, head ache, shortness of breath, anosmia, confusion) and tested positive with RT-PCR ,who were referred to our department for HRCT chest in radio-diagnosis konaseema institute of medical sciences and research foundation, Amalapuram during the period of 21-07-2020 to 15-08-2020.

Sample Size

A sample size of 146 patients with RT-PCR positive diagnosed as COVID-19 infection.

Selection Criteria

Inclusion Criteria

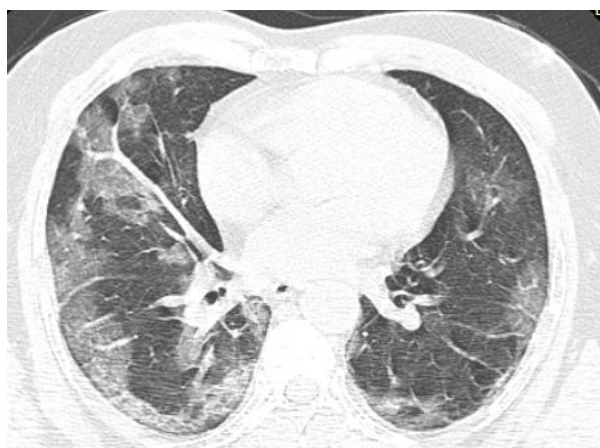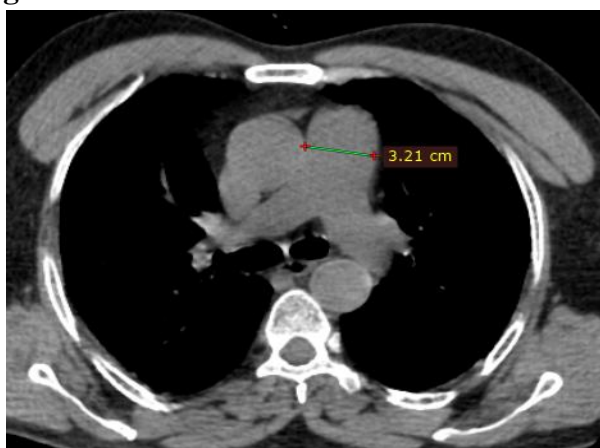
Men and women of at least 18 yrs of age COVID-19 positive cases (RT-PCR) with no previous history of pulmonary artery hypertension.

who were referred to our department of radio-diagnosis konaseema institute of medical sciences and research foundation, Amalapuram during the period of 21-07-2020 to 15-08-2020 .

Exclusion Criteria

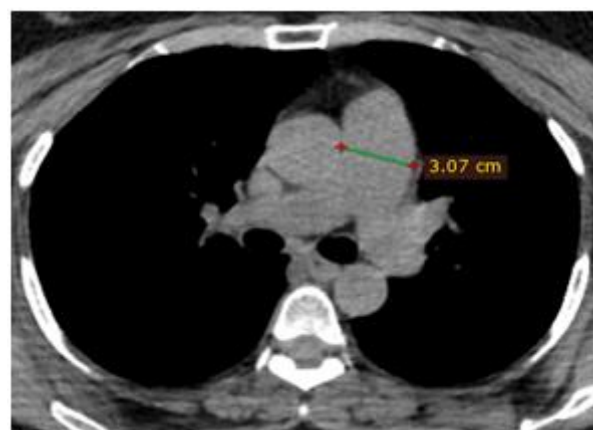
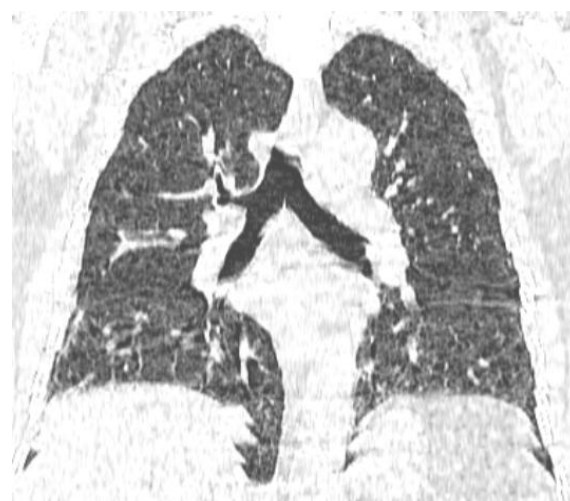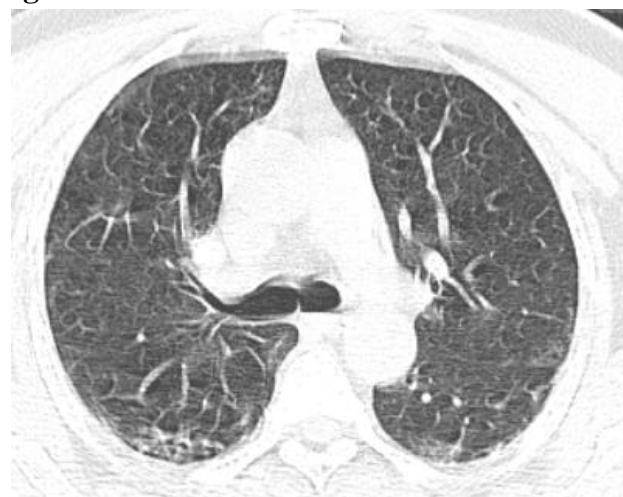
All patients with history of previous pulmonary arterial hypertension, pregnant women and children less than 18 years of age.

Figure 1



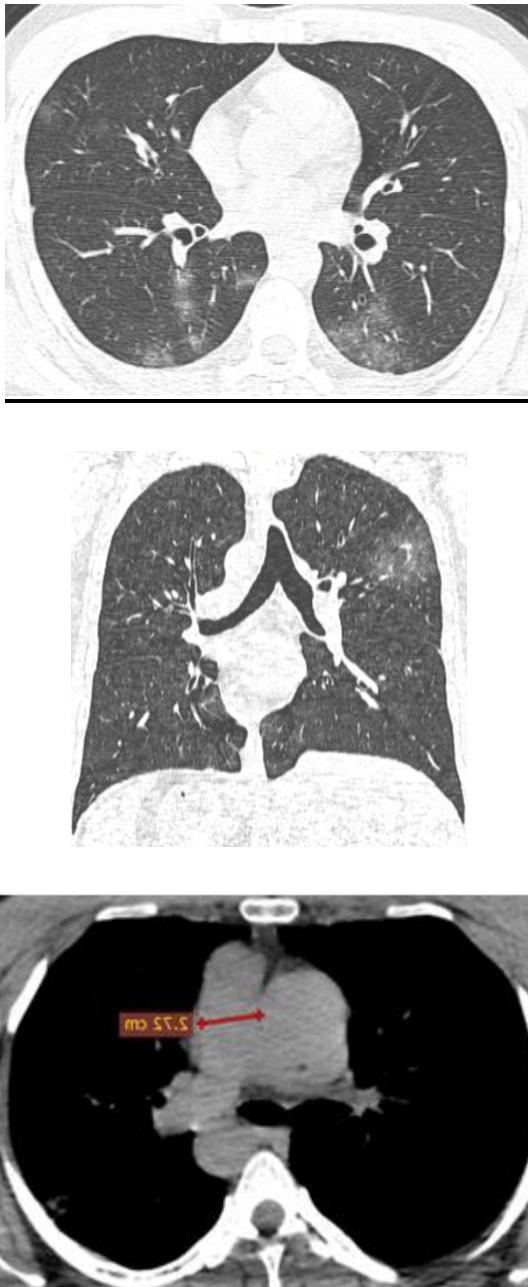
A 64 year old male HRCT chest shows - Multiple peripheral groundglass opacities with interlobular septal thickening in bilateral lung parenchyma with dilated main pulmonary artery diameter about 32mm.

Figure 2



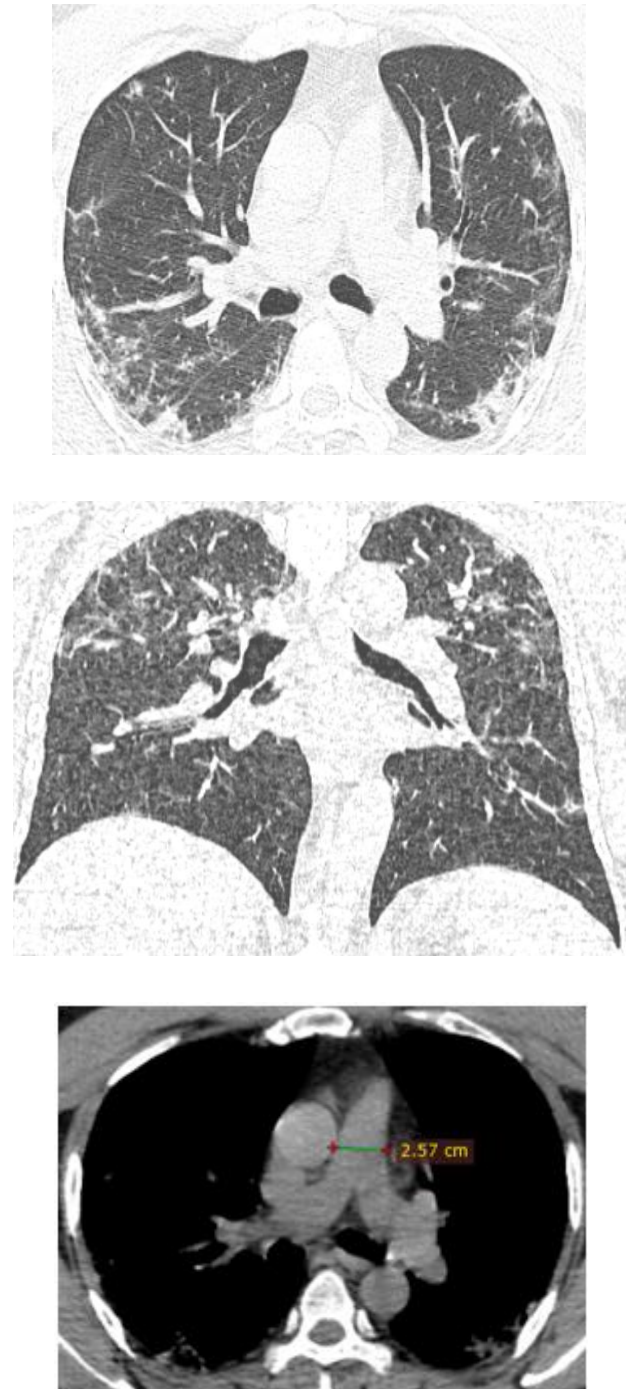
A 42 year old male HRCT chest shows - Multiple peripheral ground glass opacities with interlobular septal thickening in bilateral lung parenchyma with dilated main pulmonary artery diameter about 30.7mm

Figure 3



A 58 year old male HRCT chest shows - Multiple peripheral ground glass opacities with interlobular septal thickening in bilateral lung parenchyma with main pulmonary artery diameter about 24.2 mm

Figure 4



A 36 year old male HRCT chest shows - Multiple peripheral ground glass opacities with interlobular septal thickening in bilateral lung parenchyma with main pulmonary artery diameter about 25.7mm .

Procedure

Data Collection

Men and women with minimum age of 18 years excluding children and pregnant women with no previous history of pulmonary arterial

hypertension, who were referred to our department of radio-diagnosis, konaseema institute of medical sciences and research foundation, Amalapuram during the period of 21-07-2020 to 15-08-2020.

We grouped the patients into young aging between 18 – 49 years, and old aging between 50 to 80 years.

HRCT chest were conducted for the lung parenchymal changes and the main pulmonary artery diameter are measured to rule out pulmonary artery hypertension.

We categorised patients with ≤ 29 mm of main pulmonary artery diameter as no PAH candidates and patients with ≥ 30 mm of main pulmonary artery diameter as PAH⁽⁴⁾.

The main pulmonary artery diameter and the patients age were noted and analysed to interpret that COVID 19 viral pneumonia is a risk factor for the development of pulmonary artery hypertension and the age distribution were observed to find out its incidence in old age .

Results

we did a study on a sample size of 146 positive COVID-19 patients (confirmed by RT-PCR) without any previous history of pulmonary arterial hypertension who came for HRCT chest to our department during the period of 21/07/2020 to 15/08/2020 we found that out of the total sample size 48 (32.8 %) patients were diagnosed with pulmonary artery hypertension and we studied the age distribution of which we found that 36 (75 %) of the PAH diagnosed were old age (> 50 years) and 12 (25 %) were of young age (=49/<50 yrs) , with the *p* value as 0.0109, (statistically significant *p* <0.05) and *chi square value* – 6.48

Figure/Table 5

Age Distribution	PAH		Total
	YES	NO	
Young age (=49, <50)	12 (20.6 %)	46 (79.3 %)	58
Old age (=50, > 50)	36 (40.9 %)	52 (59.0 %)	88
	48	98	146

Figure /Table 6

Incidence of COVID 19 Associated PAH in Age Groups

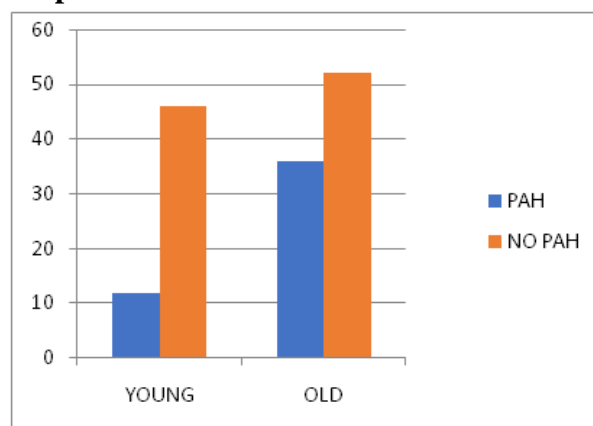
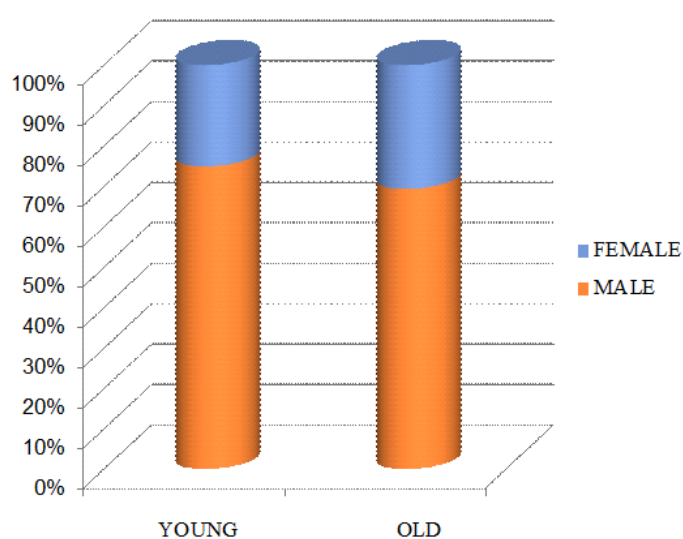


Figure /Table 7

Age Distribution	PAH		Total
	Male	Female	
YOUNG (=49, <50)	09 (75 %)	03 (25%)	12
OLD (=50, > 50)	25 (69.4 %)	11 (30.5 %)	36
	34	14	48

Figure/Table 8

Age and Sex Distribution among COVID 19 Patients with PAH



Discussion

In 2019, novel corona virus (covid-19), aka severe acute respiratory syndrome corona virus-2 (SARS-COV-2) infection has out break as an global pandemic.

It is manifested by respiratory symptoms with imaging features described as bilateral multifocal peripheral ground glass opacities with or without consolidation and regarding microvascular damage of pulmonary arteries and hypercoagulability due to proinflammatory state which leads to thromboembolic events, neurological manifestations.

We should be aware of pulmonary arterial hypertension as one of major complication associated with or may occurs as early complication of COVID-19 infection

Patients who developed pulmonary arterial hypertension usually after COVID-19 infection probably due to marked pulmonary parenchymal abnormalities in combination with microvascular damage of pulmonary arteries

The pulmonary response to consolidation is generally by hypoxic pulmonary vasoconstriction⁽⁴⁾ with reduced perfusion⁽⁵⁾ and shunting the blood towards the less affected area

The vascular enlargement was often within or outside the lung opacities and near the ground glass opacities

The dilatation of vasculature in diseased area shows a disordered vasoregulation causing V/Q mismatch.

The appearance of dilated sometimes tortuous vessels in the sub pleural lung and vascular thickening(thick vessel sign)^{(1),(2),(3)} within pulmonary opacities in COVID-19 pneumonia.

These findings are in favor of pulmonary arterial hypertension

Overall dilated pulmonary vasculature is seen in 32.8% of the cases

As in our study we have taken small group of people we need large study populations and randomized control trails to prove the significance of study.

In view of association of COVID-19 with coagulopathy, microvascular disease, subsequent, potential micro-pulmonary embolism as well as interstitial pulmonary damage pulmonary arterial hypertension is likely to be a frequent complication of severe COVID-19 pneumonia

Lang et al⁽⁵⁾, som A et al did a retrospective study on Pulmonary Vascular Manifestations of COVID-19 Pneumonia with total of 48 patients the average age was 58 ± 19 years. Overall, dilated pulmonary vasculature was seen in 41 (85%) of cases, with 38 (79%) within pulmonary opacities and 27 (56%) outside of the opacities and dilated distal pulmonary vessels extending to the pleura and fissures were seen in 40 cases (83%) and 30 cases (63%), respectively. As described, vascular enlargement was often within or outside the opacity, and extended to the pleura generally near ground-glass opacities without diffuse involvement. Mosaic attenuation, likely from mosaic perfusion, was noted in 45 cases (94%) on conventional chest CT lung window.

With the knowledge of pathogenesis of COVID - 19 patients they are at high risk of developing PAH which may further complicate to hypoxemia. As per our knowledge there are no much studies regarding the association of PAH in old age among covid patients, which makes us to study the incidence of PAH in old age with COVID infection .We have taken sample size of 146 where 48 (32.8%) patients were diagnosed with PAH among them 36 (75%) patients were ≥ 50 years.

There by showing old aged COVID-19 patients are at high risk of PAH.

As in our study we have taken small group of people we need large study populations and randomised control trails to prove the significance of study.

Conclusion

COVID-19 pneumonia appears to be associated with pulmonary arterial hypertension because of abnormal pulmonary vasoregulation, intrapulmonary shunting.

Patients with COVID-19 infection at old age had a higher rate of pulmonary artery hypertension than patients with COVID-19 infection at young age in our study.

References

1. Li Y, Xia L. Coronavirus Disease 2019 (COVID-19): Role of Chest CT in Diagnosis and Management. *AJR Am J Roentgenol* 2020;1-7. doi: 10.2214/AJR.20.22954
2. Bai HX, Hsieh B, Xiong Z, Halsey K, Choi JW, Tran TML, Pan I, Shi LB, Wang DC, Mei J, Jiang XL, Zeng QH, Egglin TK, Hu PF, Agarwal S, Xie F, Li S, Healey T, Atalay MK, Liao WH. Performance of radiologists in differentiating COVID-19 from viral pneumonia on chest CT. *Radiology* 2020:200823. doi: 10.1148/radiol.2020200823
3. Zhao W, Zhong Z, Xie X, Yu Q, Liu J. Relation Between Chest CT Findings and Clinical Conditions of Coronavirus Disease (COVID-19) Pneumonia: A Multicenter Study. *AJR Am J Roentgenol* 2020:1-
4. Grosse C, Grosse A. CT findings in diseases associated with pulmonary hypertension: a current review. *Radiographics* 2010;30(7):1753-1777. doi: 10.1148/rg.307105710.
5. Lang M, Som A, Carey D, Reid N, Mendoza DP, Flores EJ, Li MD, Shepard JA, Little BP. Pulmonary vascular manifestations of COVID-19 pneumonia. *Radiology: Cardiothoracic Imaging*. 2020 Jun 18;2(3):e200277.