



## Anaesthesia Approach for Clival Chordoma with Craniovertebral Instability and Brainstem Compression

Authors

**Dr Pratima Kothare, Dr Dipti Madan\***

Bombay Hospital Institute of Medical Sciences, 12 New Marine Lines, Mumbai- 400020

\*Corresponding Author

**Dr Dipti Madan**

### Abstract

*Craniovertebral junction lesions affect the skeleton and the enclosed neuraxis at the junction of the cranium and cervical spine. Up to 25% Chordomas occur at the base of the skull, arising from the clivus. Such lesions are rare, have a difficult anatomical access, are locally invasive and destructive in nature, and are situated in close proximity to the brainstem, thus posing a challenge for both neurosurgeons and anaesthetists.*

*Hence, it becomes important to formulate an anaesthesia plan, with special regards to intubation and extubation, causing minimal disturbance to the cervicovertebral junction, being prepared for effects of the tumour depending on the location of the tumour, delayed recovery of respiratory function and prolonged ventilation in the postoperative period.*

**Case in Brief:** *A 28 years old female, presenting with bilateral upper and lower limb tingling, 2 years after being operated for a clival chordoma. She also had complaints of imbalance while walking for 1 year.*

*The surgical management was divided in 2 stages; first a posterior occipitocervical fusion was done and then the chordoma was excised via an endoscopic endonasal transsphenoidal approach.*

*This patient developed cerebrospinal fluid leakage in the immediate postoperative period, which was managed by an endoscopic endonasal surgical repair.*

**Keywords:** *recurrent clival chordoma, cervical body erosion, brain stem compression, occipitocervical fixation, endoscopic endonasal skull base surgery.*

### Background

The Craniovertebral junction (CVJ) is formed by the occipital condyles, the atlas (C1) and axis (C2) vertebrae, and their respective articulations. Any lesions occurring at this anatomical location, thus, affect the skeleton and the enclosed neuraxis, at the junction of the cranium and the cervical spine.

Tumours at this location are a rare occurrence, with an incidence rate of 0.1 per 1000000 per year.<sup>1</sup> Such tumours are a challenge to diagnose;

in addition, their surgical resection and anaesthesia plan pose a challenge, too.

Intracranial chordomas are centrally located, arising from vestigial notochordal cells. These tumours are extradural, arising commonly from the clivus and other midline structures of the skull base. They have a male:female ratio of 2:1, are slow growing and low-grade malignancies that are invasive and locally destructive. They are difficult to remove completely without causing

neurological deficits and commonly recur, with a high risk of eventual mortality.<sup>2</sup>

The most common surgical approach for chordoma resection is transsphenoidal, via endoscopic endonasal approach.<sup>3</sup> More extensive tumours require transbasal or transpetrosal approaches. The location of clival chordomas frequently leads to airway obstruction and subsequent restrictive lung disease, making such patients high-risk for general anaesthesia.

The presenting symptom can be respiratory dysfunction caused by brainstem compression from the odontoid process of the axis vertebra pressing on the respiratory centres, and weakening of the muscles of respiration, including the diaphragm.<sup>4</sup> dissection in close vicinity to the brainstem carries a significant risk to respiration, mobility of all the limbs, bowel and bladder continence and life.

The surgical excision of a clival chordoma leads to atlantooccipital instability if more than 50% of either occipital condyle is respected. Thus, atlantooccipital fusion is usually required for craniovertebral stability. It is a neurosurgical decision on whether the atlantooccipital fusion should be done before or after chordoma excision, on a case-by-case basis.

### Case Report

A 28 years old female, who had been previously operated for a clival chordoma, presented with bilateral upper and lower limb tingling for 2 years, imbalance while walking for 1 year, and on-and-off headaches for 1 year. She did not give a history of visual symptoms like diplopia or ocular deviation, or dyspnoea. She had no known comorbidities.

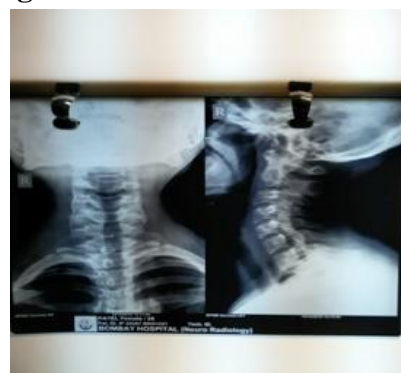A valid written consent was taken during the preoperative visit, when the patient was counselled for anaesthesia and surgery.

On examination: ASA grade 1 with adequate mouth opening, Mallampatti grade 1, normal gag reflex, normal vision and ataxic gait. Neck movements were not tested due to suspected craniovertebral instability.

**Investigations:** Routine blood investigations were within normal limits. Serum Cortisol levels were 0.953 microgram/decilitre (Normal range: 6.2 to 19.4 microgram/decilitre)

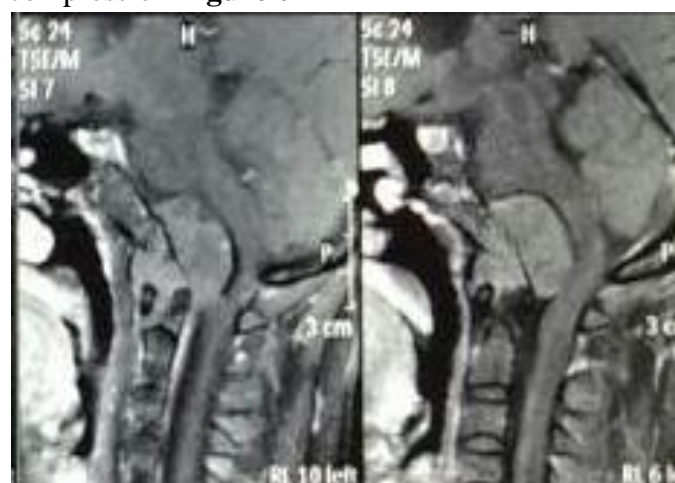Chest X-ray was normal

Cervical spine X-ray showed axis (C2) body erosion **Figure 01**



**Figure 01:** X-ray cervical spine showing axis body erosion

MRI Brain (Tumour protocol) showed a lobulated lesion involving the clivus, clival erosion, extension into the posterior fossa and brainstem compression **Figure 02**



**Figure 02:** MRI Brain showing clival chordoma with axis erosion and brainstem compression

Ophthalmic evaluation was normal.

Surgery was planned in 2 stages:

Stage1: Posterior occipitocervical fusion

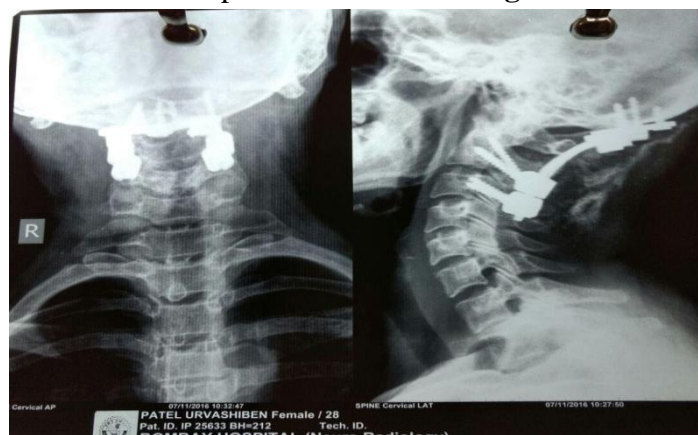Stage2: endoscopic endonasal transsphenoidal excision of chordoma.

### Anaesthesia Approach

- Standard monitoring: Electrocardiogram, oxygen saturation probe, non-invasive blood pressure, end tidal CO<sub>2</sub>, fluid intake, urine output
- Special monitoring for tumour excision: Radial arterial invasive blood pressure, right internal jugular vein cannulation, bispectral index, blood sugar, electrolytes, arterial blood gases, lumbar drain
- Intravenous fluids given as per standard protocol
- The patient was preoxygenated and premeditated with glycopyrrolate, antiemetic and antacid
- Awake fibre optic intubation was done following transtracheal injection of 4% Lignocaine and 10% Lignocaine oral spray. 7.0 flexometallic endotracheal tube used. Endotracheal tube placement confirmed by end tidal CO<sub>2</sub> tracing and auscultation. No sedation was used.
- Induction: Fentanyl (1 microgram/kg), Midazolam (0.1 milligram/kg), Propofol (2 milligram/kg), and Atracurium (0.5 milligram/kg)
- Maintenance: oxygen, air and Desflurane in a ratio that maintained mean arterial pressure of 80-90 mm Hg, heart rate of 60-70 beats per minute, end tidal carbon dioxide of 35-45 mm Hg, minimum alveolar concentration of 0.8-1.0
- Large bore peripheral line for blood induction, separate line for sedation and muscle relaxant infusions were also accessed. Fentanyl, Midazolam and atracurium were used in infusions.
- Dexmedetomidine can also be used but since it can lead to hypotension and bradycardia and the surgery required dissection near the brainstem, Dexmedetomidine was avoided.
- Labetolol infusion was used to maintain mean arterial blood pressure within the desired range.

- Extubation was done using Neostigmine (0.08 milligram/kg) and glycopyrrolate (0.004 milligram/kg) or atropine (0.01 milligram/kg). Extubation must be smooth, without sudden hypertension, or there is a risk of bleeding of cerebrospinal fluid leak.

Anaesthesia plane for Stage 1/ Day 1: Occipitocervical fusion with pedicle screw fixation and occipital screw fixation **Figure 03**

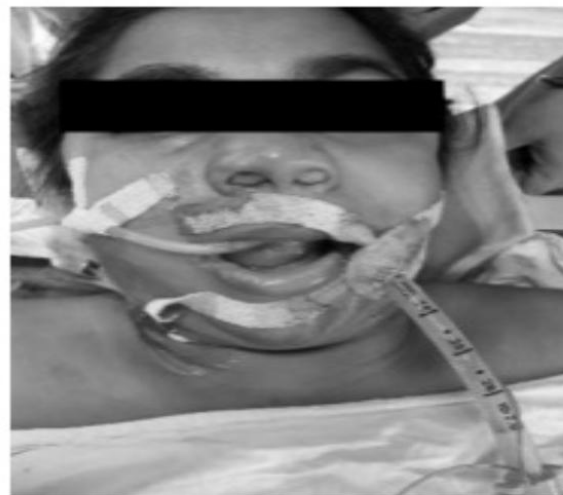
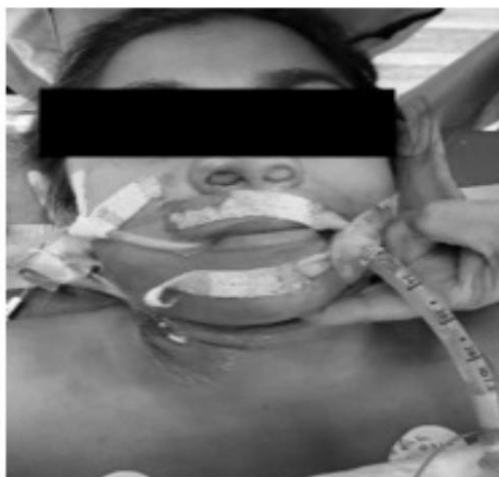
**Figure 03:** Occipitocervical fusion with pedicle screw fixation and occipital screw fixation

- On-table reassessment for mouth opening, neck movements and spine stability.
- Awake fibre optic intubation done
- Uneventful intraoperative course, no spinal cord oedema suspected
- Methylprednisolone not used
- After extubation, the patient was following commands, moving all her limbs with a good mouth opening and talking coherently postoperatively.

Anaesthesia plan for Stage 2/Day 2: Endoscopic endonasal skull base transsphenoidal approach for chordoma excision

- Preoperative assessment repeated with the patient conscious, oriented and obeying verbal commands.
- Mouth opening was found to be restricted to one finger width, neck movements were restricted due to fixation. On-table fluoroscopic examination showed the trachea to be central **Figure 04**



**Figure 04:** Short fixed neck with chin touching the chest (right) and inadequate mouth opening (left)

- Awake fibre optic intubation was done. The patient was found to have poor cough reflex on intratracheal injection. Flexometallic tube no. 6.5 was used but resistance was encountered and manipulation was required to push the cuff past the vocal cords.
- Oral gastric tube was inserted.
- Lax brain strategy was applied and 16 gauge lumbar drain was inserted to facilitate this.
- Methylprednisolone (30 milligram/kg) was given to reduce brainstem oedema expected due to dissection in its close proximity.
- The intraoperative course was uneventful, no sudden changes in blood pressure or heart rate due to brainstem handling were observed.
- There was significant blood loss requiring peaked cell transfusion.
- The patient was reversed, assessed for following verbal commands and neurological deficit, then sedated and paralysed again.

Anaesthesia plan for day 3: Tracheostomy and cerebrospinal leak repair

- The patient was on ventilator support.
- Standard anaesthesia approach was used.
- Tracheostomy was performed in view of requiring long term ventilation.

- Cerebrospinal fluid leak was detected and repaired via an endonasal end optic approach.
- Lumbar drain was continued for one more day.

This patient was gradually weaned off ventilator support and tracheostomy was decannulated on day 15 postoperatively.

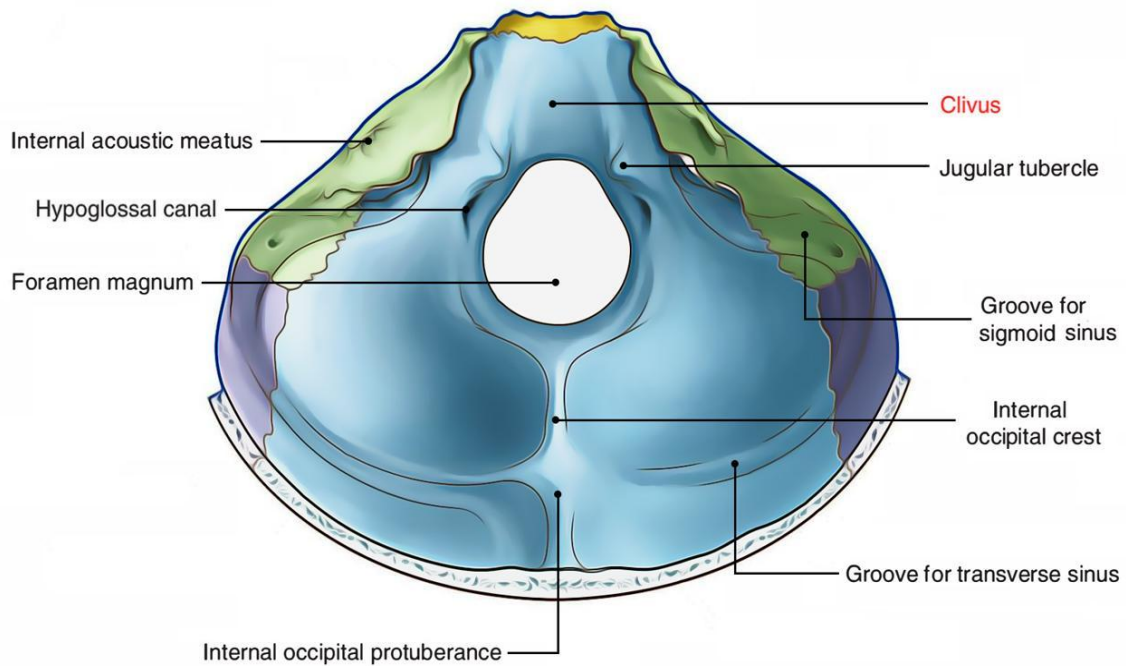
The patient was discharged 21 days postoperatively without any neurological deficits.

### Discussion

The craniovertebral junction (CVJ) is the region of the occipital bone that surrounds the foramen magnum, the atlas (C1) and axis (C2) vertebrae. So, by definition, this region includes the clivus, the foramen magnum and the upper cervical canal.<sup>5</sup>

The clivus is a sloping, bony part of the cranium at the skull base, a shallow depression posterior to the dorsum sellae that slopes obliquely backwards. It forms a gradual sloping process at the anterior most portion of the basilar occipital bone at its junction with the sphenoid bone, it is posterior to the sphenoid sinus, lateral to the foramen lacerum and the basilar artery is posterior to the clivus. The internal carotid artery passes anterior to it before forming the circle of Willis. **Figure 05**





**Figure 05:** Anatomy of the clivus

**Brief overview of chordoma**

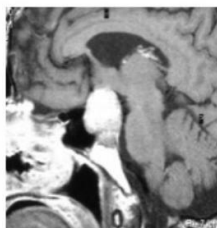
Chordomas are the most common of the extradural tumours involving the clivus at the craniovertebral junction. They can be classified as upper, middle or lower chordoma.

Grossly, chordomas are lobulated gelatinous masses surrounded by a pseudocapsule.

Histopathological features indicate that it is a remnant of the notochord.<sup>6</sup>

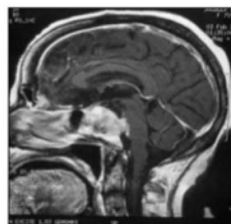
Clinical presentation of chordoma relevant to anaesthesia

The signs and symptoms depend on the location of the tumour. **Figure 06**



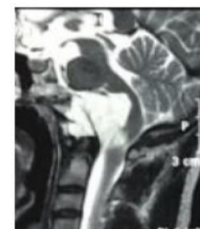**Upper Clival Chordoma:**

- Cranial nerve V: Trigeminal Neuralgia
- Cranial nerve VI palsy: Lateral gaze palsy



**Mid-Clival Chordoma:**

- Brainstem compression: Hypertension, Bradycardia
- Respiratory centre compression: Abnormal breathing pattern
- Cranial nerve VII palsy: Facial palsy



**Lower Clival Chordoma:**

- Cranial nerve IX is sensory to the palate
- Cranial nerve X and XI are motor to the palate and the pharynx

**Figure 06:** Upper, mid and lower clival chordomas

### **Chordoma commonly presents with headache, neck pain, and visual disturbances.**

- Headache is commonly occipital and occipitocervical, aggravated by changes in head position and neck movements, especially when looking up, indicating cervical instability.
- Basisphenoid chordomas have upper cranial nerve and endocrine dysfunction.
- Basiocciput chordomas have lower cranial nerve and cerebellar dysfunction.
- Lateral extension of the chordoma may cause hypoglossal nerve palsy.
- Very large chordomas may have both upper and lower cranial nerve dysfunction with brainstem compression.
- Upper clival chordomas have optic nerve dysfunction and extraocular muscle palsy. They may also have retropharyngeal compression, leading to resistance or difficulty in passing an endotracheal tube.<sup>7</sup>
- Middle and lower clival chordomas may have corticospinal dysfunction with sensory deficits.

### **Anaesthesia applications of diagnostic evaluation of clival chordoma**

- X-ray skull and cervical spine: To look for bony erosion of clivus process and destruction of sphenoid wing, dorsum sellae or clivus, indicating cervical instability, thus, requiring cautious intubation and extubation with cervical collar and to expect bleeding during drilling.
- CT scan head: Chordoma appears as solitary or multiple areas of decreased attenuation with the clivus.
- MRI brain: To assess proximity or displacement of basilar artery, brainstem compression, fourth ventricle invasion. To observe for perioperative brainstem changes and postoperative brainstem oedema and other sequelae.

### **Application of perioperative evaluation for skull base surgery**

- Signs of raised intracranial pressure: Nausea, vomiting, headache, altered sensorium, visual disturbances, papilloedema. Application of lax brain strategy is needed, like use of diuretics and lumbar drain insertion.
- Signs of brainstem dysfunction: Altered respiratory pattern, sleep apnoea. Observe for changes due to brainstem manipulation, like bradycardia and hypertension and inform the surgeon to stop immediately. Postoperative elective ventilation should be considered.
- Signs of cranial nerve dysfunction: Dysphagia, absent gag reflex. Insertion of Ryle's tube to prevent regurgitation.
- Signs of cerebellar dysfunction: Ataxia. Recovery may be slow as the muscles are weak.

### **Management of clival chordoma**

- I. Surgical
- II. Medical
- III. Phototherapy

### **Surgical management of clival chordoma**

Microsurgery with the aim of gross total resection (GTR), or subtotal resection (STR), followed by radiotherapy, is considered the standard for treatment.

Endoscopic endonasal transsphenoidal route for surgical approach is the most commonly used<sup>3</sup>, due to being easier and associated with lower bleeding risk. This approach avoids hard and soft palatal split and its related morbidity, reduces postoperative tube feeding duration, and also avoids tongue swelling due to prolonged retractor use.

Complete resection of tumour during the first surgery in expert centres provides the best chance for local control and long term survival.<sup>8,9</sup>

### Radiotherapy for clival chordoma

Intensity modulated radiotherapy and gamma knife radiosurgery reduce the risk of recurrence after surgery and prolong survival for chordoma patients.<sup>10</sup>

However, chordomas tend to recur in the same or nearby locations, even after surgery and/or radiotherapy.

### Medical management of clival chordoma

Case-specific and not the mainstay of therapy

Special concerns for anaesthesiologists during skull base and craniovertebral location procedures via endoscopic endonasal approach:<sup>11,12,13,14</sup>

- Long duration of anaesthesia due to 2 staged surgical approach
- Preoperative preparations involving coexisting comorbidities requiring optimisation and cessation of anticoagulant therapy, if the patient is using these drugs.
- Cervical spine instability due to local invasion by the tumour requires induction and positioning with minimal or no neck movements at the atlantoaxial joint by using a cervical collar and a fibre optic bronchoscope for intubation, to prevent spinal cord and brainstem damage.<sup>15</sup>
- Difficult airway must be anticipated due to cervical instability, large tumours with retropharyngeal space invasion, tracheal displacement, and fixed cervical spine due to fixation surgery<sup>16</sup>. A smaller sized endotracheal tube may be required. Awake fibre optic intubation is preferred to avoid complications, and also keeping difficult airway cart ready with supraglottic airway devices, that will allow ventilation and oxygenation, if endotracheal intubation fails.<sup>17,18</sup>
- The patient needs to be carefully positioned to prevent peripheral nerve injuries, ocular damage during prone positioning and risk of venous air embolism.

- Neurophysiological monitoring like somatosensory evoked potential (SSEP) and motor evoked potential (MEP) help prevent damage to cranial nerves.
- Controlled hypotension allows for reduction in intraoperative bleeding and improves surgical field visibility of an already narrow and limited area.
- Tumour vicinity to the basilar artery and the internal carotid artery and their injury during drilling would cause sudden and torrential blood loss and require massive blood transfusion and its sequelae.
- Posterior circulation compromise may lead to ventilator dependency.
- Craniovertebral lesions may cause respiratory problems of a multifactorial origin. There may be restrictive or obstructive lung disease, obstructive sleep apnoea (OSA), due to respiratory muscle weakness, including the diaphragm, direct compression of the respiratory centres of the medulla oblongata from bony abnormalities. Lower clival chordomas may cause lower cranial nerve damage causing poor cough or gag reflex, resulting in frequent aspiration and pulmonary infections.<sup>17</sup> Atlantoaxial instability may cause compression at the craniovertebral junction, causing acute and progressive respiratory dysfunction producing disordered breathing during sleep.<sup>10</sup>
- Prolonged postoperative ventilation may require a tracheostomy
- Early or late cerebrospinal fluid leak requiring surgical repair may occur.

### Conclusion

Choice of anaesthetic agent is a choice based on personal experience and preference, within the limits of the principles of neuroanaesthesia.

- Intubation and extubation strategy plan: Awake fibre optic intubation without sedation is recommended

- Rescue airway: Nasopharyngeal tube, laryngeal mask airway, combitube and tracheostomy tubes to be kept standby
- Occipitocervical instability precautions requiring immobility during intubation and positioning with a cervical collar is ideal
- Understanding the anatomy of the craniovertebral junction, the location of the tumour and its proximity to the brainstem, carotid artery, basilar artery and posterior communicating artery is important
- If the posterior circulation is compromised (basilar or posterior communicating artery), brain oedema, infarction, delayed recovery, no recovery with ventilator dependence may be seen
- Lower cranial nerve damage may cause swallowing problems leading to regurgitation and/or aspiration pneumonia. An orogastric tube/Ryle's tube insertion is an important step for the anaesthesiologist
- Endoscopic endonasal transsphenoidal skull base surgical approach requires lax brain and a dry surgical field by employing pharmacological methods rather than increasing the depth of anaesthesia

### Acknowledgements

Department of Neurosurgery, Bombay Hospital Institute of Medical Sciences, Mumbai

Dr. Ranjana Das, Consultant Anaesthesiologist, Bombay Hospital Institute of Medical Sciences, Mumbai

Consultant Neurosurgeons: Dr. C. E. Deopujari, Dr. Vikram Karmarkar, Dr. Chandan Mohanty

**Conflict of Interest:** Nil

**Sources of support in the form of grants:** None

### References

1. McMaster ML, Goldstein AM, Bromley CM, Ishibe N, Parry DM. Chordoma: incidence and survival patterns in the United States, 1973-1995. *Cancer Causes Control*. 2001 Jan;12(1):1-11. doi:

- 10.1023/a:1008947301735. PMID: 11227920.
2. Tzortzidis F, Elahi F, Wright D, Natarajan SK, Sekhar LN. Patient outcome at long-term follow-up after aggressive microsurgical resection of cranial base chordomas. *Neurosurgery*. 2006 Aug; 59(2):230-7; discussion 230-7. doi: 10.1227/01.NEU.0000223441.51012.9D. PMID: 16883163.
3. Fraser JF, Nyquist GG, Moore N, Anand VK, Schwartz TH. Endoscopic endonasal transclival resection of chordomas: operative technique, clinical outcome, and review of the literature. *J Neurosurg*. 2010 May;112(5):1061-9. doi: 10.3171/2009.7.JNS081504. PMID: 19698043.
4. Mascarenhas O. Anaesthesia management in craniovertebral junctional anomalies. *J Craniovertebr Junction Spine*. 2016 Oct-Dec;7(4):193-196. doi: 10.4103/0974-8237.193256. PMID: 27891026; PMCID: PMC5111318.
5. Branch JC, Cunningham's manual of practical anatomy, London Oxford press, volume 3, pages 258-295.
6. Salisbury JR, Deverell MH, Cookson MJ, Whimster WF. Three-dimensional reconstruction of human embryonic notochords: clue to the pathogenesis of chordoma. *J Pathol*. 1993 Sep;171(1):59-62. doi: 10.1002/path.1711710112. PMID: 8229458.
7. Singh, Neha & RAO, PARNANDI BHASKAR & Gupta, D. & Ambesh, Sushil. (2013). Anesthetic management of clival chordoma with retropharyngeal extension: Importance of imaging. *Anaesthesia, Pain and Intensive Care*. 17. 211-212.
8. Stippler M, Gardner PA, Snyderman CH, Carrau RL, Prevedello DM, Kassam AB. Endoscopic endonasal approach for clival chordomas. *Neurosurgery*. 2009



- Feb;64(2):268-77; discussion 277-8. doi: 10.1227/01.NEU.0000338071.01241.E2. PMID: 19190456.
9. Förander P, Bartek J Jr, Fagerlund M, Benmaklouf H, Dodoo E, Shamikh A, Stjärne P, Mathiesen T. Multidisciplinary management of clival chordomas; long-term clinical outcome in a single-institution consecutive series. *Acta Neurochir (Wien)*. 2017 Oct;159(10):1857-1868. doi: 10.1007/s00701-017-3266-1. Epub 2017 Jul 22. PMID: 28735379; PMCID: PMC5590026.
10. Ito E, Saito K, Okada T, Nagatani T, Nagasaka T. Long-term control of clival chordoma with initial aggressive surgical resection and gamma knife radiosurgery for recurrence. *Acta Neurochir (Wien)*. 2010 Jan;152(1):57-67; discussion 67. doi: 10.1007/s00701-009-0535-7. PMID: 19826755.
11. James E Cottrell MD, David Smith MD, PhD. *Anaesthesia and Neurosurgery*.
12. Hrayyer K, Shaninian, M Kabil MD, R Jarrahy MD, MP Thill MD. *Endoscopic Skull Base Surgery: A Comprehensive Guide with Illustrative Cases* 2008 Edition. Chapter 2, anaesthetic considerations.
13. Soltanpour P, Behnaz F, Azizi Faresani H, Seddighi A, Karimian M. Anesthetic Considerations in a Case With Massive Recurrent Clivus Chordoma. *Int Clin Neurosci J [Internet]*. 2019 Jun 29 [cited 2021 Dec 12];6(2):76-8. Available from: <https://journals.sbm.u.ac.ir/neuroscience/article/view/26258>
14. Jellish, W. S., Murdoch, J., & Leonetti, J. P. (2002). Perioperative management of complex skull base surgery: the anesthesiologist's point of view, *Neurosurgical Focus FOC*, 12(5), 1-7. Retrieved Dec 12, 2021, from <https://thejns.org/focus/view/journals/neurosurg-focus-focus/12/5/foc.2002.12.5.6.xml>
15. Abrams KJ, Grande CM. Airway management of the trauma patient with cervical spine injury. *Current Opinion in Anesthesiology*. 1994 Apr 1;7(2):184-90.
16. Bhatnagar V, Karmarkar AA, Dwivedi D, Ray A. Anesthetic management of excision of recurrent C2 chordoma with extension into posterior pharyngeal wall. *J Mar Med Soc* 2017;19:128-30.
17. Marda, Manish & Pandia, Mihir & Rath, Girija & Bithal, Parmod & Dash, Hari. (2013). Post-operative pulmonary complications in patients undergoing transoral odontoidectomy and posterior fixation for craniovertebral junction anomalies. *Journal of anaesthesiology, clinical pharmacology*. 29. 200-4. 10.4103/0970-9185.111720.
18. Sreedharan, R., & Farag, E. (2000). Airway Management in a Patient with an "Uncleared" Cervical Spine. In D. Doyle & B. Abdelmalak (Eds.), *Clinical Airway Management: An Illustrated Case-Based Approach* (pp. 227-231). Cambridge: Cambridge University Press.