



Dorsal Wrist Ganglion - Our Experience in its Management at Tertiary Care Centre

Authors

Dr K. Srinivasa Chakravarty M S¹, Dr Eppala Tejaswi^{2*}, Dr Gopi Chandra Goli³

¹Associate Professor, Department of General Surgery

^{2,3}Post Graduate, Department of General Surgery

*Corresponding Author

Dr Eppala Tejaswi

Post Graduate, Department of General Surgery

Abstract

Background: *Ganglion cyst is the most common soft tissue tumour of the hand. 60-70 % are present on dorsal aspect of wrist. They may affect any age group, however they are more common in 20s-40s. Although the pathogenesis is unclear, history of trauma is seen in 10% of cases. These cysts are filled with fluids, and most often, they appear and disappear very quickly and majority of them do not require treatment unless the cyst is painful, alters function of the wrist or deformed appearance*

Aims and Objectives: *To study the size of ganglion cyst, symptoms at presentation, management done and outcomes.*

Materials and Methods: *A Retrospective analysis of all the cases of dorsal wrist ganglion presented to Surgical OPD over a period of 1 year, June 2020 to may 2021 at Maharajah's Institute of Medical Sciences,, Vizianagaram and in them dorsal wrist ganglion cases were studied with respect to the size of the cyst, Symptoms at presentation, management done and outcomes.*

Results: *Total of 94 cases have been presented to Surgical OPD. Of it 60% cases are of size greater 2cm. Symptoms: 14 cases presented with pain, 6 cases presented with tingling sensation others for cosmetic appearance and apprehension of tumour.*

Management: *wait & watch(observation) for 36 cases of size less than 1cm; Immobilization (wrist brace or splint) for 8 cases which are arising from wrist joint; Aspiration &steroid injection(triamcelone) for 35 cases; Surgical excision for 15 cases which were recurrences from previous management and painful cases.*

Outcome: *recurrence is the most common complication. Success by surgical excision was 86% and aspiration &steroid injection was 75%.*

Conclusion: *Recurrence after management was the most common complication of dorsal wrist ganglions. Surgical excision is the most successful form of treatment followed by aspiration &steroid injection into the ganglion.*

Keywords: *Dorsal Wrist Ganglion, Excision, Aspiration and Injection.*

Introduction

Ganglion cyst is the most common soft tissue tumor of the hand. 60-70 % are present on dorsal aspect of wrist. They may affect any age group; however, they are more common in 20s-40s.

Although the pathogenesis is unclear, history of trauma is seen in 10% of cases. These cysts are filled with fluids, and most often, they appear and disappear very quickly.

Majority of them do not require treatment unless the cyst is painful, alters function of the wrist or deformed appearance

They are the most common tumor like conditions in the hand and wrist which usually arise from a pedicle in tendon sheath or joint capsule and located over scapholunate ligament.

There are a number of treatment modalities for ganglion, such as observation, aspiration, intralesional steroid injection, sclerotherapy and surgical excision, but none of these modalities has been the standard or best treatment.

Aims and Objectives

To study the size, symptoms at presentation, management done and outcomes of ganglion cyst.

Materials and Methods

Study Type: A Retrospective analysis

Study Centre: Department of General surgery, Maharajah's Institute of Medical Sciences, Vizianagaram

Study Period: 2 years, June 2019 to May 2021.

Study subjects: All the cases of dorsal wrist ganglion

Dorsal wrist ganglion cases were studied with respect to the size of the cyst, Symptoms at presentation, management done and outcomes.

Diagnosis of ganglion was based on history and clinical examination. All patients were informed and explained about the lesion and their treatment plan.

In some patients, radiological investigations like X-ray and ultrasonography were done to rule out other lesions.

Inclusion Criteria

1. Dorsal wrist ganglion of at least 1 cm in size
2. Patients older than 15 years (15-70 years)
3. Patients who are willing for follow-up.

Exclusion Criteria

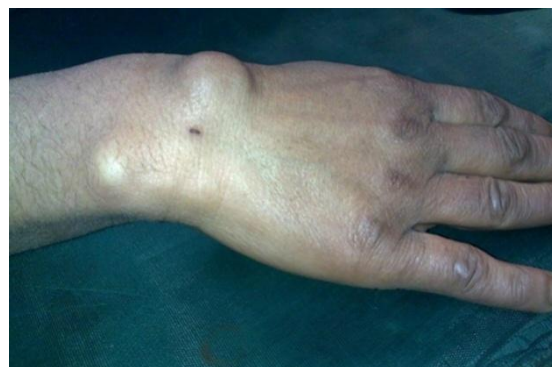1. Pediatric patients below the age of 15 years.
2. Patients refusing for investigations and treatment.
3. Those who are not willing to participate in the study.
4. Ganglion cysts present over other than dorsal wrist.

Results

Total of 94 cases have been presented to Surgical OPD.

Of it 60% cases are of size greater 2cm.

Symptoms: 14 cases presented with pain, 6 cases presented with tingling sensation others for cosmetic appearance and apprehension of tumor.



Photograph 1: Dorsal Wrist Ganglion

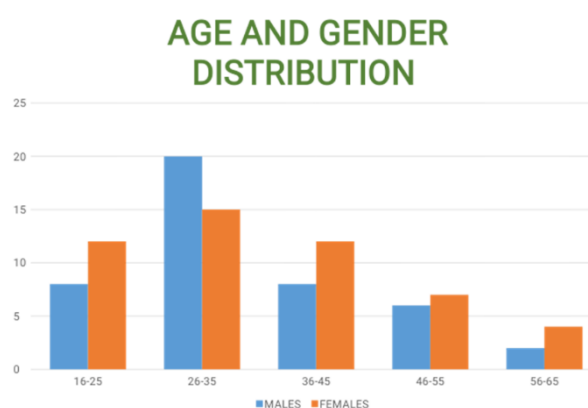


Figure 1: Age and Gender Distribution

Age group of 26-35 years have highest incidence of dorsal wrist ganglion
 Male to Female ratio 3:2
 60% of cases have dorsal wrist ganglion size > 2cm in the study

SIZE DISTRIBUTION

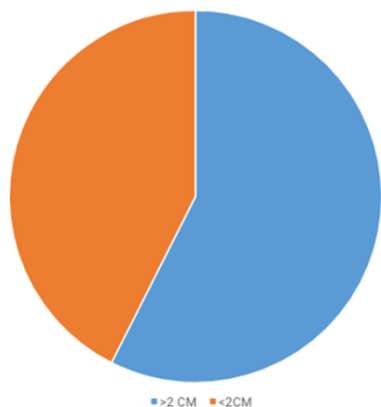
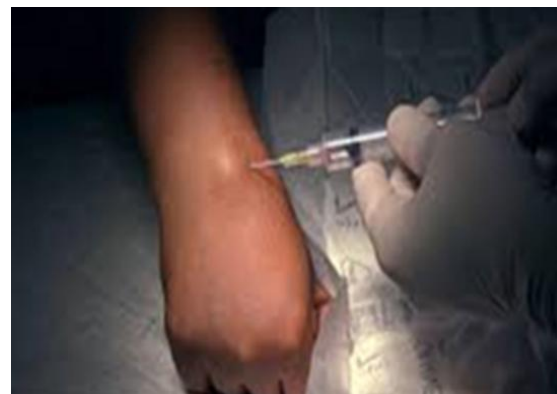
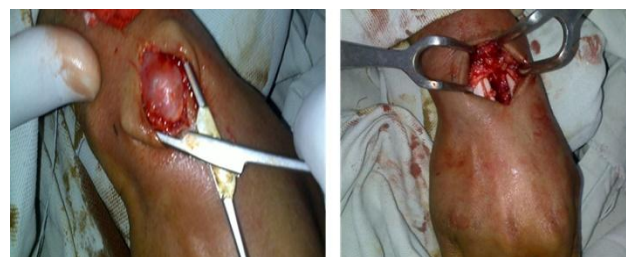
Figure 2: Size Distribution



Photograph 2: Aspiration and Injection of steroid



Photograph 3: Surgical Excision

Table1: Presenting Symptoms

	SYMPTOMS	CASES
1	PAIN	14
2	TINGLING SENSATION	6
3	OTHERS (COSMETIC, TUMOR APPREHENSION)	74

Management

- wait & watch(observation) for 36 cases of size less than 1cm;
- Immobilization (wrist brace or splint) for 8 cases which are arising from wrist joint;
- Aspiration & steroid injection (triamcelone) for 35 cases;
- Surgical excision for 15 cases which were recurrences from previous management and painful cases.

Table 2: Management

	MANGEMENT	CAUSE	NO OF CASES
1	WAIT & WATCH (OBSERVATION)	CYST LESS THAN 1 CM SIZE	36
2	IMMOBILIZATION (WRIST BRACE)	CYST ARISING FROM JOINT CAPSULE	8
3	ASPIRATION & STERIOD INJECTION	CYST GREATER THAN 2 CM SIZE	35
4	SURGICALEXCISION	RECURRENCES FROM PREVIOUS MANAGEMENT AND PAINFUL CYST	15

Outcome

- ✓ Recurrence is the most common complication.
- ✓ Success by surgical excision was 86% and
- ✓ aspiration & steroid injection was 75%

Discussion

Carpal ganglion cyst is the most common benign soft tissue tumor, including approximately 50-70% of the tumors of the hand and wrist area.

There are a number of treatment modalities for ganglion such as observation, aspiration, intralesional steroid injection, sclerotherapy and surgical excision, but none of these modalities has been the standard or best treatment.

The mean age of our patients at the time of presentation was 24.7 years.

Our study involved 94 patients with a male/female ratio of 3:2.

Wait & watch (Observation) was done for all the ganglion cyst size less than 1 cm which spontaneously get resolved without intervention
 Immobilization with hand brace was done for the cysts arising joint capsule and the cyst spontaneously resolved

Aspiration and injection Steroid (Triamcelone) was done for other cases which showed good results

Surgical excision was done for the recurrence cases of other treatment modalities and also for painful cysts.

Recurrence is the most common complication after management of dorsal wrist ganglion.

Surgical excision has the least incidence of recurrence of ganglion cyst.

Conclusion

Exact Pathogenesis of ganglion cyst is still unknown.

Recurrence after management was the most common complication of dorsal wrist ganglions.

Surgical excision is the most successful form of treatment followed by aspiration & steroid injection into the ganglion.

References

1. Stephen A, Lyons A, Davis T. A prospective study of two conservative treatments for ganglia of the wrist. *J Hand Surg Am.* 1999;24:104–5. [PubMed] [Google Scholar]
2. Nield DV, Evans DM. Aspiration of ganglia. *J Hand Surg Br.* 1986; 11:264. [PubMed] [Google Scholar]
3. Gang RK, Makhlof S. Treatment of ganglia by a thread technique. *J Hand Surg Br.* 1988;13:184–6.