



## A Rare Case of Renal Mucormycosis and its Management: A Case Report

Authors

**Dr Muqqurab Ali Khan S<sup>1</sup>, Dr Vamsi Krishna<sup>1</sup>, Dr Keerthana Kota<sup>1</sup>, Dr C.Nithish<sup>2</sup>**

<sup>1</sup>Department of Urology, Care Hospitals, Banjara Hills, Hyderabad

<sup>2</sup>Department of Pharmacology, Care Hospitals, Banjara Hills, Hyderabad

Corresponding Author

**Dr Muqqurab Ali Khan S**

Department of Urology, Care Hospitals, Banjara Hills, Hyderabad, India

### Introduction

Mucormycosis, which is also known as zygomycosis, refers to rare infections caused by fungi of the order of Mucorales, which are characterized by the production of aseptate hyphae and asexual spores<sup>[1]</sup>. Mucormycosis is more frequently seen in diabetic patients, followed by neutropenic patients, transplant recipients, patients with the haematological disease, patients on deferoxamine therapy, and IV drug users. The most common presentation of mucormycosis is rhinocerebral disease, followed by pulmonary, cutaneous, and disseminated diseases. Less commonly, mucormycosis can involve the kidneys<sup>[2,3]</sup>. Classically, invasive mucormycosis has been classified into six different clinical syndromes based on the general location of the disease: rhino-cerebral, pulmonary, gastrointestinal, cutaneous, disseminated and miscellaneous<sup>[4]</sup>. Renal involvement in disseminated mucormycosis occurs in up to 19% of patients<sup>[5]</sup>. As the *Mucorales* infections have an almost universal feature of extensive angioinvasion associated with thrombosis and ischemic necrosis, kidneys are similarly involved

in the process with consequent complications<sup>[6]</sup>. The clinical manifestations of renal mucormycosis depend upon whether the disease is unilateral or bilateral and whether it is disseminated or isolated to the kidney<sup>[7]</sup>.

Mucormycosis is a life-threatening and emerging disease in immunocompromised hosts in which patients usually develop relatively rapid angioinvasive fungal disease. Treatment options are limited. Only amphotericin formulations are reliably active to treat this disease. Mucorales species are usually resistant to antifungal agents commonly used to treat presumed fungal diseases, such as voriconazole and echinocandins<sup>[8]</sup>. The response of mucormycosis to antifungal agents is host and site-dependent and is particularly problematic in patients with haematological disorders or who have undergone HSCT<sup>[9,10]</sup>. A comprehensive review of patients with mucormycosis showed that dissemination developed in 23% of cases and was associated with 96% mortality<sup>[9,10]</sup>. Thus, early recognition of this disease along with aggressive management and appropriate antifungal treatment is critical for optimal outcomes<sup>[11,12]</sup>

Key Words: Renal Mucormycosis, PTCA, Thulium laser deroofing, isavuconazole

### Case Description

A 67-year-old male, known case of hypertension and diabetes was presented with complaints of Left loin pain radiating to the groin, burning micturition, decreased intake, drowsiness- since 1 week, Difficulty in micturition for 8 months. He also has a recent history of urosepsis, urine culture showed *Enterobacter aerogens*.

To the best of our knowledge, this is the first case report of Mucormycosis and the use of isavuconazole in India. This patient had multiple comorbidities like diabetes, hypertension, coronary artery Post-PTCA on antiplatelets. The patient has complaints of left-sided flank pain, difficulty with micturition and pain in the perineum for eight months. Ultrasound done at a peripheral centre showed left renal abscess and underwent left renal aspiration but the abscess did not resolve. Hence, pigtail insertion with DJ stenting was done on 12 December 2020. The patient developed myocardial infarction post-procedure and was found to have triple vessel disease for which he was on aspirin and ticagrelor<sup>[13]</sup>.

On examination, the patient was sick, dehydrated and pale. he was maintaining his vitals, on per abdominal examination tenderness was noted at the left renal angle with PCN insitu which was not draining. On per rectal examination, boggy prostate was felt and was diagnosed as a prostate abscess. The radiology CT image (figure.1) is suggestive of two hypodense around 3x2x2 cm was the largest, thick-walled peripherally enhancing lesions within the prostate, larger one toward the left side, suggesting prostatic abscess. A thick-walled exophytic hypodense collection of 7x5x6 cm with intrinsic air pockets is noted in the upper pole of the left kidney with surrounding perinephric fat stranding (figure.2)

Then Patient was planned for Thulium laser deroofing of prostate abscess and redo pigtail drainage of left renal abscess with left PCN

exchange. Intra op pus culture grew MDR pseudomonas and klebsiella, the fungal strain was suggestive of mucormycosis. Immediately patients have been treated with Isavuconazole 100mg twice a day<sup>[14]</sup> for 7Days, But there is no improvement and disease progression was severe. Left nephrectomy was done, demonstrated Gross appearance of nephrectomy specimen as shown in (Figure.3) tissue sent for HPE. He was monitored postoperatively and extubated the following day onto NIV. He later had recurrent episodes of fever, hypoxic, bradycardia requiring reintubation.

### Discussion

Although renal mucormycosis is rare and generally occurs as a part of disseminated disease, its presentation as renal abscess and the prostate abscess was seen in our case, The challenging task was patient have diabetes and a history of PTCA and was on Antiplatelets. Anti platelets were stopped 3 days before the surgery<sup>[15]</sup>. In this case, Thulium laser deroofing of the prostate was done, during the procedure, we found the presence of fungal strain was observed. Abscess culture was reported as Mucormycosis and was managed with Antifungals. In our case, Prostate abscess with renal mucormycosis has never been reported in English literature. Chakrabarti *et al*<sup>[16]</sup>. in their 10 years of experience reported two cases of isolated renal mucormycosis, who were treated with antifungal therapy alone but did not survive. Since mucormycosis is an angio-invasive fungus causing extensive necrosis, antifungal therapy alone fails because of poor tissue penetration. mucormycosis generally occurs in the immunocompromised host and has high mortality reported up to 75–100%. Survival after isolated renal mucormycosis has been reported to be 65% with combined surgical debridement and antifungal therapy<sup>[17]</sup>

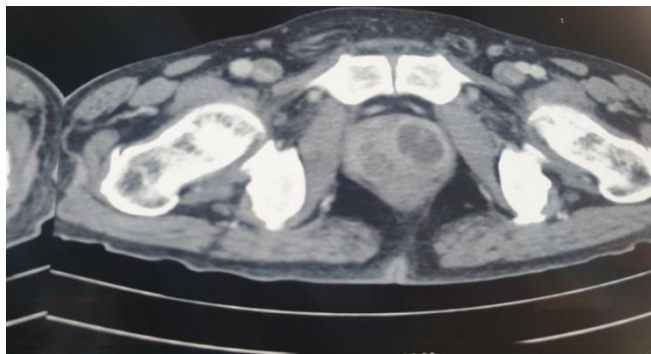


Figure 1

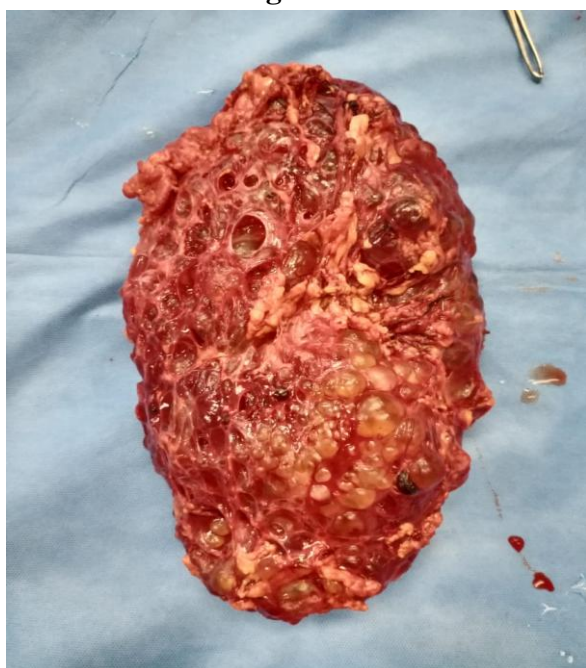


Figure 2

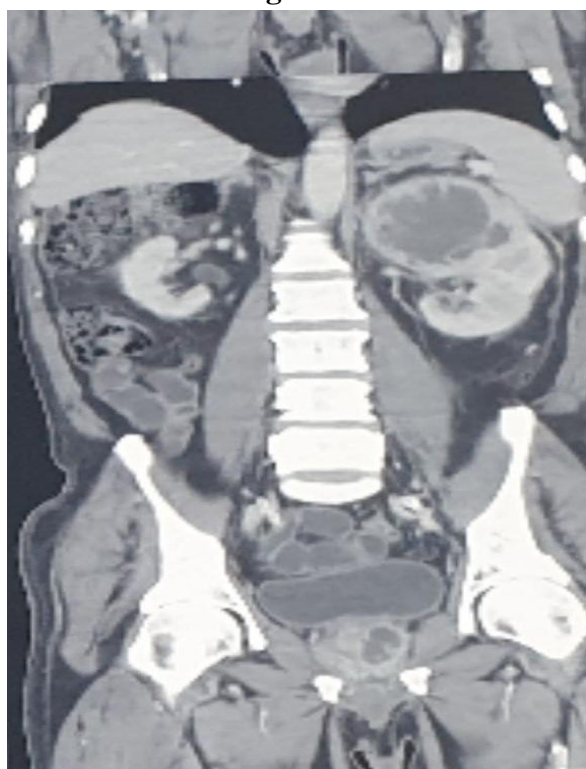

Figure 3

### Conclusion

This is high risk and rare presentation of Renal Mucormycosis case with multiple comorbidities. Thulium laser deroofing of prostate abscess and PCN was done, Isavuconazole was used and but no progress was observed with this antifungal. Hence left open Nephrectomy was done.

**Financial Support and Sponsorship:** Nil

**Conflict of Interest:** Nil

**Acknowledgements:** None

### Reference

1. D. P. Kontoyiannis et.al., "Zygomycosis in the 1990s in a tertiary-care cancer center," *Clinical Infectious Diseases*, vol. 30, no. 6, pp. 851–856,2000.
2. J. Brown, "Zygomycosis: an emerging fungal infection," *American Journal of Health-System Pharmacy*, vol. 62, no. 24, pp. 2593–2596, 2005.
3. N.CrumCianflone, "Mucormycosis," *Emedicine*, <http://emedicine.medscape.com/article/222551-overview>.
4. Roden MM, Zaoutis TE, et.al., *Epidemiology and outcome of zygomycosis: a review of 929 reported cases. Clin Infect Dis.* 2005 1;41(5):634-53.
5. Chakrabarti A, Das A, Sharma A, Panda N, Das S, Gupta KL, et al. Ten years' experience in zygomycosis at a tertiary care centre in India. *J Infect* 2001;42:261-6.
6. Zygomycetes in human disease Ribes JA, Vanover-Sams CL, Baker DJ *Clin Microbiol Rev.* 2000 Apr; 13(2):236-301.
7. *Epidemiology and outcome of zygomycosis: a review of 929 reported cases.*
8. Spellberg B, Edwards J Jr, and Ibrahim A. 2005. Novel perspectives on mucormycosis: pathophysiology, presentation, and management. *Clin. Microbiol. Rev.* 18:556–569.
9. Roden MM, Zaoutis TE, Buchanan WL, Knudsen TA, Sarkisova TA, Schaufele RL,

- Sein M, Sein T, Chiou CC, Chu JH, Kontoyiannis DP, and Walsh TJ. 2005
10. Epidemiology and outcome of zygomycosis: a review of 929 reported cases. *Clin. Infect. Dis.* 41:634–653.
  11. Spellberg B, Edwards J Jr, and Ibrahim A. 2005. Novel perspectives on mucormycosis: pathophysiology, presentation, and management. *Clin. Microbiol. Rev.* 18:556–569, 5.
  12. Hammond SP, Baden LR, and Marty FM. 2011. Mortality in hematologic malignancy and hematopoietic stem cell transplant patients with mucormycosis, 2001 to 2009. *Antimicrob. Agents Chemother.* 55:5018–5021
  13. Deepak L Bhatt et.al., Ticagrelor in patients with diabetes and stable coronary artery disease with a history of previous percutaneous coronary intervention (THEMIS-PCI): a phase 3, placebo-controlled, randomised trial., *The Lancet*: Published online September 1, 2019.
  14. Bianca Graves et.al., Isavuconazole as salvage therapy for mucormycosis *Medical Mycology Case Reports* Volume 11, March 2016, Pages 36-39.
  15. Dimitrova, G., Tulman, D. B., & Bergese, S. D. (2012). Perioperative management of antiplatelet therapy in patients with drug-eluting stents. *HSR proceedings in intensive care & cardiovascular anesthesia*, 4(3), 153–167.
  16. Chakrabarti A, Das A, Sharma A, Panda N, Das S, Gupta KL, et al. Ten years' experience in zygomycosis at a tertiary care centre in India. *J Infect.* 2001;42:261–6.
  17. Verma R, Vij M, Agrawal V, Jain M. Renal mucormycosis in immunocompetent patients: Report of three cases. *Basic Appl Pathol.* 2011;4:66–70.