



Incidence of Various Neck Swellings in a Tertiary Health Care Establishment in Central India

Authors

Navin Agrawal¹, Sanjay K Gupta², Saket Bansal^{3*}, Vishal Hansrajani⁴,
Anand Sharma⁵, Saurabh Vijay⁶

^{1,2,3,4,5,6}Department of ENT, IMCHRC, Indore (M.P.), India

*Corresponding Author

Saket Bansal

Abstract

Aim: To find out the incidence of various types of neck swellings in patients presenting to a tertiary health care establishment in Central India.

Materials and Methods: All the patients presenting with the complaint of neck swelling in the last one year were taken in the study regardless of the age group or the gender of the patient. The incidence of various neck swellings were evaluated taking into account the correlation of the clinical examination, USG and the FNAC reports of the patient.

Results: Total 96 cases were included in the study. Of all the patients, almost two third patients were females. Almost two third females had thyroid gland swellings. Most of the people were in the 31-40 years of age group. Most of the patients had thyroid swellings. Next in incidence were lymph node swellings.

Conclusion: The present study shows that the patients presenting with neck swelling usually turn out to be thyroid swelling in our setting. The need of the hour is nationwide public enlightenment campaigns to help in the proper management of various neck swellings.

Keywords: Neck swelling, USG, FNAC.

Introduction

Neck swellings are frequently encountered in clinical practice in a country like India. They can prove to be an important reason of significant morbidity and mortality. The etiology of neck masses ranges from benign or congenital lesions to acquired or neoplastic lesions which may also present in late childhood.⁽¹⁻⁵⁾ There can be a variety of neck swellings like goitre, tubercular lymphadenitis, pleomorphic adenoma, lipoma, sebaceous cyst etc. Neck malignancy forms a significant fraction of the various neoplasms in India. 23% of all the cancers in males and 6% of

all the cancers in females occur in the neck. The increased prevalence of neck swellings in India can be because of use of tobacco in various forms, poor oro-dental hygiene and viral infections.⁽⁶⁻⁸⁾

Proper diagnosis of the neck swellings can prove to be a challenge in underdeveloped and developing countries. If properly evaluated, timely diagnosis of neck swellings can help in reducing significant morbidity. Various imaging modalities like Ultrasonography, CT scan, MRI can prove to be useful in the effective, non-invasive evaluation of neck swellings and ascertain its relationship to adjacent soft tissue and bony structures.⁽⁹⁻¹¹⁾

However, these imaging modalities are costly and unavailable in some centres with limited resources.

In the last two decades, fine needle aspiration cytology (FNAC) has become an important tool in the evaluation of the various neck swellings. This is because of the high degree of cost effectiveness, diagnostic accuracy and minimal disruptive nature of the procedure. It can prove to be an important tool for correct diagnosis, not only for neoplastic lesions of the neck but also for inflammatory, infective and degenerative neck lesions as well.^(8,12)

Aims and Objectives

1. To evaluate the incidence of various neck swellings in patients presenting to a tertiary health care establishment.
2. To evaluate the incidence of various types of thyroid, salivary glands and lymph nodal swellings.

Materials and Methods

This retrospective study was carried out in the department of Otorhinolaryngology in a tertiary

health care establishment in Central India. All the patients presenting with neck swellings in the last one year were evaluated in terms of their final diagnosis based on their clinical examination, ultrasonography and FNAC reports correlation.

Inclusion Criteria

All the patients presenting to the department of Otorhinolaryngology with neck swelling were included in the study regardless of the age group of the patient or gender.

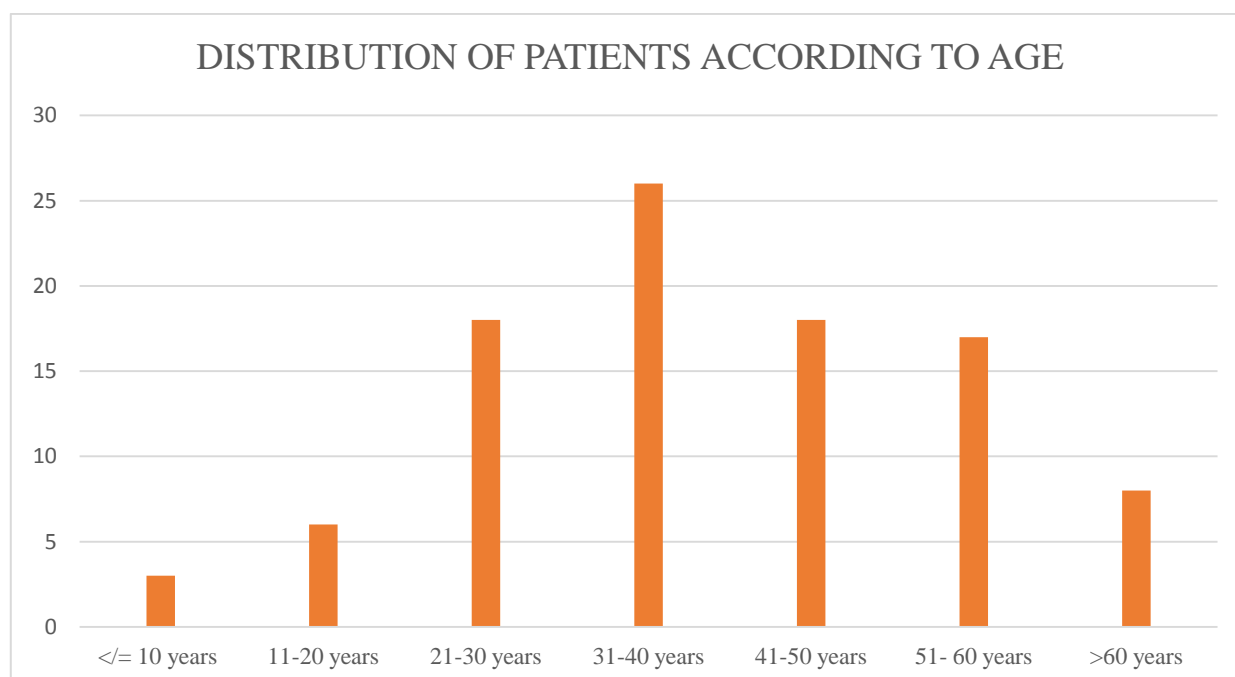
Exclusion Criteria

Patients not giving consent for the study.

Observations and Results

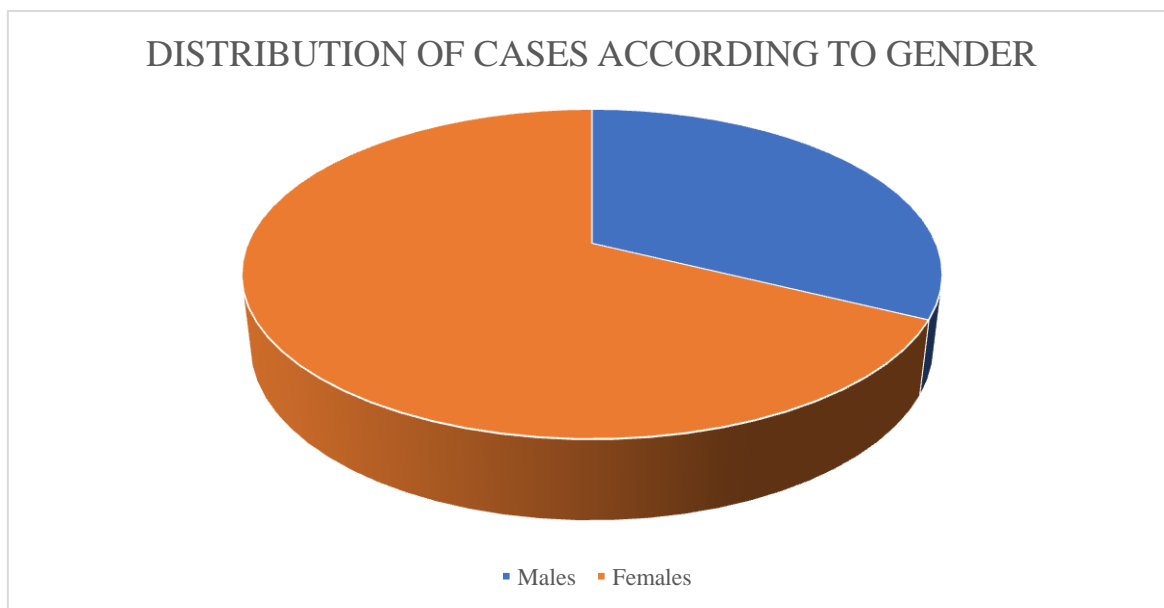
There were 96 cases in this study, those who presented with the complaint of neck swelling within the duration of 1 year (November 2018 to October 2019).

Age groups (in years)	Number of cases	%
<= 10	3	3.13%
11-20	6	6.25%
21-30	18	18.75%
31-40	26	27.08%
41-50	18	18.75%
51-60	17	17.71%
>60	8	8.33%
Total	96	100%



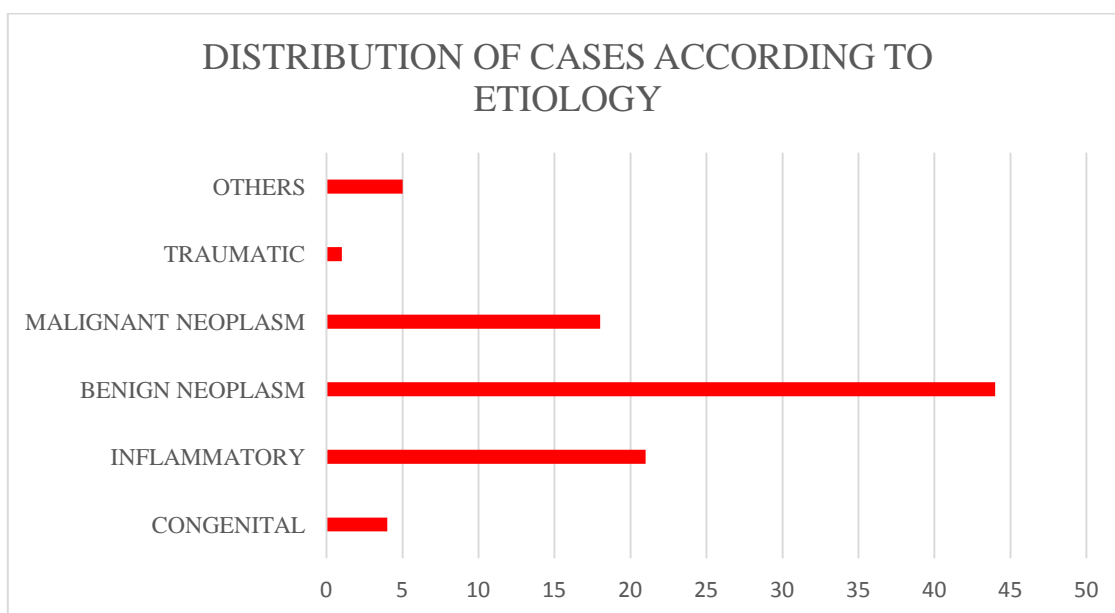
Most of the people in the study were in the age group of 31-40 years, who constituted more than 1/4th of the total number of cases. Next in incidence were the age groups 21-30 and 41-50 years, having 18 cases (18.75%) each.

Gender	Number of cases	%
Male	31	32.29%
Female	65	67.71%



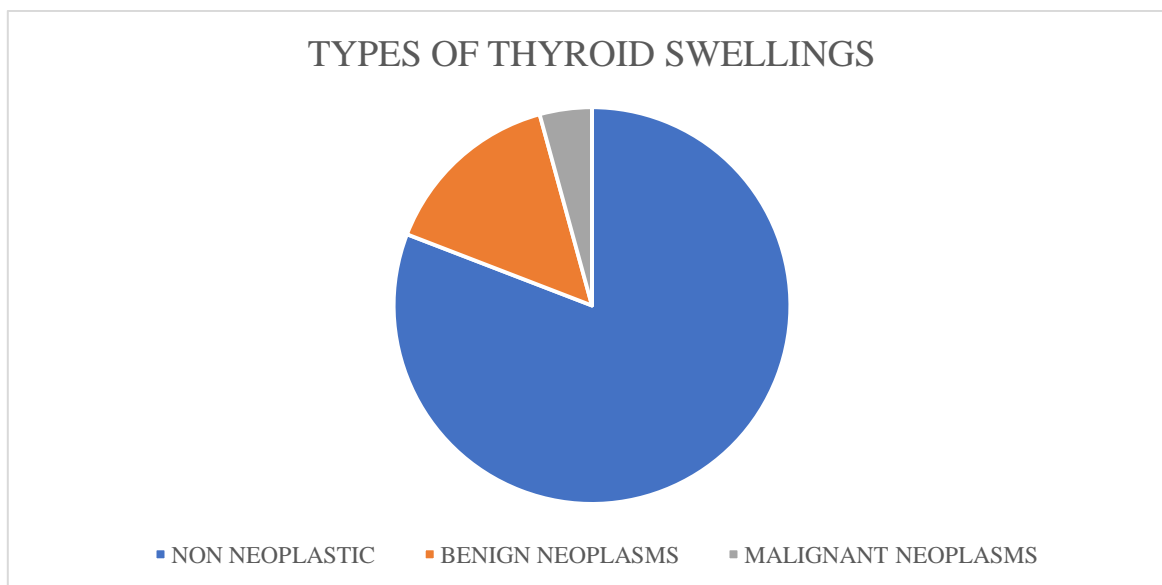
About 2/3rd patients in the study were females. They made up a total of 65(67.71%) against 31(32.29%) males.

Etiology	Number of cases	%
Congenital	4	4.30%
Inflammatory	21	22.58%
Benign neoplasm	44	47.31%
Malignant neoplasm	18	19.35%
Traumatic	1	1.08%
Others	5	5.38%



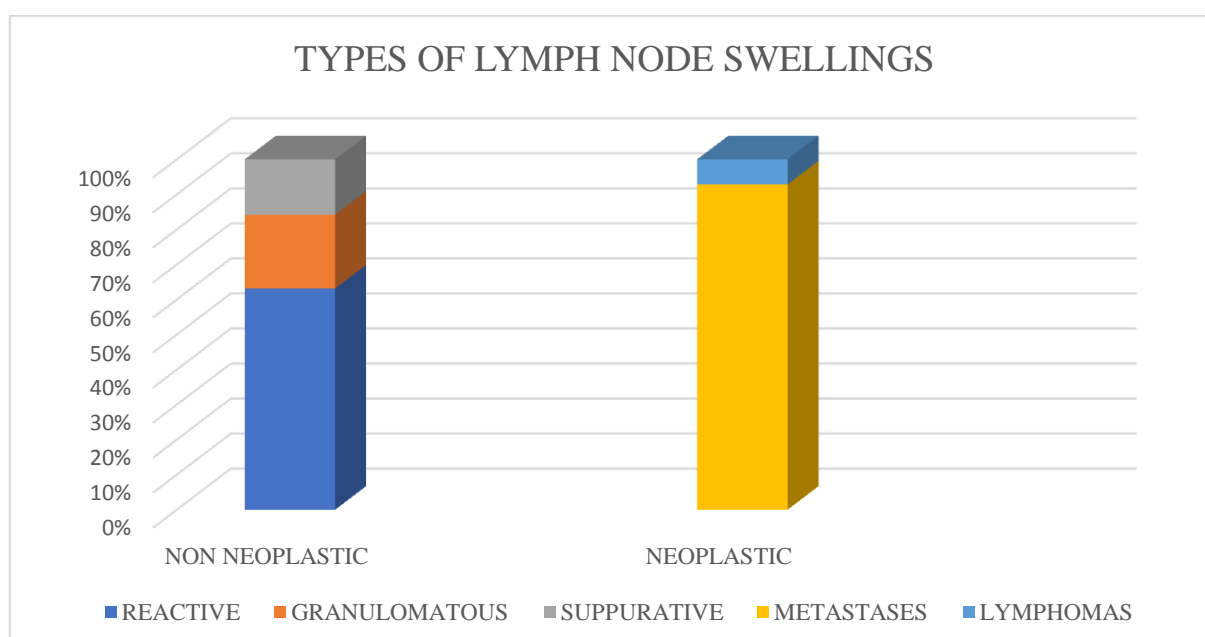
Almost half the cases of all neck swellings turned out to be benign conditions. Most of the neck swellings were thyroid swellings. Next in incidence was lymph nodal swellings. Almost 63% females had some or the other swelling of the thyroid gland. The commonest diagnosis was colloid goitre followed by neck secondary's.

Thyroid swelling type	Number of cases	%
Non neoplastic	38	80.85%
Benign neoplasm	7	14.89%
Malignant neoplasm	2	4.26%



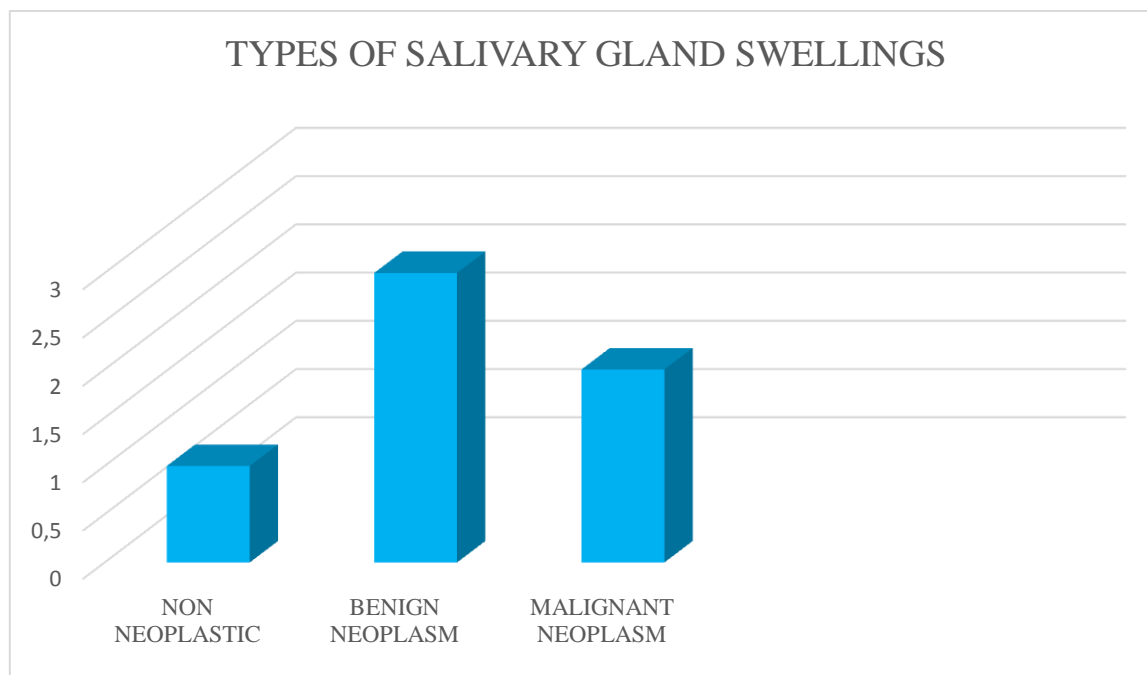
More than 3/4th (38) thyroid swellings were non neoplastic. Rest of the swellings turned out to be benign or malignant neoplasms.

Lymph node swelling	Number of cases	%
1) Non neoplastic		
Reactive	12	36.36%
Granulomatous	4	12.12%
Suppurative	3	9.1%
2) Neoplastic		
Metastases	13	39.39%
Lymphomas	1	3.03%



There were comparatively more non neoplastic (19) than neoplastic lymph node swellings (14). The neoplastic lesions were mostly neck secondaries.

Salivary gland swelling	Number of cases	%
Non neoplastic	1	16.67%
Benign neoplasm	3	50%
Malignant neoplasm	2	33.33%



Half of the salivary gland swellings (3 cases) were benign neoplasms. Rest of the swellings were either non neoplastic or had a malignancy.

Discussion

The evaluation of the various neck swellings can prove to be a challenge for health care providers. The differential diagnoses of neck swellings range from inflammatory neck swellings to malignancies. Proper history taking and clinical examination are very important for the initial evaluation of such patients. FNAC is also helpful mainly because of its high diagnostic accuracy. In this study, the diagnostic yield of the FNAC was almost 97%.

The neck masses in the paediatric age group are broad and include congenital, inflammatory and neoplastic lesions.⁽¹³⁾ In the present study, similar to other reports, most common lesions in the paediatric age group were benign conditions.⁽¹⁴⁾ According to one study, most of the people were in the third decade of their life.⁽¹⁵⁾ This is in contrast to our study in which most of the people were in the age group of 31-40 years.

In our review, about 68% of the patients were females and remaining were males. In a similar

study,⁽¹⁵⁾ about 75% patients with neck swellings were females while about 1/4th were males.

In this study, we found that most of the neck swellings were benign neoplasms or inflammatory conditions. Some of the attempts by Mohamed MH et al.⁽¹⁶⁾ and Cheng AT et al.⁽¹⁷⁾ showed that inflammatory and nonneoplastic conditions are more common in the developing countries while malignant neck conditions are more common in the developed countries.

Among all the neck swellings, most of the swellings seen in our study were thyroid swellings. Of all the thyroid lesions in our study, most of the cases were having the final diagnosis as colloid goitre. This is similar to the study done by Savithri et al.⁽¹⁸⁾ and others⁽¹⁵⁾ in which most common neck swelling was colloid goitre. Kumar V et al. also reported that most of the lesions of the thyroid were benign neoplasms.⁽¹⁹⁾

In the present case series, most of the lymph nodal masses were inflammatory/infectious lesions. This is in concordance with the study done by

Matsumoto F et al.⁽²⁰⁾ where similar findings were seen. However, in one study⁽²¹⁾ most of the lymph nodal masses were neoplastic (mostly lymphoma cases). In a study by Manjula K et al.⁽²²⁾ and similar studies^(23,24,25,26), the most common diagnosis was tubercular lymphadenitis which ranged from around 20-60%.

There were very few cases of salivary gland swellings in our study. But, most of the salivary gland swellings turned out to be benign conditions. Rice DH et al.⁽²⁷⁾ and Shishegar M et al.⁽²⁸⁾ also found more cases of benign neoplasms of the salivary glands than malignant neoplasms in their studies.

FNAC is a safe choice for evaluation of all the neck masses because even if the mass is malignant then also the chance of the needle seeding of the neoplastic cells while performing the procedure is 0.003-0.009%.⁽¹⁶⁾ This feature makes FNAC much safer than excision biopsy.

Conclusion

It can be concluded that most of the people with neck masses seeking medical care in this study were people having thyroid swellings. Of all the thyroid swellings, most common one was colloid goitre. It won't be wrong to add that though neck swellings can be a diagnostic puzzle for health care providers, if properly evaluated and investigated they can be diagnosed and treated on time.

References

1. Turkington JR, Paterson A, Sweeney LE, Thornbury GD: Neck masses in children. *Br J Radiol* 2005, 78:75–85.
2. Tracy TF, Muratore CS: Management of common head and neck masses. *Semin Pediatr Surg* 2007, 16:3–13.
3. Osifo OD, Ugiagbe EE: Neck masses in children: Etiopathology in a tertiary center. *Niger J Clin Pract* 2011, 14:232–236.
4. Maharjan M, Hirachan S, Kafle PK, Bista M, Shrestha S, Toran KC: Incidence of tuberculosis in enlarged neck nodes, our experience. *Kathmadu Univ Med J* 2009, 7:54–58.
5. Al-Khateeb TH, Al Zoubi F: Congenital neck masses: A descriptive retrospective study of 252 cases. *J Oral Maxillofac Surg* 2007, 6:2242–2247.
6. Popat CV, Vora D, Shah H. Clinico-pathological correlation of neck lesions – A study of 103 cases. *The internet journal of head and neck surgery*. 2010;4(2):DOI: 10.5580/450.
7. Mehrotra R, Singh M, Kumar D, Pandey AN, Gupta RK, Sinha US. Age specific incidence rate and pathological spectrum of oral cancer in Allahabad. *Indian J Med Sci*. 2003;57:400–4.
8. Rahman MA, Biswas MMA, Sikder AM. Scenario of fine needle aspiration cytology of neck masses in a tertiary care hospital. *J Enam Med Col*. 2011;1(1):8–14.
9. Malik A, Odita J, Rodriguez J, Hardjasudarma M: Pediatric neck masses: a pictorial review for practicing radiologists. *Curr Probl Diagn Radiol* 2002,31:146–157.
10. Meuwly J, Lepori D, Theumann N, Schnyder P, Etehami G, Hohlfeld J, Gudinchet F: Multimodality imaging evaluation of the pediatric neck: techniques and spectrum of findings. *Radio Graph* 2005, 25:931–994.
11. Swischuk LE, John SD: Neck masses in infants and children. *Radiol Clin North Am* 1997, 35:1329–1340.
12. Advani SK, Dahar A, Aqil S. Role of fine needle aspiration cytology (FNAC) in neck masses/cervical lymphadenopathy. *Pak J Chest Med*. 2008;14(3):9–14.
13. Turkyilmaz Z, Karabulut R, Bayazit YA, Sonmez K, Koybasioglu A, Yilmaz M, et al. Congenital neck masses in children and their embryologic and clinical features. *B-ENT*. 2008;4(1):7–18. [PubMed:18500016]

14. Dickson PV, Davidoff AM. Malignant neoplasms of the head and neck. *Semin Pediatr Surg.* 2006;15(2):92–8. doi: 10.1053/j.sempedsurg.2006.02.006. [PubMed: 16616312]
15. Prakash H Muddegowda, Shuba Srinivasan, Jyothi B Lingegowda, Ramkumar Kurpad R and K Sathiya Murthy. Spectrum of Cytology of Neck Lesions: Comparative Study from Two Centers. *J Clin Diagn Res.* 2014 Mar; 8(3): 44-45.
16. Mohamed MH, Hitam S, Brito-Mutunayagam S, Yunus MRM. Role of FNAC in evaluation of neck masses. *J Curr Surg.* 2013;3(1):19-23.
17. Cheng AT, Dorman B. Fine needle aspiration cytology: the Auckland experience. *Aust N Z J Surg.* 1992;62:368-72.
18. Savithri C, Dimple D, Dholakia A. Fine needle aspiration cytology of neck lesion – An experience at tertiary care hospital in central Gujarat. *National journal of medical research.* 2012;2(3):255-9.
19. Kumar V, Abbas AK, Aster JC. *Robbins and Cotran Pathologic Basis of Disease* Elsevier Science Health Science Division; 2014.
20. Matsumoto F, Itoh S, Ohba S, Yokoi H, Furukawa M, Ikeda K. Biopsy of cervical lymph node. *Auris Nasus Larynx.* 2009;36(1):71–4. doi: 10.1016/j.anl.2008.03.008. [PubMed: 18479855]
21. Soussan Irani, Farahnaz Bidari Zerehpoush and Shahram Sabeti. Prevalence of Pathological Entities in Neck Masses: A Study of 1208 Consecutive Cases. *Avicenna J Dent Res.* 2016 June; 8(1): e25614.
22. Manjula K., C.S.B.R. Prasad, Gayathri B.N., Harendra Kumar M.L. Cytomorphological study of Lateral Neck Swellings. *Journal of clinical and diagnostic research.* 2011 Oct; 5:1016-1019.
23. Ahmad T, Naeem M, Ahmad S, Samad A, Nasir A. Fine needle aspiration cytology and neck swellings in the surgical outpatient. *J Ayub Coll Abbottabad* 2008; 20: 30-32.
24. Hag IA, Chiedozi LC, Reyees AFA, Kollur SM. Fine needle aspiration cytology of head and neck masses. Seven year's Experience in a secondary care Hospital. *Acta Cytol* 2003; 47:387-92.
25. Gupta RK, Naran S, Lallu S, Fauck R. The diagnostic value of fine needle aspiration Cytology in the assessment of palpable supraclavicular lymph nodes - a study of 218 Cases. *Cytopathology*; 8:511-14.
26. Lawrence C, Imad AH, Shara NMNM. Study of Fine Needle Aspiration of head and Neck masses. *Acta Cytol*; 47:387-92.
27. Rice DH. Salivary gland disorders. Neoplastic and nonneoplastic. *Med Clin North Am.* 1999;83(1):197–218. [PubMed: 9927970].
28. Shishegar M, Ashraf MJ, Azarpira N, Khademi B, Hashemi B, Ashrafi A. Salivary gland tumors in maxillofacial region: a retrospective study of 130 cases in a southern Iranian population. *Patholog Res Int.* 2011;2011:934350. doi: 10.4061/2011/934350. [PubMed: 21776345].