



Hereditary Progressive Arthro-ophthalmodystrophy -Stickler Syndrome- A Rare Case Report

Authors

**Dr (Prof) Vijay Bhaisare¹, Dr Jaishree Lilani², Dr Sanchaikya Thakur³,
Dr Isha Gupta^{3#}**

¹Head of the Department Ophthalmology, MGM Medical College

²Post Graduate Junior Resident Ophthalmology

³Senior Resident Department of Ophthalmology

^{3#}Ex -Senior Resident Department of Ophthalmology, Currently Resident in Aravind Eye Institute
Pondicherry, India

Introduction

- It is a progressive autosomal dominant connective tissue disorder due mutation in type ii procollagen (COL2A1) located at long arm of chromosome 12.
- **Systemic Features**
- Premature Osteoarthritis
- Hearing Loss
- Skeletal and facial malformations (hypoplasias, cleft palate, depressed nasal bridge)
- Cardiovascular Abnormalities

Ocular Features

- Retinal Detachment
- Glaucoma
- Premature Cataract
- High Myopia
- Viterous Liquefaction
- Retinal Pigmentary Changes

Case Report

Mother (25 years of age)- Diminution of vision in both eyes-15 years


Both eyes cataract surgery done 10 years back (RE-SICS; LE-SICS with PCIOL). Use of thick glasses since 5 years.

Son (6 years of age) - Diminution of vision in both eyes -4years. Both eyes cataract surgery done 5 years back (RE-SICS; LE-SICS with PCIOL)

General Examination

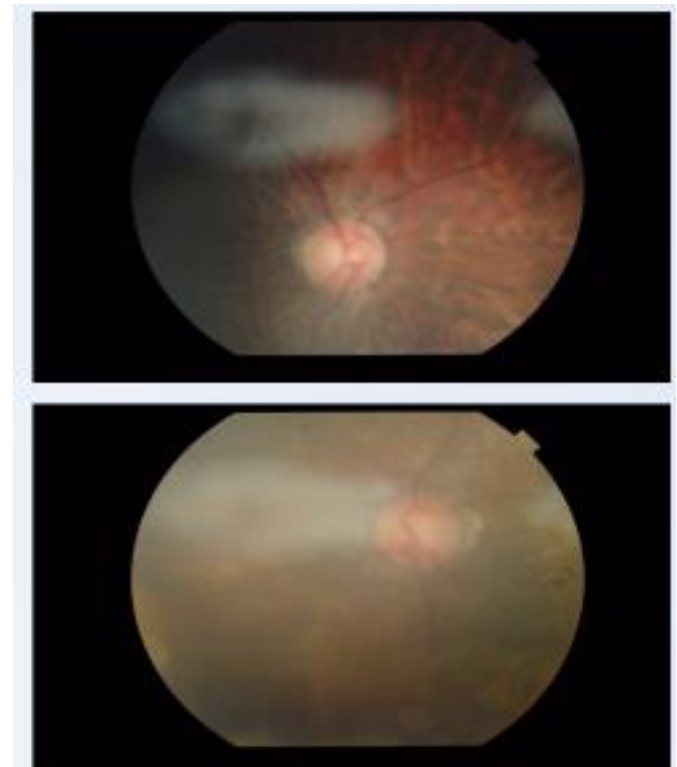
Mother

- Short Stature (138 CM)
- Depressed Nasal Bridge
- Bifid Uvula
- Low IQ
- Moderate B/L Sensorineural Hearing Loss.



Son

- Short Stature (<2sd for Normal Age & Sex).
- Depressed Nasal Bridge.
- Saddle Nose Deformity
- Bilateral Temporoparietal Bone Flattening
- Right Ventricular Hypertrophy (ECHO Cardiography).

**Ocular Examination****Mother**

- RE- 6/60 BCVA- PH-6/60-aphakic-optic atrophy
- LE- 6/60 BCVA- PH-6/24-pseudophakic-high myopic fundus with disc pallor
- Both eye vitreous sineresis present.

Intra Ocular Pressure- RE- 16MM OF HG.

- LE-19.3 MM OF HG.
- Both Eye Jerky Nystagmus Present.

Son

RE-6/36 BCVA-6/24-aphakic-tessellated myopic fundus

LE-6/60BCVA-6/36-pseudophakic-temporal pallor with large cup 0.5:1

Both eye vitreous sineresis present.

Intra Ocular Pressure- RE- 17.7MM OF HG.

- LE-20 MM OF HG.
- Both Eye Jerky Nystagmus Present.

Discussion

Stickler syndrome is believed to be a direct result of abnormalities in the production of collagen types II, IX and XI, all of which are recognized as components of the human vitreous. The condition has been divided into subgroups based on ocular and systemic clinical findings, with each subgroup also corresponding to a specific genetic defect. The most common ocular findings in Stickler syndrome are vitreous syneresis in a membranous or beaded configuration and radial perivascular retinal lattice degeneration, both of which are present in up to 100% of affected patients.

Differential diagnosis

The differential diagnosis includes other type II/XI collagenopathies:

- Knobloch syndrome
- Wagner syndrome
- Multiple epiphyseal dysplasia
- Kniest dysplasia (Metatropic dwarfism, type II)

Management

Regular monthly follow up to limit vision loss and to improve the quality of life of affected patients.

References

1. Stickler G. Hereditary Progressive Arthro-Ophthalmopathy. Mayo Clinic proceedings. 1965-06; 40:433-55.
2. Snead M. Stickler syndrome, ocular-only variants and a key diagnostic role for the ophthalmologist. Eye (London). 2011-11;25:1389-400.
3. Pediatric Ophthalmology and Strabismus, Section 6. Basic and Clinical Science Course, AAO, 2011-2012.
4. E.S. Parma, J. Korkko, W.S. Hagler, L. Ala-Kokko. Radial perivascular retinal degeneration: a key to the clinical diagnosis of an ocular variant of Stickler syndrome with minimal or no systemic manifestations. Am J Ophthalmol, 134 (2002), pp. 728–734
5. Kanski J.clinical ophthalmology, 3rd ed. London :Butterworths,1994,417-418.