



Traumatic Cataract in Young

Authors

Dr (Lt Col) Rishi Sharma*¹, Dr (Col) B.V Rao², Dr (Col) Rakesh Maggon³

^{1,2}Military Hospital Yol, Himachal Pradesh

³Department of Ophthalmology, Command Hospital (WC), Chandigarh

*Corresponding Author

Dr. (Lt Col) Rishi Sharma

Military Hospital Yol, Himachal Pradesh, India

Abstract

27 year-old male patient presented with history of trauma to his left eye one month back sustained with pin of a rifle while cleaning the weapons in his unit. Post injury, he developed pain, redness and diminution of vision in the left eye. Vision at presentation was 6/6 unaided in the right eye and 6/24 in the left eye with no further improvement. Lids and adnexa were normal with no retained foreign body in both eyes. Right eye anterior segment and fundus evaluation was normal. Left eye had clear cornea, no cells and flare in AC, no hyphema. Pupillary reactions were normal, no iris sphincter tear was seen. Rosette shaped cataract was seen. Fundus examination was normal. Phacoemulsification with Intraocular lens implantation was done. Post-operative day vision was 6/6 unaided, clear cornea, mild AC reaction normal reacting pupil with well centred IOL in capsular bag. IOP was 16 and 19 mm Hg. Patient was placed on topical antibiotic and steroid eye drops. He has been kept on regular follow-up.

Keywords: Rosette cataract, Closed globe injury, Irrigation/Aspiration.

Introduction

The incidence of ocular trauma is relatively common despite the anatomic and functional protective mechanisms of the visual system. It occurs most frequently in men and young people.¹ World Health Organization estimated that up to 55 million eye injuries occur annually worldwide and approximately 1.6 million people lose their vision due to eye trauma.² Several guidelines for ocular trauma have been published to help determine the visual prognosis.³ Visual outcome generally depends on the initial visual acuity, pupillary reflex response, and severity of the trauma.⁴ In this article, we will focus on the presentation and management of injury to the lens and, in particular, traumatic cataract.

Case History

A 27 year-old male patient presented with history of trauma to his left eye one month back sustained with pin of a rifle while cleaning the weapons in his unit. Post injury he developed pain, redness and diminution of vision in the left eye. Vision at presentation was 6/6 unaided in the right eye and 6/24 in the left eye with no further improvement. Lids and adnexa were normal with no retained foreign body in both eyes. Right eye anterior segment and fundus evaluation was normal. Left eye had clear cornea, no cells and flare in AC, no hyphema. Pupillary reactions were normal, no iris sphincter tear was seen. Rosette shaped cataract was seen. no lens subluxation/ zonular dialysis/ phacodonesis. Fundus examination was normal.

Ultrasonography B Scan of both eyes was normal. IOP was 16 mm Hg(RE) and 18 mm Hg(LE) with applanation tonometry.

The individual was taken up for cataract surgery. Bimanual I/A was used for removal followed by Intraocular lens implantation. Postoperative day #1 vision (figure 2) was 6/6 unaided, clear cornea, mild AC reaction normal reacting pupil with well centred IOL in capsular bag. IOP was 14 and 16 mm Hg .Patient was placed on topical antibiotic and steroid eye drops. Postoperative week #1 his vision was 6/5. He has been kept on regular follow-up. Last check up(after 01 month) revealed vision of 6/5 unaided in the left eye, clear cornea, quiet AC, and well centred IOL in capsular bag. Fundus- normal. IOP- 13 and 14 mm Hg with applanation tonometry. Gonioscopy revealed open angles grade 4 with no signs of angle recession both eyes. The steroid antibiotic drops were tapered off as per the standard regime followed. The patient has been counselled and advised to report immediately in case of pain, redness, diminution of vision, floaters, and flashes in the operated eye. On follow-up visual acuity, IOP recording, detailed slit lamp bio microscopy to rule out any uveitis, intraocular lens decentration, synechiae, pupillary capture and posterior capsular opacification were done. Posterior segment evaluation was done with indirect ophthalmoscopy.

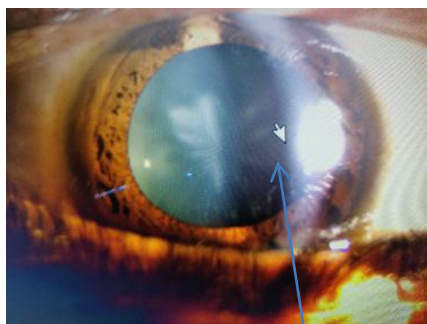


Figure 1: Rosette shaped cataract

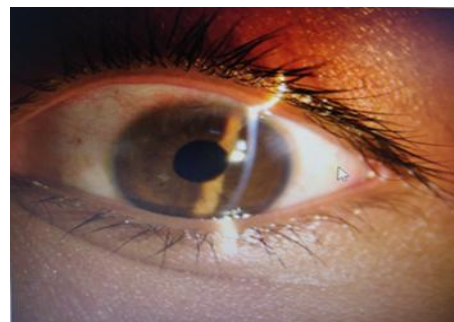


Figure 2: 1st post-op day

Discussion

Blunt or penetrating ocular trauma resulting in traumatic cataract that results from either needs special consideration because of associated injury to ocular and periorbital structures. Surgery of traumatic cataract can be primary or secondary. Primary cataract removal is suggested if the lens is fragmented, swollen causing a pupillary block or to examine the posterior segment otherwise blocked by lens opacity. Secondary cataract removal is more beneficial because of improved visibility, proper intraocular lens calculation, and less chances of postoperative inflammation⁵

The morphology of traumatic cataracts plays an important role in determining the appropriate surgical technique and the final visual outcome.⁶ In this case the cataract was Rosette shaped (Figure 1) with no associated injury to the surrounding ocular structures therefore, we used I/A Cannula to aspirate the lens after good hydrodissection. This is in consonance with study done by Shah, M. A., S. M. Shah, Shashank Shah et al.⁷ They stated that the surgical technique should be selected according to morphology and the condition of tissues other than the lens. They advocated the use of Phacoemulsification to operate on cataracts with hard, large nuclei. With a lens that has either a white soft or rosette type of cataract, they used of bimanual/co-xialaspiration. Membranectomy and anterior vitrectomy, either via an anterior pars plana route, in case the cataract was membranous. Implantation of intraocular lens (IOL) in traumatized eyes after removal of traumatic cataract depends on availability of capsular support. In capsular bag or sulcusfixation is preferred if there is sufficient

capsular and Zonular support. Patients with insufficient capsular or Zonular support are the candidate for Artisan lenses, scleral fixation IOLS and anterior chamber IOLS. One must assess and consider the capsular bag's long term stability for intracapsular fixation of the IOL.^{8,9,10} In this case the capsule and the bag were intact therefore IOL could be placed in the capsular bag .

Post-operative inflammation is a common complication following traumatic cataracts, hampering visual outcome. Other complications leading to decreased post-operative vision are corneal scar, uveitis, secondary glaucoma, pupillary capture, posterior capsular opacification and retinal scar.¹¹ The major postoperative complications encountered on first postoperative day is severe uveitis which responds to medical therapy. Cheema and coworker reported that the fibrinous uveitis was the most common postoperative complication (25%).¹² It may mainly be due to surgical trauma in an already traumatized eye and not related to type or location of IOL inside the eye. The commonest late postoperative complication in these traumatic cataractous eyes is posterior capsular opacification seen at 6 months postoperatively. Eckstein and colleagues reported that posterior capsular opacity was seen in almost 92%.¹³

The patient has been kept on follow-up for early diagnosis and management of these complications including Cystoid macular edema which may warrant an OCT in case of diminution of vision.

Conclusion

Traumatic cataract resulting from ocular trauma is a common cause of ocular morbidity, especially in young population. Management of traumatic cataract for good visual outcomes requires a holistic approach consisting of meticulous pre-op evaluation, uneventful surgery and post-op follow-up to evaluate and manage any delayed complication which could hinder post-op recovery of vision.

Conflicts of Interest: None

References

1. Serna-Ojeda JC et al. Int Ophthalmol. 2015; 35(4):451-458.
2. Négrel AD, Thylefors B. Ophthalmic Epidemiol. 1998;5(3):143-169.
3. Kuhn F, Morris R, Witherspoon CD, et al. The Birmingham eye trauma terminology system (BETT). J Fr Ophtalmol 2004;27 (2):206-10.
4. Mian ST, Azar DT, Colby K. Management of traumatic cataracts. Int Ophthalmol Clin 2002; 42:23-31.
5. Mester V, Kuhn F. Lens. In: Kuhn F, Pieramici DJ, editors. Ocular trauma: principles and practice. New York (NY): Thieme; 2002.
6. Mehul AS, Shreya MS, Shashank BS, Patel UA. Effect of interval between time of injury and timing of intervention on final visual outcome in cases of traumatic cataract. Eur J Ophthalmol 2011; 21:760-5.
7. Shah, M. A., S. M. Shah, Shashank Shah et al. Morphology of traumatic cataract: does it play a role in final visual outcome? BMJ Open 2011;1: e000060.
8. Sminia ML, Odenthal MT, Wenniger-Prick LJ, Gortzak-Moorstein N, Völker-Dieben HJ. Traumatic paediatric cataract: a decade of follow-up after artisan aphakia intraocular lens implantation. J AAPOS 2007; 11:555-8. Epub 2007 Aug 27.
9. Buckley EG. Hanging by a thread: The long-term efficacy and safety of transscleral sutured intraocular lenses in children (an American Ophthalmological Society thesis). Trans Am Ophthalmol Soc 2007; 105:294-311.
10. Bekibele CO, Fasina O. Visual outcome of traumatic cataract surgery in Ibadan, Nigeria. Niger J Clin Pract 2008;11(4): 372-5.

11. Mohammadpour M, Jafarinasab MR, Javadi MA. Outcomes of acute postoperative inflammation after cataract surgery. *Eur J Ophthalmol* 2007;17(1):20-8.
12. Cheema RA, Lukran AD. Visual recovery in unilateral traumatic paediatric cataracts related with posterior chamber intraocular lens and anterior vitrectomy in Pakistan. *Int Ophthalmol* 1999; 23:85-9.
13. Eckstein M, Vijaya Lakshmi P, Kelladar M, Gilbert C, Foster A. Use of intraocular lens in children with traumatic cataract in South India. *Br J Ophthalmol* 1998; 82:911-5.