



Review Article

Evaluation Study on Ilizarov Principles of Deformity Correction

Author

Dr R.A.M. Kausarul Islam¹

¹Assistant Professor, Orthopedic Surgery Department, NITOR, Dhaka, Bangladesh

Corresponding Author

Dr R.A.M. Kausarul Islam

Abstract

Limb-lengthening surgery can be outlined back to the 19th Century. Since that time, the orthopedic community has made remarkable progress in performing successful lengthening procedures. Dr. Gavril Ilizarov is one of the leading physicians among the important contributors to the field of lengthening surgery. Because of advancements over the past century, limb lengthening has become a viable method of treating severe bony deformities and defects. The aim of this article is to reviews the principles of deformity correction in limb lengthening surgery for distraction osteosynthesis and its evaluation including a thorough discussion of indications, instrumentation, and surgical technique.

Keyword: *Limb- lengthening, Orthopedics community, deformity correction, osteosynthesis.*

Introduction

In the 1950s, Prof. Gavriil Abramovich Ilizarov started his career giving treatment to some patients in Western Siberia, who had been suffering sustained fractures happened from the Second World War. In 1954 he began his assignment experimenting with external fixation designs and successfully treated his first patient, a factory worker with a tibial non-union. His outstanding results significantly reduced healing time. He also discovered distraction osteogenesis for bone lengthening, observed callus formation of a patient who mistakenly distracted his frame rather than compressing. In 1968, Valery Brumel, an Olympic champion high jumper of 1964 games, visited Ilizarov in Kurgan. He had been suffered a compound fracture of his distal tibia from 1965. Despite 20 operations over 3 years, he

infected a significant non-union leg-length discrepancy. His successful surgery widely publicized and gained Ilizarov recognition within the Soviet Union. In 1980, Carlo Mauri, a well-known Italian journalist, suffered a distal tibial fracture of 10 years, by a mountain accident, successfully treated in Kurgan. On his return to Italy, the surgeons were amazed by the treatments of Ilizarov. His findings were presented at the AO Conference in Bellagio. Since Ilizarov's significant steps have been made in motivating the advancing biology of limb lengthening. His initiated works confirmed with further studies across the United States and Europe. In a study, it has been found that the ligaments and capsule stretched gradually tension to improve joint contractures, while nerves, vessels, and muscles have been shown to stretch by local neogenesis.¹

Distraction osteogenesis is a term which describes the de novo production of bone between corticotomy surfaces. New bone forms by a process resembling intramembranous ossification.^{1,2} Endochondral ossifications may also be present within the normal intramembranous.² Whether these areas of endochondral ossification within the regenerate are normal or not is controversial. Some investigators argue that its occurrence is inherent to the normal process of regenerate formation.^{3,4} However Ilizarov and others have argued that its presence is indicative of instability or of localized ischemia.⁵⁻⁸ The site where the transported segment meets the target segment at the end of bone transport is termed the “docking site”^{9,10} which is histologically different from that of the regenerate. There is a progressive increase in the quantity of bony tissue with concomitant decrease, which finally disappearance of necrotic tissue and hematoma. Ilizarov and others describe “zone growth”.^{1,6,7,11} Zone growth argues that the process of regenerate ossification occurs simultaneously in the regions adjacent to the osteotomies surfaces. The fibrous inter-zone, a collagen-rich central region, is the last zone to ossify. Under optimal conditions, this growth zone is hardly visible during distraction. During the neutral fixation period following a distraction, the central growth zone gradually ossifies. Fibroblast-like cells become metabolically active and secrete collagen. The collagen eventually forms fibers that align parallel to the distraction force. Osteoblast activity results in osteoid and eventually new bone formation.

Basic science and principles of distraction osteogenesis

A chain of experiments was conducted over 10 years, using 65 dogs to comprehend better the process of distraction osteogenesis.¹² These experiments found that ideal conditions included stable fixation, a low energy osteotomy followed by 5–7-day latency and a distraction rate of 1mm/day in 3 or 4 divided increments.^{13, 14} These findings were paralleled clinically in human

studies.¹⁵ Prior to these studies, the rate, and rhythm of distraction were not considered important.^{16, 17} New bone trabeculae form directly from this central collagen zone extending to both bone surfaces.¹⁸ It is orientated parallel to the distraction force and surrounded by blood vessels. Following distraction, these micro columns consolidate and rapidly remodel to form a structure similar in composition to that of the host bone, a process called consolidation. Up to 10% lengthening is well-tolerated by muscle, but substantial histopathological changes occur after lengthening of 30%.¹⁹⁻²¹ Nerves, arteries, and veins had histological evidence of temporary degenerative changes but these disappeared 2 months after lengthening.^{22,23} Short-term changes in articular cartilage of the knee in the tibial lengthening of rabbits showed that the cartilage underwent histopathological changes, including the reduced thickness of the hypertrophic and proliferative zones.²⁴

Mechanical principles of the Ilizarov method

The success of the Ilizarov method trusts on the presence and mutual function of several biologic and mechanical factors. Ilizarov observed that for bone to realize its full osteogenic potential, a versatile fixation system was needed that would provide stability, soft tissue preservation, adjustability, and functionality. Unique features of the Ilizarov frame and method are the use of a stable yet dynamic frame that allows the surgeon the options of acute and gradual correction, frame modularity to build as complex a frame as needed, and the ability of the patient to bear weight and move adjacent joints as tolerated. Round fixators are contained of several apparatuses with rings and connecting rods. Full rings provide the principal rigidity; partial rings and arches are particularly supportive when working near joints of bone. Bony firmness is important for osteogenesis and depends on the steadiness of the external frame. Frame stability is impressively impacted by the ring properties; rings of huge diameter are less

stable than smaller rings.²⁵ Reducing ring diameter by 2 cm increases axial frame stiffness by 70%;²⁶ therefore, the smallest diameter ring which fits the edge should be used. A general guideline is to go away 2cm space between ring and skin circumferentially to permit possible limb swelling. Distance between the rings will affect stability; rings that are far apart and connected with long rods are will be less stable. So to reduce the unsupported length between rings, additional connecting rods or an intermediate free ring secured within the mid-portion of the long rods. The steadiness of the ring is further increased by using two rings rather than one for every bone segment for controlling both near and much ends of every bone segment. A minimum of four connecting rods between the rings and a minimum of two points of fixation or wires per ring are required.²⁷ Atrophic non-unions require double-ring blocks to extend the steadiness of the construct. In hypertrophic non-unions, one ring block per segment would be sufficient as long as no deformity correction is required. Lengthening frames usually gain and sustain additional stability from distraction forces needed to beat the soft tissue envelope; therefore, one ring per segment with multiple wires in several planes would be used. The ring frame supports and stabilizes the underlying bone through the utilization of transfixion wires and half pins. Frame stability increases with increasing wire diameter and tension, the utilization of more wires per ring, placing wires on opposite sides of the ring and inserting wires in several planes. Increasing crossing angles of wires to 90° provides maximal stability and crossing angles of but 60° may allow the bone to slip along the wires requiring the utilization of opposing olive wires or the addition of a half pin.⁶ Olive wires provide a crucial buttress effect within the correction of angular deformity.²⁷ Thorough knowledge of the cross-sectional anatomy of the extremity is important to avoid neurovascular injury. If under a

general anesthetic, the patient shouldn't receive paralytic agents as this may mask the important signs of muscle flickering when a nerve is irritated. It's important to attenuate the warmth generated during wire drilling to stop bone and soft tissue necrosis. Wire tensioning greatly enhances the rigidity of the wire and stability of the frame.²⁸ Smooth wires are typically tensioned to 130 Nm as tension beyond 155 Nm will cause stretching and plastic deformity of the wire.²⁹ Wires crossing an angle of but 60° should be tensioned simultaneously to make sure equal tension across both wires. Studies comparing wire only frames and combination half-pin frames have shown that the utilization of half-pins increased the bending and torsional stiffness of the frame.³⁰ Hydroxyapatite-coated pins became increasingly popular, especially in limb lengthening and deformity surgery where the frames stay for several months. Hydroxyapatite-coated pins are shown to possess increased extraction torque, lower rates of loosening and decreased infection rates.^{31, 32} Deformity correction is often achieved using hinges on the connecting rods but this needs very accurate frame construction³³ to avoid lengthening, compression or translation. As a consequence, hexapod systems, like Taylor-special frames, became popular. Readings on six oblique struts and measurements taken from post-operative radiographs are fed into a computer virus to supply a protocol for daily adjustments to correct a deformity.

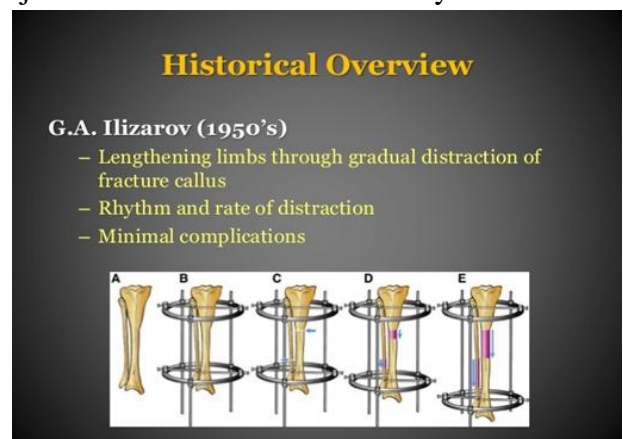


Figure -1: Historical Overview of Prof. G.A. Ilizarov's Lengthening Surgical Techniques

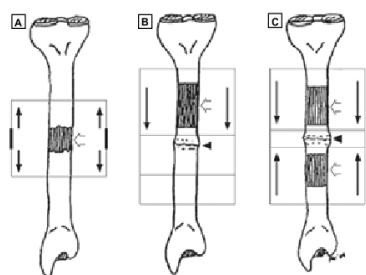


Figure -2: Three types of distraction osteogenesis: Monofocal, bifocal, and trifocal.

Limb lengthening

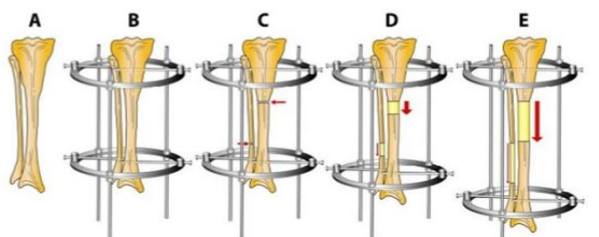


Figure -3: Insight of Limb Lengthening Surgery

Procedure...

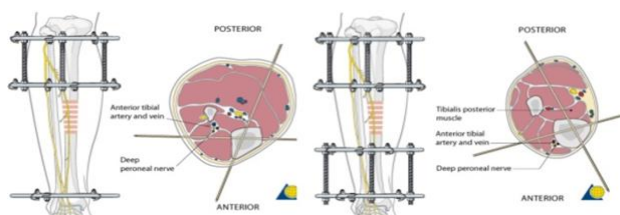


Figure 4: Procedure of Limb Lengthening Surgery

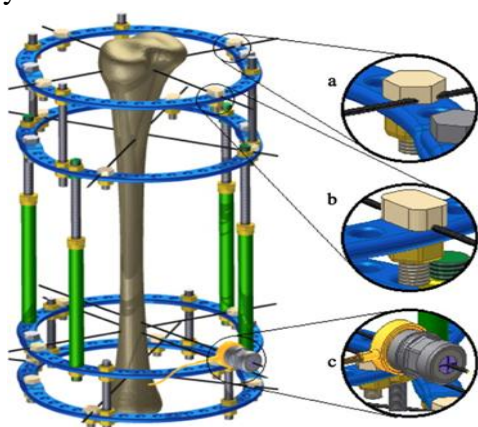


Figure-5: Wire tensioning with integrated load-cell in the Ilizarov orthopedic external fixation system

Clinical use of Ilizarov external fixators

Comprehensive anatomical alignment and rotation knowledge requires for deformity assessment. Usually, the contralateral limb is often used as a reference and radiographs are a routine a part of deformity and leg-length discrepancy investigation. A full-length, standing, anteroposterior radiograph of both lower limbs, using blocks under the short leg to level the pelvis, is taken. Anteroposterior and lateral radiographs will guide management and supply a template for pre-operative planning. To correct the leg-length discrepancy, Acorticotomy is executed to correct, the bone is exposed and therefore the periosteum incised and elevated paying careful attention to preserve its integrity. Using a 4.8-mm drill, holes are made circumferentially through the cortex and therefore the corticotomy is completed using an osteotome. To correct angular deformity, an awareness of the traditional mechanical axis is required. This represents a line drawn from the middle of the femoral head to the middle of the ankle mortice. The situation of this line in reference to the knee defines the mechanical axis deviation, normally 0–8 mm medial to the middle of the knee. The location of the deformity must be identified and mid-diaphyseal lines are often drawn on a radiograph on either side of a deformity. A corrective osteotomy at this site will allow angular correction without translation. In cases where there are length discrepancy and angular deformity, correction is often made at one level, the CORA, if bone regeneration potential is sweet. Alternatively, a double level osteotomy could also be performed, one at CORA for deformity correction and one at the advised level for lengthening. Gradual correction and lengthening use the principle of ‘distraction osteogenesis’. Bone and soft tissue are gradually distractedatarateof1mmperdayinfourdividedincrements. Bone growth within the distraction gap is named regenerate. The interval between osteotomy and lengthening is named the latency stage and is typically 7–10 days. The correction and lengthening are called the distraction phase.

The time from the top of distraction until the bony union is named the consolidation phase. Methods of bone separation that disrupt the periosteum, like widely displaced corticotomies or osteotomies, may result in decreased osteogenesis.³⁴ The optimum thanks to treating hypertrophic non-unions are via gradual distraction to realize normal alignment. Only modest lengthening of 1.5cm is often achieved through the non-union. If additional lengthening is required, an extra corticotomy will get to be performed. In atrophic non-unions, the treatment must be directed to enhance the biology and mechanical environment of the union site. Atrophic non-unions should be exposed and bone ends contoured so there's healthy bleeding bone on each side with good contact. Acute correction of deformity should be followed by bone grafting and stable fixation with compression. In infected non-unions, the non-union must be exposed and everyone infected bone removed by opening of intramedullary canals with thorough washout. The bone should be excised back to bleeding surfaces and apposed with good contact and correction of the deformity. The patient should ideally have been receiving antibiotics for several weeks and multiple intra-operative specimens for culture and pathology should be sent. The bone graft shouldn't be utilized in the first surgery if there's a niche between the 2 bone ends antibiotic beads are often used for dead-space management. Several weeks later, the antibiotic beads are often removed and therefore the non- union are often bone grafted.³⁵

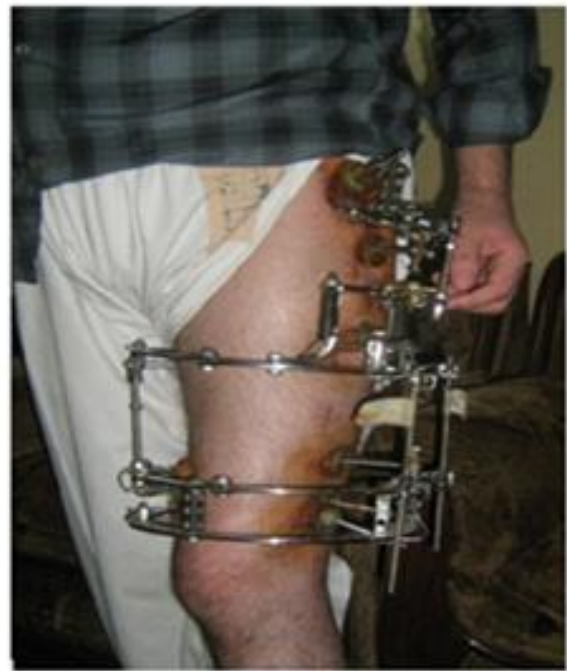

Figure -6: Clinical Procedure of Llizavo Limb Lengthening Surgery (Arms)

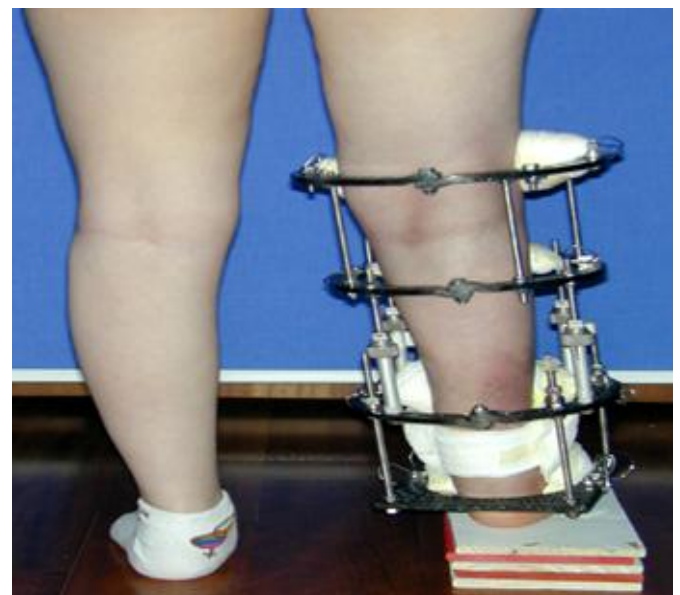


Figure 7: Clinical Procedure of Llizavo Limb Lengthening Surgery (Leg)

Complications

Early complications like pain, bleeding that can result in hematoma or compartment syndrome. Direct damage of neurovascular structures, deep vein thrombosis, pulmonary embolism, and nerve injury could happen of stretching. Infection, especially of the pin sites, which almost 95%. However with local pin care, with or without oral administration of antibiotics for 5 days, resolved

97%.³⁶ Soft tissue contractures, subluxation, and contracture of the joint are more serious complications. They can, however, be minimized with preoperative planning, including protection against subluxation by spanning of the joint with the fixator and with intensive therapy and splinting during the fixation period.³⁷ Late complications include chronic recurrent pin-site infections, osteomyelitis, premature union if a distraction is too slow or delayed or non-union, hardware failure, reflex sympathetic dystrophy, late bowing, and fracture. The rate of complications decreases substantially as the experience of the surgeon increases. In one study, major complications followed 69% Ilizarov lengthening performed in the first 6-month period of experience, but only 35% in the third 6-month period.³⁸ The rate of minor complications remained constant independent of the experience of the surgeon and the type of fixator.

Conclusion

Surgical limb lengthening and bone transportation techniques have undertaken significant evolution over the past century. While numerous potential complications still exist, most complications are now minor and simply treatable. Osteogenesis has become a viable treatment option when applied during a cooperative patient by a surgeon with appropriate training. Advances in technique still be made, and therefore the introduction of latest devices has made ring external fixation a more accessible treatment option. Ilizarov frames provide a flexible fixation system that provides stability, soft tissue preservation, adjustability, and functionality. of these factors are vital for the bone to understand its full osteogenic potential. A pre-operative plan is important with careful selection of patients who are going to be ready to adhere to the strict postoperative regimen of lengthening and angular correction to avoid late complications

References

1. Aronson J, Harrison BH, Stewart CL, Harp JH Jr. The histology of distraction osteogenesis using different external fixators. *Clin Orthop Relat Res.* 1989 Apr; (241):106-16.
2. Garcia FL, Picado CH, Garcia SB. Histology of the regenerate and docking site in bone transport. *Arch Orthop Trauma Surg.* 2009 Apr; 129(4):549-58.
3. Kojimoto H, Yasui N, Goto T, et al. Bone lengthening in rabbits by callus distraction. The role of periosteum and endosteum. *J Bone Joint Surg Br.* 1988 Aug; 70(4):543-9.
4. Kusec V, Jelic M, Borovecki F, et al. Distraction osteogenesis by Ilizarov and unilateral external fixators in a canine model. *Int Orthop.* 2003; 27(1):47-52.
5. Li G, Simpson AH, Triffitt JT. The role of chondrocytes in intramembranous and endochondral ossification during distraction osteogenesis in the rabbit. *Calcif Tissue Int.* 1999 Apr; 64(4):310-7.
6. Ilizarov GA. Clinical application of the tension-stress effect for limb lengthening. *Clin Orthop Relat Res.* 1990 Jan ; (250):8-26.
7. Murray JH, Fitch RD. Distraction Histiogenesis: Principles and Indications. *J Am Acad Orthop Surg.* 1996 Nov; 4(6): 31727.
8. Jazrawi LM, Majeska RJ, Klein ML, et al. Bone and cartilage formation in an experimental model of distraction osteogenesis. *J Orthop Trauma.* 1998 Feb; 12(2):111-6.
9. Aronson J, Harrison B, Boyd CM, et al. Mechanical induction of osteogenesis: the importance of pin rigidity. *J Pediatr Orthop.* 1988 Jul-Aug;8(4):396-401.
10. Aronson J, Harrison B, Boyd CM, et al. Mechanical induction of Osteogenesis. Preliminary studies. *Ann Clin Lab Sci.* 1988 May-Jun; 18(3):195-203.

11. Aronson J, Johnson E, Harp JH. Local bone transportation for treatment of intercalary defects by the Ilizarov technique. *Biomechanical and clinical considerations. Clin Orthop Relat Res.* 1989Jun ;(243):71-9.
12. Ilizarov GA, Ledyasev VI, Shitin VP. Experimental studies of bone lengthening. *Eksp Khir Anesteziol* 1969; 14: 3.
13. Ilizarov GA. The tension–stress effect on the genesis and growth of tissues: Part I. The influence of stability of fixation and sort tissue preservation. *Clin Orthop* 1989; 238: 249–81.
14. Ilizarov GA. The tension-stress effect on the genesis and growth of tissues: Part II. The influence of the rate and frequency of distraction. *Clin Orthop* 1989; 239: 263–85.
15. Ilizarov GA. Clinical application of the tension-stress effect for limb lengthening. *ClinOrthop* 1990; 250: 8–26.
16. Codivilla A. On the means of lengthening in the lower limbs, the muscles and tissues which are shortened through deformity. *Am J OrthopSurg* 1905; 2: 353–69.
17. Wagner H. Operative lengthening of the femur. *ClinOrthop* 1978; 136: 125–42.
18. Vauhkonen M, Peltonen J, Karaharju E, Aalto K, Alitalo I. Collagen synthesis and mineralization in the early phase of distraction bone healing. *Bone Miner* 1990; 10: 171–81.
19. Kaljumae U, Martson A, Haviko T, Hanninen O. The effect of lengthening of the femur on the extensors of the knee. An electromyographic study. *J Bone Joint Surg Am* 1995; 77: 247–50.
20. Paley D. Problems, obstacles and complications of limb lengthening by the Ilizarov technique. *Clin Orthop* 1990; 250: 81–104.
21. Lee DY, Choi IH, Chung CY Chung PH, Chi JG, Suh YL. Effect of tibial lengthening on the gastrocnemius muscle. A histopathologic and morphometric study in rabbits. *Acta Orthop Scand* 1993; 64: 688–92.
22. Ippolito E, Peretti G, Bellocchi M, Farsetti P, Tudisco C, Caterini R et al. Histology and ultrastructure of arteries, veins and peripheral nerves during limb lengthening. *Clin Orthop* 1994; 308: 54–62.
23. Galardi G, Comi G, Lozza L, Marchettini P, Novarina M, Facchini R et al. Peripheral nerve damage during limb lengthening. *Neurophysiology in five cases of bilateral tibial lengthening. J Bone Joint Surg Br* 1990; 72: 121–4.
24. Lee DY, Chung CY, Choi IH. Longitudinal growth of the rabbit tibia after callotasis. *J Bone Joint Surg Br* 1993; 75: 898–903.
25. Cross AR, Lewis DD, Murphy ST. Effects of ring diameter and wire tension on the axial biomechanics of four ring circular external fixator constructs. *Am J Vet Res* 2001; 62: 1025–30.
26. Gasser B, Boman B, Wyder D. Stiffness characteristics of the circular Ilizarov device asopposed to conventional external fixators. *J Biomech Eng* 1990; 112: 15–21.
27. Rozbruch SR, Ilizarov S. *Limb Lengthening and Reconstruction Surgery.* New York: Informa Healthcare, 2007
28. Podolsky A, Chao EY. Mechanical performance of Ilizarov circular frame external fixators in comparison with other external fixators. *Clin Orthop* 1993; 293: 61–70.
29. Ilizarov GA, Emilyanova HS, Lebedev BE. Some experimental studies. Mechanical characteristics of Kirschner wires. In: Perosseus compression and distraction osteosynthesis. *Traumatology and Orthopaedics. Kurgan, 1972l; 34–47.*
30. Calhoun JH, Li F, Bauford WL. Rigidity of half pins for the Ilizarov external fixator. *Bull Hosp J Dis* 1992; 52: 21–6.

31. Piza G, Caja VL, Gonzalez-Viejo MA. Hydroxyapatite-coated external-fixation pins. The effect on pin loosening and pin-tract infection in lengthening for short stature. *J Bone Joint Surg Br* 2004; 86: 892–7.
32. Pommer A, Muhr G, David A. Hydroxyapatite-coated Schantz pins in external fixators for distraction osteogenesis: a randomised, controlled trial. *J Bone Joint Surg Am* 2002; 84: 1162–6.
33. Paley D. *Principles of Deformity Correction*. Berlin: Springer, 2001.
34. Frierson M, Ibrahim K, Boles M, Bote H, Ganey T. Distraction osteogenesis. A comparison of corticotomy techniques. *Clin Orthop* 1994; 301: 19–24.
35. McKee MD, Wild LM, Schemitsch EH, Waddell JP. The use of antibiotic impregnated, osteoconductive, bioabsorbable bone substitute in the treatment of infected long bone defects: Early results of a prospective trial. *J Orthop Trauma* 2002; 16: 622–7.
36. Aronson J. Experimental and clinical experience with distraction osteogenesis. *Cleft Palate Craniofac J* 1994; 31: 473–81.
37. Coglianesi DB, Herzenberg JE, Goulet JA. Physical therapy management of patients undergoing limb lengthening by distraction osteogenesis. *J Orthop Sports Phys Ther* 1993; 17: 124–32.
38. Velazquez RJ, Bell DF, Armstrong PF, Babyn P, Tibshirani R. Complications of use of the Ilizarov technique in the correction of limb deformities in children. *J Bone Joint Surg Am* 1993; 75: 1148–56.