



Keratomalacia - A Case Report

Authors

Deepthi Pullepu^{1*}, Deepthi Janga², V Murali Krishna³

*Corresponding Author

Deepthi Pullepu

Department of Ophthalmology, Rangaraya Medical College, Kakinada, Andhra Pradesh, India

Abstract

Xerophthalmia refers to an ocular condition of destructive dryness of conjunctiva and cornea caused due to severe vitamin A deficiency. Usually affects infants, children and women of reproductive age group. It is estimated to affect about one-third of children under the age of five around the world. Keratomalacia means dry and cloudy cornea which melts and perforates, caused due to severe vitamin A deficiency. Here we describe a case of 21 year old female with neurofibromatosis type 1 presenting with keratomalacia.

Keywords: Vitamin A deficiency, Xerophthalmia, Keratomalacia.

Introduction

Vitamin A is essential for the functioning of the immune system, healthy growth and development of body and is usually acquired through diet. Globally, 190 million children under five years of age are affected by vitamin A deficiency

They suffer from an increased risk of visual impairment, illness and death from childhood infections such as measles and those causing diarrhoea

XEROPHTHALMIA refers to the spectrum of ocular manifestations due to vitamin A deficiency. Such signs include night blindness, conjunctival xerosis, bitot spots, corneal xerosis and keratomalacia. They vary according to the severity of the deficiency and age. Though a rare condition in developed countries, frequently seen in poor countries.

It is estimated that approximately half of all childhood blindness in India is preventable or treatable, to which Vitamin A-associated corneal

blindness is a significant contributor

In India, it is estimated that there are approximately 6.8 million people who have vision less than 6/60 in at least one eye due to corneal diseases; of these, about a million have bilateral involvement.

Corneal blindness resulting due to this disease can be completely prevented by institution of effective preventive or prophylactic measures at the community level.

In this case report, we present the history, clinical features and post treatment response of 21 year old female with keratomalacia who is a known case of neurofibromatosis type 1.

Case Report

A 21 year old female came with the chief complaints of blurred vision both eyes more in the left eye and foreign body sensation since 2 months. Defective vision of both eyes is insidious in onset gradually progressive of duration 2 months with

greater fall in the left eye since 2 weeks. It is associated with pain, watering and photophobia of left eye since 2 weeks. H/o defective night vision present

No h/o redness, eye discharge. No h/o any topical medication usage. No h/o joint pains or backache or dryness of mouth and nasal cavity. She underwent cholecystectomy four months back with weight loss following it. Since then having diarrhoea 3-5 episodes per day following meal.

Poorly built and illnourished with multiple neurofibromas over face and body and cafe au lait spots over body .Vitals are stable. CVS, CNS and

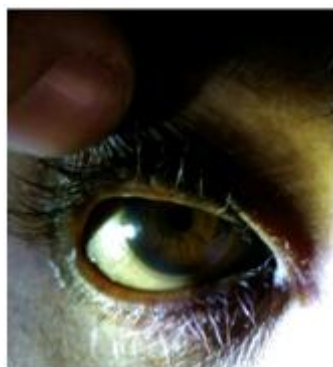Respiratory systems are normal. Abdomen is soft without any organomegaly with a scar in left hypochondrium

Different investigations were done. CBC, ESR, RBS were normal. Screening for retrovirus was done and was negative. Liver and kidney function tests were done and were normal.

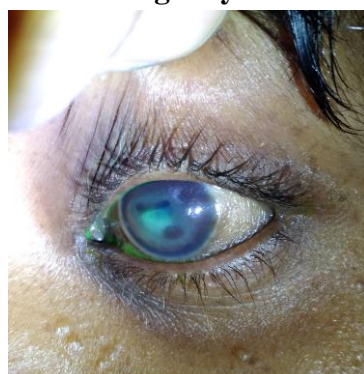
Due to unavailability of lab facilities for serum retinol levels and conjunctival impression cytology was not done.

After thorough history and investigations she was diagnosed as keratomalacia X3A left eye and X2 right eye secondary to vitamin A deficiency.

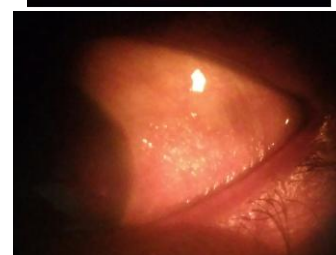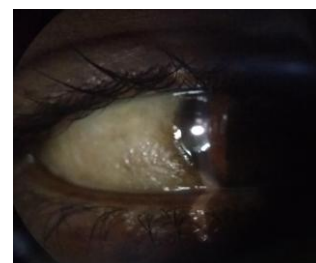	OD	OS
UCVA	6/12	CF CF
PH vision	6/6	No improvement
LIDS AND ADNEXA	Matting of lashes with poor tear meniscus	Matting of lashes with poor tear meniscus
CONJUNCTIVA	Dry and wrinkled (xerosis) with bitot spots temporally. No congestion	Dry and wrinkled (xerosis) with bitot spots temporally. No congestion
CORNEA	Dry, dull, lusterless, clear	Dry ,dull, lustreless, melting of less than 1/3 cornea present
ANTERIOR CHAMBER	Deep and quiet	Deep and quiet
IRIS	Lisch nodules are present	Lisch nodules are present
LENS	Clear	clear
FUNDUS	Normal	Details cannot be seen



Right eye



Left eye



Discussion

The patient was diagnosed as keratomalacia X3A left eye and xerophthalmia X2 right eye as per WHO classification which is as follows

XN- Night blindness

X1A- Conjunctival xerosis

X1B- Bitot spots

X2- Corneal xerosis

X3A- Corneal ulceration / keratomalacia, involving less than one-third of the cornea

X3B- Corneal ulceration / keratomalacia, involving more than one-third of the cornea

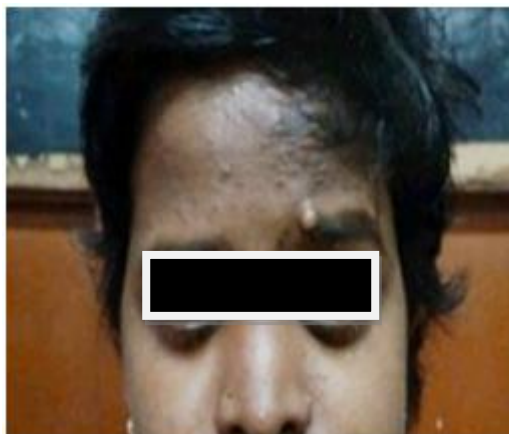XS- Corneal scar due to xerophthalmia

XF- Xerophthalmic fundus

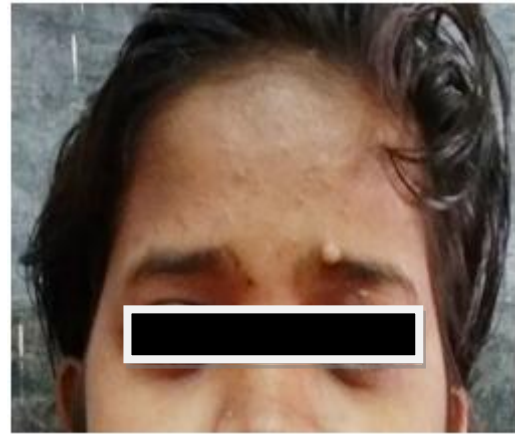Due to vitamin A deficiency post cholecystectomy followed by diarrhoea. This lead to malabsorption. Also she is associated with poor nutritional history attributed to her poor economic status. As the patient looks malnourished in appearance with a clear history of defective vision following surgery, cause of vitamin A deficiency can be explained.

She was treated with oral supplements of vitamin A (5000u/ day) for four weeks and dietary advice. She was also given preservative free lubricating eye drops and prophylactic antibiotic eye drops. She was also advised for physician checkup.

On further follow ups, her visual acuity improved to 6/9 left eye and 6/6 right eye.



At presentation



Post treatment

Conclusion

As keratomalacia comes under preventable and treatable cause of blindness, health education and other preventive measures have to be implemented.

Awareness of this condition is recommended to recognize this disease at the earliest and timely manage to prevent the patient from losing their vision.

References

1. WHO global database on vitamin A deficiency. Global prevalence of vitamin A deficiency in populations at risk 1995-2005. World Health Organization; 2009.
2. Gombos G M, Hornblase A, Vendeland J. Ocular manifestations of vitamin A deficiency. *Ann Ophthalmol.* 1970;2:680.
3. dube, D. G. C. (2018). A study on the prevalence of corneal blindness: A demographic correlates. *International Journal of Medical Science and Clinical Invention*, 5(7), 3925-3927.