



## Bilateral pneumothorax, pneumomediastinum and subcutaneous emphysema following functional endoscopic sinus surgery under general anaesthesia - A case report

Authors

Aswani B<sup>1</sup>, Anand S<sup>2</sup>, Amarnath Moni<sup>3</sup>, Lailu Mathews<sup>4</sup>

<sup>1</sup>Post Graduate Student, <sup>2</sup>Professor, <sup>3</sup>Associate Professor, <sup>4</sup>Professor & HOD,  
Department of Anaesthesiology, Chettinad Hospital & Research Institute, Chennai, India

### Abstract

*Negative pressure pulmonary edema (NPPE) is defined as fluid transudation into the pulmonary interstitium which occurs as a result of elevated negative intrathoracic pressure caused by the upper respiratory tract obstruction and strong inspiratory effort. NPPE is usually seen during emergence from general anesthesia in the early post-operative period. The occurrences of pneumothorax and pneumomediastinum are rare, but considered to be potentially life-threatening in patients undergoing functional endoscopic sinus surgery under general anesthesia. The early detection and treatment is vital to patient outcome. We report the case of a 25-year old male who developed massive bilateral pneumothorax and pneumomediastinum after functional endoscopic sinus surgery under general anesthesia.*

**Keywords:** *Pneumomediastinum, Pneumothorax, Negative pressure pulmonary edema, Endoscopic sinus surgery.*

### Introduction

Functional endoscopic sinus surgery (FESS) is a routine otolaryngology procedure with a success rate of about 90% for symptomatic improvement in patients with chronic rhinosinusitis.<sup>[1]</sup> Negative pressure pulmonary edema (NPPE) is a well described cause of acute respiratory failure that occurs after intense inspiratory effort against an obstructed airway, usually from upper airway infection, tumor, or laryngospasm.<sup>[2]</sup> The occurrences of pneumothorax and pneumomediastinum are rare, but considered to be potentially life-threatening conditions in patients undergoing functional endoscopic sinus surgery under general anesthesia. In our case, this unusual occurrence of pneumomediastinum after FESS may have led to major complications. This article discusses the incidence, diagnosis and evaluation

of complications of pneumothorax.

### Case Report

A 25-year-old male patient with BMI of 34.5 was planned for functional endoscopic sinus surgery and septoplasty for a diagnosis of chronic sinusitis and nasal septal deviation. The patient presented with complaints of frequent nasal discharge for 7 years which was aggravated for past 1 month. There was no history of comorbidities except for occasional smoker. History of snoring was present.

Airway examination showed Mallampati class II, mouth opening of more than 3 cm, thyromental distance of 7cm, and full range of neck movements. Pre-operative investigations were normal. Patient was adequately premedicated and shifted to operating room on the day of surgery.

Standard monitoring such as heart rate, non invasive blood pressure, oxygen saturation were recorded.

Inj.Glycopyrrolate 0.2 mg IV, Inj.Midazolam 1mg IV, Inj.Fentanyl 150mcg and Inj. Clonidine 25mcg given as premedication, and preoxygenated with 100% oxygen before induction of anesthesia. Inj. Propofol 180mg IV was given slowly and Inj. Atracurium 50mg IV injected after confirming the ability to ventilate the lungs. Oral intubation with an 8.0 mm I.D flexometallic endotracheal tube achieved. Position of endotracheal tube was confirmed by bilateral equal air entry equal with end tidal carbondioxide 35 mmHg. Cuff pressure monitor was used to set ETT cuff pressures at less than 25 mm Hg. Volume control mode of ventilation with tidal volume of 550ml, respiratory rate of 14/min, I:E ratio 1:2 maintaining airway pressures 19 – 20 cm H<sub>2</sub>O was started. Throat packing was done to prevent any trickling of blood into the trachea. Anesthesia was maintained with 50% O<sub>2</sub> at 4 L/min, 50% N<sub>2</sub>O at 4 L/min, and Isoflurane MAC 1.0. The patient was stable intraoperatively with heart rate maintained between 70-80bpm and blood pressure 130/80 mm Hg and Etco<sub>2</sub> of 28 mm Hg. The duration of the surgery was 4 hours. After completion of the surgery, the nasal cavity was packed, throat pack removed & blood and secretions suctioned out.

After spontaneous respiratory attempts were observed, Inj.neostigmine 3.0mg IV and Inj.glycopyrrolate 0.5 mg IV were given to reverse the neuromuscular blockade. When spontaneous respiration was sufficient enough for extubation, suddenly the patient bit the endotracheal tube and was aggressive. However the trachea was extubated and the patient was conscious with respiratory efforts. Post-extubation, the patient had airway obstruction with difficulty in breathing and desaturated (spO<sub>2</sub> 80%). Vitals became stable with spO<sub>2</sub> of 100% after performing bag and mask ventilation and shifted to recovery room with the patient in awake condition. Patient was provided with oxygen through simple oxygen face mask at

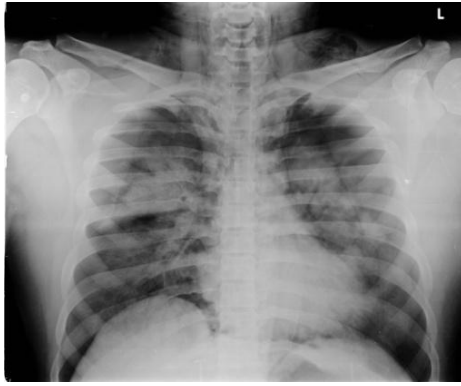6L/min. An hour after surgery, the patient started to feel dyspnoeic, sweating and started desaturating with spO<sub>2</sub> 80% with simple oxygen face mask. Arterial blood gas analysis showed respiratory acidosis. Continuous positive airway pressure (CPAP) was started with Pressure support (PS) 20mm Hg and Positive end expiratory pressure(PEEP) 7mmHg with inspired oxygen concentration ( FiO<sub>2</sub> ) 40%. CPAP was given for 2 hours intermittently with Non-Rebreathing oxygen mask (NRBM) of 15-30 minutes. After 12 hours of surgery, patient complained of chest pain and physical examination showed decreased breath sounds in right infrascapular and infraaxillary area compared to left side and crepitations bilaterally. Oxygen saturation of 98% was maintained with intermittent CPAP and NRBM.

Chest x-ray was done on post operative day 1 which revealed Negative pressure pulmonary edema with subcutaneous emphysema, pneumomediastinum and pneumothorax and High Resolution Computed Tomography chest was advised to confirm the findings. HRCT chest showed Massive Bilateral pneumothorax with concomitant consolidation, pneumomediastinum and subcutaneous emphysema in right supraclavicular area.

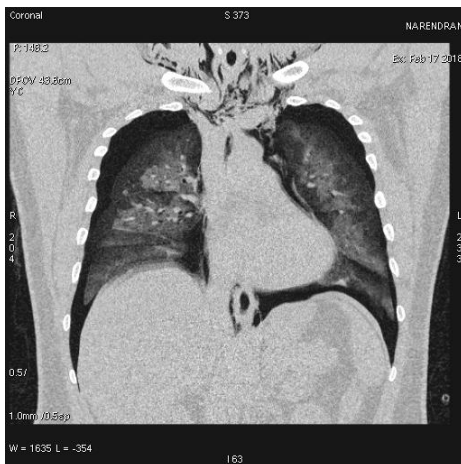
Clinically, the patient presented with chest pain, sweating and tachycardia.

On post-operative day 1, under Ultrasound guidance, Intercostal chest tube (ICD) was inserted on the right 6<sup>th</sup> intercostal space between mid-axillary line and mid-scapular line and air bubbles noted in the water trap.

Chest xray was taken after the procedure to confirm the position of ICD. Patient maintained oxygen saturation of 100% with simple oxygen face mask. Arterial blood gas analysis was normal. Treated with Broad spectrum antibiotics. On post operative day 2, he maintained room air oxygen saturation and discharged after ICD was removed on Post-operative day 7.



**Fig 1:** Chest x ray revealing subcutaneous emphysema and pneumothorax.



**Fig 2:** HRCT chest showing pneumomediastinum and pneumothorax.

## Discussion

In our case, post-extubation of endoscopic sinus surgery, there was upper airway obstruction treated by positive pressure ventilation and the cause of pneumomediastinum and pneumothorax is positive pressure ventilation induced barotrauma which was treated conservatively. Although history of smoking is present but the chances of emphysematous bullae is less since the symptoms were gradual and progressive. Tracheal rent is not a possibility because airway pressures were normal and intubation was done by experienced anesthesiologist. Next, there is the possibility of mucosal damage due to the movement of the endotracheal tube. In a study regarding the movement of the endotracheal tube, it is referred that the tube moves 1.5 cm towards the carina when flexing the neck, and moves 2.4 cm towards the vocal cords when the neck is extended. In our case, there were no excessive

position changes to the neck area during surgery, but in the process of regaining consciousness and spontaneous respiration, there were struggling before extubation. The tube could have moved during the neck bending and the position could have changed during this incident.

Mechanical ventilation can lead to barotrauma. Air leaks can be defined as any extrusion of air from normal gas-filled cavities including the upper airway, sinuses, tracheobronchial tree. Clinical conditions include pneumothorax, pneumomediastinum, pneumoperitoneum, and subcutaneous emphysema.

The term 'pneumothorax' was first coined by Itard and then Laennec in 1803 and 1819 respectively and refers to air in the pleural cavity (ie, interspersed between the lung and the chest wall). It is classified into spontaneous (primary or secondary) and traumatic (non iatrogenic and iatrogenic). Most pneumothoraces occurring during anaesthesia are due to pneumothorax secondary to barotrauma and traumatic pneumothorax as a result of thoracic injury during surgery.

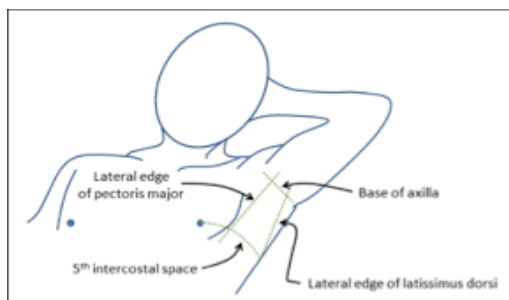
The primary cause of spontaneous pneumothorax are smokers and secondary causes are Chronic obstructive airway disease, Bullous lung disease, Cystic fibrosis and Asthma. The causes of Iatrogenic procedures are the transthoracic needle aspiration (24%), subclavian vessel puncture (22%), thoracocentesis (22%), pleural biopsy (8%) and mechanical ventilation (7%).

In patients receiving positive pressure ventilation, a pneumothorax is often caused by barotrauma in the presence of reduced lung compliance. The initial process in barotrauma is the production of perivascular interstitial emphysema. When the pressure gradient between the alveoli and the interstitium exceeds a critical level, alveoli rupture occurs and air enters into the interstitium.

In Chest X-ray in the upright position, the classical appearance is the presence of radiolucent air and the absence of lung markings between the shrunken lung and the parietal pleura. The volume of a pneumothorax approximates to the ratio of the cube of the lung diameter to the hemithorax

diameter; hence, a pneumothorax of 2 cm on a PA film would occupy 49% of the hemithorax volume. This is recommended as a guide to aid decisions on intervention by British Thoracic Society. Overall, CT chest is the gold standard for such imaging.

Simple aspiration is recommended as first-line treatment for all primary pneumothoraces requiring intervention. If simple aspiration of any pneumothorax is unsuccessful in controlling symptoms, an intercostal tube should be inserted. The most common position for chest tube insertion is in the mid-axillary line in right 5<sup>th</sup> intercostal space. The drain should not be removed until bubbling has ceased, and chest radiography demonstrates lung re-inflation. There is no evidence that clamping a chest drain at the time of its removal is beneficial.



The patient in our case received conservative treatment consisting of bed rest, oxygen therapy, use of antibiotics, and administration of analgesics together with prompt investigation of the cause after presenting symptoms.

Clinical symptoms of pneumomediastinum are usually chest pain with accompanying radiating pain from the neck, breathlessness, and throat discomfort. Physical findings include subcutaneous emphysema, the loss of cardiac dullness to percussion, and mediastinal crepitation (Hamman's sign).

In a simple chest x-ray, usually a line due to an air shadow can appear between the heart and diaphragm (continuous diaphragm sign), while in the lateral view of chest x-ray, there can be subcutaneous emphysema of the chest and neck, along the back of the sternum, around the outer pericardium of the right pulmonary artery (ring around the artery sign).

Treatment for pneumomediastinum is conservative treatment consisting of bed rest, a supply of oxygen, and use of antibiotics when the symptoms are not severe and the vital signs are satisfactory.

Subcutaneous emphysema is characterized by painless swelling of the tissues because of air tracking along tissue planes. Palpation elicits a characteristic tissue paper feeling beneath the fingers. Treatment is self resolving but it can be drained by skin incision with a needle if it produces distress to the patient. Radiologically, it is seen as translucent areas after the line of anatomical structures.

From the various cases and literature reviewed above, pneumothorax and pneumomediastinum developed is a case of positive pressure ventilation induced barotrauma post-operatively leaking a large amount of air through the damaged area in a short period of time.

### Conclusion

With prompt diagnosis and therapeutic action, early recognition and proper management of pneumothorax and pneumomediastinum is crucial to decrease the related complications.

### References

1. Mallar Bhattacharya; Richard H. Kallet, MS, RRT; Lorraine B. Ware, and Michael A. Matthay, 2016 Negative pressure pulmonary edema Md chest; 150(4): 927-933
2. Westreich R, Sampson I, Shaari CM, Lawson W. 2006 Negative -pressure pulmonary edema after routine septorhinoplasty. Arch Fac Plast Surg;8(8)-15.
3. Jung Man Park, Young-Chul Park, Jong Nam Lee, Jun Seok Bae, and Shin Kyu Kang 2013 Pneumomediastinum after functional endoscopic sinus surgery under general anaesthesia ; Korean J Anesthesiol 64(4):367-372
4. Andrew Mac Duff, Anthony Arnold, John Harvey, Management of spontaneous

- pneumothorax: British Thoracic Society pleural disease guideline Thorax 2010;65
5. S Sharma, A Jain. 2007 Negative- pressure pulmonary oedema after septoplasty. The Internet Journal of Anesthesiology. 17(1) – 1-4.
  6. Macklin CC. Transport of air along sheaths of pulmonic blood vessels from alveoli to mediastinum: clinical implications. Arch Intern Med (Chic) 1939; 64: 913-26.
  7. Jabourian Z, McKenna EL, Feldman M. Spontaneous pneumomediastinum and subcutaneous emphysema. J Otolaryngol 1988; 17: 50-3.
  8. Flint K, Al-Hillawi AH, Johnson NM. Conservative management of spontaneous pneumothorax. Lancet 1984
  9. Fremont RD, Kallet RH, Matthay MA, Ware LB. Post obstructive pulmonary edema- A case for hydrostatic mechanisms. Chest 2007;131:1742-6.
  10. Meinick BM. Post laryngospasm pulmonary edema in adults. Anesthesiology 1984 May; 60(5): 516-7.