

**Research Paper**

## A Prospective Study to determine the outcome and efficacy of Harmonic scalpel Hemorrhoidectomy

Authors

**Thakur D S<sup>1</sup>, Joshi H<sup>2\*</sup>, Somashekar U<sup>3</sup>, Kothari R<sup>4</sup>, Kumar V<sup>5</sup>, Sharma D<sup>6</sup>**

<sup>1</sup>Associate Professor, Department of Surgery, N.S.C.B. Medical College, Jabalpur

<sup>2</sup>Resident, Department of Surgery, N.S.C.B. Medical College, Jabalpur

<sup>3,4,5</sup>Associate Professor, Department of Surgery, N.S.C.B. Medical College, Jabalpur

<sup>6</sup>Professor and H.O.D., Department of Surgery, N.S.C.B Medical College, Jabalpur

\*Corresponding Author

**Joshi H**

Resident, Department of Surgery, N.S.C.B. Medical College, Jabalpur, MP, India

**Abstract**

**Aims and Objectives:** *The aim of the present work is to determine the outcome and efficacy of Harmonic scalpel hemorrhoidectomy (HSH) for grade III and IV hemorrhoids in terms of Operating time, Post operative pain, Post operative stay and Post operative complications.*

**Methods:** *Prospective study of 30 patient for grade III and IV hemorrhoids was done from October 2017 to 31st August 2019 at department of general surgery N.S.C.B Medical College and Hospital, Jabalpur. All surgeries done under saddle block. A follow up examination was conducted for minimum period of 3 months.*

**Results:** *Out of 30 patients 7 female and 23 male patients were treated with HSH. The mean age of patients were 46.17 years. The average operative time was 19.20±2.14min. VAS pain score on postoperative Day 1, Week 1, Week 3, Week 6 were 4.77±0.94, 2.83±0.75, 0.20±0.41 and 0. The average postoperative stay was 1.13 ±0.43 days. the incidence of post operative hemorrhage was low and 1 of 30 cases i.e. 3.3% and no recurrence or fecal incontinence, stenosis/stricture, and anal abscess was found after 3 months of follow up.*

**Conclusion:** *The present study shows that HSH is safe, effective, with less complication rate.*

**Introduction**

Hemorrhoids is common diseases of the rectum, with estimated worldwide prevalence ranges from 2.9% to 27.9%, of which more than 4% are symptomatic<sup>[1,2]</sup>.

Milligan Morgan hemorrhoidectomy or Ferguson's hemorrhoidectomy are considered a gold standard treatment for advanced hemorrhoids<sup>[3,4,5]</sup>. Post-op pain, bleeding, incontinence, stenosis are the complications which delays

discharge of patients and mobility. To overcome these complication newer methods and instrumentations has come upon. The harmonic scalpel (HS) cause less damage to tissue, better hemostasis thus reduced pain and bleeding in postoperative period<sup>[6]</sup>. HS use ultrasonic vibration to cut and seal tissues. This study shows our experience with harmonic scalpel for hemorrhoidectomy.

### Materials and Methods

The study was conducted between October 2017 to 31st August 2019 and involved 30 patients who underwent HSH for grade III/IV and were followed up for 3 months. Patients with Liver cirrhosis, Pregnancy and Uncontrolled diabetes were excluded from study. We measured operating time, postoperative pain, length of hospital stay, urinary retention, incontinence to flatus and faeces, anal abscess, recurrence were evaluated. All surgeries were done under saddle block. Patients were placed in the lithotomy position and painting draping was done. Hemorrhoids were held with artery forceps and excision of hemorrhoid pedicle to the apex was done without damaging the internal sphincter with the help of using **Harmonic Focus®** Curved Shears Probe (Johnson & Johnson). Mucosal suture were placed with Vicryl 2-0 after removal of haemorrhoidal tissue. Anal canal was inspected for any bleeding and the wound was closed primarily with Vicryl 2-0 sutures.

Total analgesic (Tab. Diclofenac 50 mg/days) needs of the patients were recorded after 1 day, 7 days, 3 weeks, 6 weeks and 3 month. Pain was recorded on a visual analogue scale (VAS) on the same days.

Operation time was defined as the time between the incision and suturing. Patients were assessed for early and late complication when they came back for follow up.

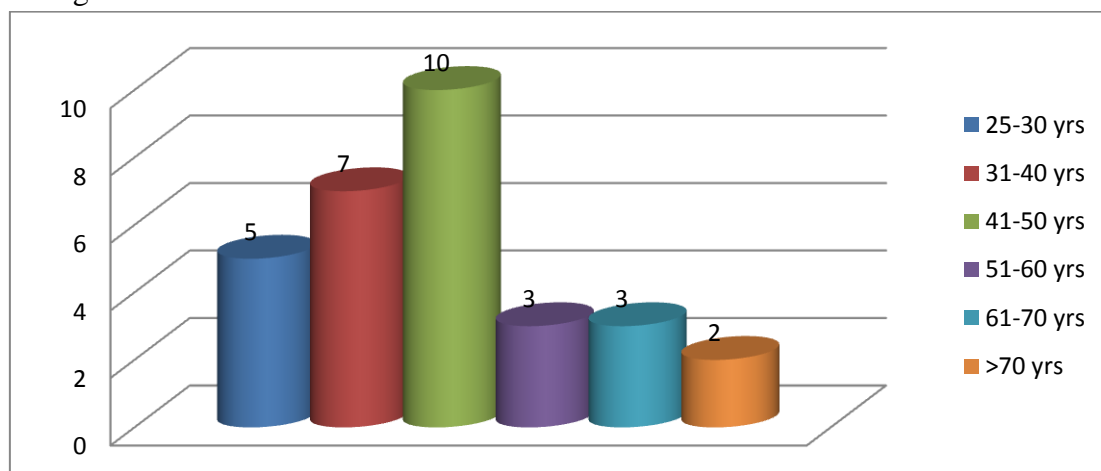
### Results

Out of the 30 patients 23 were male (76.7 %) and 7 were female (23 %). In our study group patients with grade 3 comprised up to 63% and those of grade 4 were 36.7%. So in majority of patients prolapsed was an important factor seeking for treatment.

**Table -1** Demographic of the patients

Variables	Frequency	Percent
Sex		
Female	7	23.3
Male	23	76.7
Grade		
Grade-3	19	63.3
Grade-4	11	39.7

**Graph No. 1** Age Wise Distribution of Cases



The average postoperative stay in our study group was  $1.13 \pm 0.43$  days. Maximum stay of 3 days present in 1 patient. The mean operative time in our study group was  $19.20 \pm 2.14$  minutes. The VAS pain score on postoperative Day 1, Week 1,

Week 3, Week 6 were  $4.77 \pm 0.94$ ,  $2.83 \pm 0.75$ ,  $0.20 \pm 0.41$  and 0. Pain was higher in first 24 hours and then decreased gradually. Pain was more on first postoperative day and then gradually decreased.

**Table -2** Outcomes of Harmonic Scalpel Hemorrhoidectomy

Variable	Mean	Std. Dev.	Min	Max
Age (year)	46.17	14.47	25	85
Operative time	19.2	2.14	16	24
Hospital-stay	1.13	0.43	1	3
Earlypost operative VAS	4.77	0.94	3	7
Painweek1	2.83	0.75	2	4
Painweek3	0.2	0.41	0	1
Painweek6	0	0	0	0
Painmonth3	0	0	0	0

In postoperative period incidence of acute urinary retention after surgery is 20% (6/30).

3.3% (1/30) of patients had post operative hemorrhage which got resolved on conservative treatment.

**Table-3** Post op Period

Complications	Frequency	Percent
Urinary retention	6	20
Haemorrhage	1	3.3

There were no complication of incontinence flatus/fecal and recurrence of disease after 3 months of follow up. There were no case of postoperative prolapsed; anal stricture or stenosis and anal abscess.

### Discussion

Hemorrhoidectomy is accepted as the gold standard for surgical treatment of hemorrhoids worldwide.<sup>[7]</sup> Conventional hemorrhoidectomy for Grade III and Grade IV hemorrhoids is associated with significant morbidity and a prolonged convalescence.<sup>[7]</sup> The Harmonic Scalpel (HS) has advantage over other energy device as it causes very little lateral thermal injury in the tissues. A decreased lateral thermal injury results in less postoperative pain.<sup>[8,9]</sup>

HS causes minimal intraoperative bleeding, which allows better exposure and has an operative time less than surgery with other techniques. In the current study the mean operative time required for HSH is 19.20±2.14 minutes. Harmonic scalpel causes minimal lateral damages (1-3mm) and causes minimal mucosal damage leading to faster wound healing less post op morbidity and minimal pain. Current study showed that the VAS pain score on postoperative Day 1, Week 1, Week 3,

Week 6 were 4.77±0.94, 2.83±0.75, 0.20±0.41 and 0. Study done by Bulus H et al, VAS score for post operative pain on day 1, 1st week and on 4th week was 5.4±0.7, 4±0.8 and 0.01±0.1 respectively<sup>[12]</sup>. Similarly in study of Dae Ro et.al they found that the postoperative resting pain scores were 5.4±0.7 on post operative day (POD), 4.8 ± 1.4 on postoperative day 3 (POD 3) and 0.8 ± 0.8 on POD 14<sup>[11]</sup> which was comparable.

The average postoperative stay in our study group was 1.13 ±0.43 days. While it was 1.46±0.8 days in the study done by Amrithraj Thiyagarajan & Shubhi Bhatnagar<sup>[13]</sup> and we found that in early postoperative period (within 7 days of surgery) incidence of acute urinary retention after surgery is 6/30 i.e. 20%.

The current study showed the incidence of post operative hemorrhage was low and 1 of 30 cases i.e. 3.3% which got resolved on conservative treatment and there were no anal abscess, incontinence or anal stenosis, stricture over 3 months of follow up period.

The present study shows that HSH is safe, effective, with decreased complication rate. The major drawback with Harmonic Scalpel hemorrhoidectomy compare to conventional hemorrhoidectomy is higher cost. The long-term results and recurrence rate should be evaluated in larger prospective studies.

### Conclusion

Present study conclude that harmonic scalpel it is safe, effective and easy without serious complications. It also allows earlier return to work, good patient satisfaction, decrease pain, incontinence to flatus and feces. Thus a

hemorrhoidectomy performed using an ultrasonic scalpel is recommended as an alternative approach to existing conventional hemorrhoidectomy techniques but larger studies with large number of patients are required to validate the result of this study.

### Bibliography

1. Johnson JF, Sonnenberg A. The prevalence of hemorrhoids and chronic constipation: an epidemiological study. *Gastroenterology*. 1990; 98(2): 380-386.
2. Rogozina VA. Hemorrhoids Eksperimental' Naia i Klinicheskaia Gastroenterologiya. 2002; 4: 93-96.
3. MacRae HM, McLeod RS. Comparison of Hemorrhoidal Treatment Modalities. A meta-analysis. *Dis Colon Rectum*. 1995; 38(7): 687-694.
4. Longo A. Treatment of haemorrhoidal disease by reduction of mucosa and haemorrhoidal prolapse with a circular stapling device: a new procedure.
5. Thompson WH. The nature of hemorrhoids. *Br J Surg* 1975;62:542-52.
6. Sayfan J, Becker A, Koltun L. Sutureless closed hemorrhoidectomy: a new technique. *Ann Surg*. 2001;234:21e24.
7. Prospective, randomized trial comparing pain and clinical function after conventional scissors excision/ligation vs. diathermy excision without ligation for symptomatic prolapsed hemorrhoids. Seow-Choen F, Ho YH, Ang HG, Goh HS. *Dis Colon Rectum*. 1992 Dec; 35(12):1165-9.
8. *Tech Coloproctol*. 2002 Sep;6(2):89-92
9. *International Surgery Journal Thiyagarajan A et al. Int Surg J*. 2017 Sep;4(9):3007-3014.
10. *Ann Coloproctol*. 2016 Jun; 32(3): 111-116.
11. Milito G, Cadeddu F. Tips and tricks: haemorrhoidectomy with Liga Sure. *Tech Coloproctol*. 2009;13(4):317-20
12. Bulus H, Tas A, Coskun A, Kucukazman M. Evaluation of two hemorrhoidectomy techniques: harmonic scalpel and Ferguson's with electrocautery. *Asian J Surg*. 2014;37:20-23.
13. *Asian journal of surgery* (2014)37 ,20-23.