



## A Case Report on Tuberos Sclerosis with Associated Ectropion Uvea

Author

**Raktima Baksi (Mandal)<sup>1</sup>**

<sup>1</sup>RMO-CT (Tutor), Dept. of Ophthalmology, Rampurhat Government Medical College, Birbhum

\*Corresponding Author

**Raktima Baksi (Mandal)**

RMO-CT (Tutor), Dept. of Ophthalmology, Rampurhat Government Medical College, Birbhum

### Abstract

*Phakomatosis syndrome are defined as a group of multisystem syndromes that have characteristic ophthalmic manifestations. They have familial incidence and congenital basis, having varied ocular profile of presentation, with some of them having serious ocular morbidity. Key features include retinal and uveal lesions. The common factor joining this group of disorder are presence of neurological, ophthalmological and cutaneous manifestations. All patients diagnosed with phakomatosis should be referred for neurocutaneous consultation, spinal cord imaging, neuroimaging and Electroencephalogram. Most of the cases are reported from far East countries especially Japan, Mexico or Argentina. On the first week of February 2015 a male patient aged 15years, residing in Kishanganj district, Bihar came to visit our Ophthalmology OPD of M.G.M Medical College and Hospital, Kishanganj, Bihar with no vision since birth in both eyes. It was a rare case because he had adenoma sebaceum in his face. He was of low intelligence with no history of epilepsy. On slit lamp examination we found that he had ectropion uvea, microphthalmos, horizontal nystagmus and congenital cataract in his left eye and Phthisis bulbi, congenital cataract with horizontal nystagmus in his right eye*

**Keywords:** *Phakomatosis, adenoma sebaceum, ectropion uvea, microphthalmos, nystagmus, phthisis bulbi.*

### Introduction

The Phakomatosis (mother spot disease) comprise a group of diseases with a familial incidence and a congenital basis, having various ocular presentations, with some of them having serious ocular morbidity. They include Neurofibromatosis type 1 (Von Recklinghausen's disease) and type 2 (Central Neurofibromatosis), Tuberos Sclerosis, Ataxia telangiectasia, Sturge Weber syndrome, von-Hippel Lindau's disease, Weber-Mason Syndrome, Klippel-Trenaunay-Weber Syndrome, Naevus of Ota. All other

phakomatosis, except ataxia telangiectasia, demonstrate an autosomal dominant inheritance pattern.

The classical phakomatosis, was first described by von Recklinghausen and Bourneville's coined the term '*sclerose tuber*' for this condition. The clinical features of the disease complex comprises of epilepsy, low intelligence and adenoma sebaceum, therefore this condition has also been termed as *epiloia*. The term commonly used now-a-days is Tuberos Sclerosis Complex (TSC). Tuberos sclerosis complex (TSC) is a multisystemic

neurocutaneous genetic condition with autosomal dominant inheritance, characterized by hamartomas that affect multiple organs, including skin, central nervous system, heart, lungs, and kidney. It is also known as epiloia or Pringle-Bourneville phacomatosis, and was initially described in the 19th century by Virchow and Von Recklinghausen, who identified hamartomas in the brain and heart during the necropsy of patients with seizures and mental retardation. However, the correlation between the cutaneous manifestations with other clinical symptoms and the description of the syndrome were made by Bourneville in the beginning of the 20th century. Years after, Campbell in 1905 and Vogt three years later established the triad that characterizes TSC, which is mental retardation, epilepsy and Pringle type of sebaceous adenoma (angiofibroma).<sup>[1,2]</sup> Diagnostic criteria for tuberous sclerosis were firstly established in 1998.<sup>[3]</sup> In 2012, in the second International Tuberous Sclerosis Complex Consensus Conference held in Washington, these criteria were reviewed with the aim of presenting recommendations for the diagnosis, surveillance and management of TSC patients.<sup>[3]</sup> The condition affects one in every 6,000 to 10,000 individuals and can affect both sexes and all ethnic groups equally. It has a great phenotypical variability, which can sometimes make its recognition difficult.<sup>[4,5]</sup> Statistically there is approximately 1 case per 10,000 people in the general population group. Phacomatosis comprise of congenital hamartomatous malformations affecting the CNS, the skin and the eye and the phenotypic variations of these presentations are high. The common factor joining these groups of disorder are presence of neurological, ophthalmological and cutaneous manifestations. These syndromes are also known as *neurocutaneous syndromes*. All patients diagnosed with phacomatosis should be referred for neurological consultation, spinal cord imaging, neuroimaging and EEG. But some of the conditions like von-Hippel Lindau's syndrome and tuberous sclerosis may also require an abdominal CT Scan.

TSC occurs due to the deletion, rearrangement and inactivating mutation of tumor suppressor genes TSC1 or TSC2, that lead to abnormal proteins hamartin and tuberin, codified in the loci 9p34 and 16p13, respectively.<sup>[4,6]</sup> The role of these genes consists in the regulation of cellular growth through the phosphatidylinositol 3-kinase signaling pathway, inhibiting the mammalian target of rapamycin (mTOR).<sup>[7]</sup> The complex hamartin/tuberin is an important inhibitor of tumor growth. These proteins suppress the activity of the mTOR pathway, responsible for cellular proliferation and inhibition of cellular apoptosis. In TSC patients, changes in these proteins lead to a permanent activation of the mTOR pathway, and therefore to the formation of hamartomas in multiple organs. Familial cases of the condition are due to germline mutations and, despite being able to be transmitted hereditarily, 70% of TSC patients are the result of somatic mutations, configuring sporadic cases.<sup>[1]</sup> Studies demonstrate that changes in the TSC2 gene are more common and lead to a more severe neurological impairment when compared to TSC due to mutations in TSC1.<sup>[5,8,9]</sup> Cases of familial transmission result in mild to moderate disease, sometimes not fulfilling all diagnostic criteria and have a higher frequency of changes in the TSC1 gene.

### Clinical Manifestations

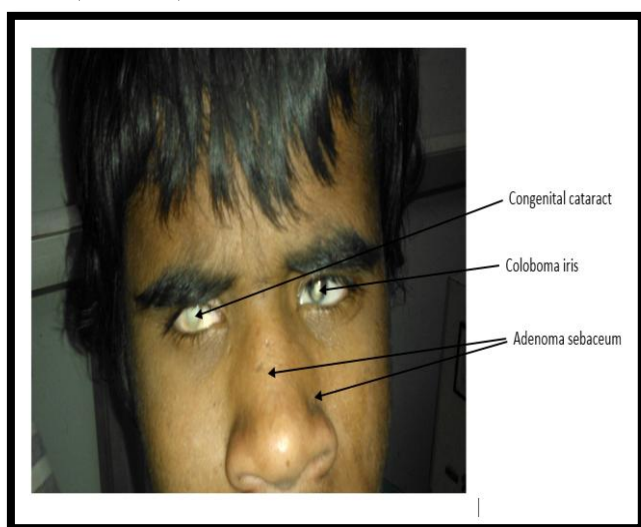
Most patients affected by TSC seek medical attention due to seizures or skin lesions.<sup>[10]</sup> TSC is a condition with variable expression and complete penetrance. Both sexes are equally affected but women can have more marked signs.<sup>[1]</sup> Cutaneous manifestations represent the most common findings observed in TSC patients, even though there are some affected individuals with no cutaneous involvement. Neurological and renal complications are the main cause of morbidity and mortality associated to the condition.

### Case Report

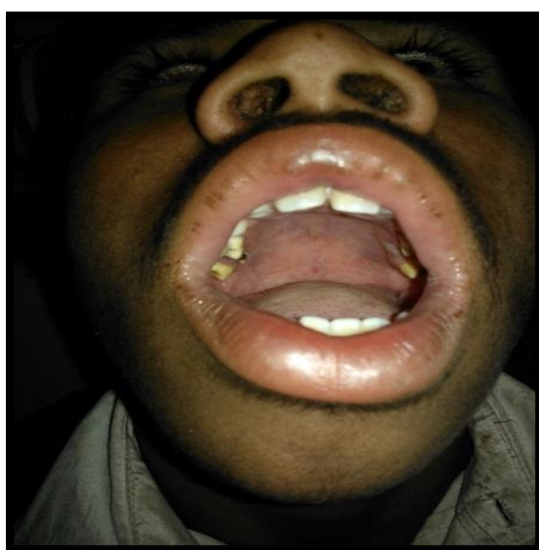A 15 years old boy from Kishanganj district (Bihar) was referred to the Ophthalmology OPD in

February 2015 at M.G.M Medical College and Hospital, Kishanganj, Bihar with chief complains consisting of no vision in both eyes since birth, with yellow brown rubbery papules in the face arranged in a butterfly fashion.

The child was assessed by an ophthalmologist and was found to have microphthalmos, microcornea, ectropion uvea, congenital cataract and horizontal nystagmus in his left eye and phthisis bulbi and congenital cataract with horizontal nystagmus in his right eye. His anterior segment examination was done. (Table 1)



**Figure 1:** Shows ectropion Uvea, Microphthalmos, Microcornea, Horizontal Nystagmus and Congenital Cataract in his Left Eye and Phthisis Bulbi, Congenital Cataract with Horizontal Nystagmus in His Right Eye



**Figure 2** Showing Gingival Adenoma in the Same Patient with Tuberous Sclerosis

**Table 1:** Anterior Segment Examination

	RIGHT EYE	LEFT EYE
Vision unaided	PL denied	PL denied
Lid	Normal	Normal
Conjunctiva	Phthisis bulbi	Clear
Cornea	Cannot be evaluated	Microcornea
Anterior chamber	Cannot be evaluated	Ectropion uvea
Iris	Cannot be evaluated	Ectropion uvea
Pupil	Cannot be evaluated	Ectropion uvea
Lens	Congenital cataract	Congenital cataract
Extraocular muscles and movements	Full and painless	Full and painless
	Horizontal nystagmus	Microphthalmos
		Horizontal nystagmus

**Posterior Segment Examination**

Following instillation of tropicamide and phenylephrine combination eye drop in both the eyes, they were examined after one hour which showed no dilation. Fundus could not be visualised due to opaque media as a result of congenital cataract. Vision did not improve with refraction.

**Other Systemic Examinations**

- CNS- The patient was found to be mentally retarded.
- Skin-Adenoma sebaceum present (yellow brown rubbery papules in a butterfly distribution over the face).
- CVS-S1 and S2 heart sounds were audible.
- Renal System- No abnormality detected.

**Differential Diagnosis**

- 1) Neurofibromatosis 1 and Neurofibromatosis 2
- 2) Tuberous Sclerosis
- 3) Sturge Weber Syndrome
- 4) Ataxia telangiectasia
- 5) von Hippel Lindau's syndrome
- 6) Wyber Mason Syndrome
- 7) Klippel Trenaunay Weber Syndrome
- 8) Naevus of Ota

**Discussion**

Tuberous Sclerosis is an autosomal dominant condition with incomplete penetrance, with the genes mapped to chromosome 9q34 (TSC1) and 16p31 (TSC2). There is very high percentage of

mutation in the causation of this condition and there is no gender or racial predilection. Mortality rate is high.

The average age of presentation with the classical features is between two and eight years of age. Skin lesions develop in about 90 percent of the patients. The ash leaf macule, shagreen patch, facial angiofibroma and ungula fibromas are characteristic of this condition. The revised criteria for the TSC are divided into major and minor criteria is shown in Table 2 and the criteria for diagnosing TSC is given in Table 3.

**Table 2:** Major and minor criteria for the diagnosis of TSC

Systems	Major Criteria	Minor Criteria
Dermatological signs	Facial angiofibroma, 3 or more hypomelanotic macules, ungual and periungual fibromas, shagreen patch,	Gingival fibroma. Confetti skin lesions
Central Nervous System signs	Cortical tubers, subependymal nodules, subependymal giant cell astrocytoma	Cerebral white matter radial migration lines
Ocular Criteria	Multiple retinal nodular astrocytoma	Retinal achromatic patch
Cardiac Criteria	Rhabdomyosarcoma single or multiple	
Renal	Renal angiomyolipoma	Multiple renal cysts
Others	Pulmonary lymphangiomatosis	Non renal hamartoma, multiple dental enamel pits, bony cysts, hamartomatous rectal polyps

**Table 3:** Criteria for Diagnosing TSC

Definitive TSC	Probable TSC	Possible TSC
Presence of 2 major criteria	Presence of 1 major criteria and 1 minor criteria	1 major criteria
Presence of 1 major and 2 minor criteria		2 or more minor criteria

Major and minor diagnostic criteria are characteristic of all phakomatosis because of extremely variable phenotypic presentations of the same. As most of them are autosomal dominant disorders, evaluation for the presence of minor criteria in close relatives of the patient is also of great significance in genetic counselling.

Tuberous Sclerosis is derived from potato like appearance of the tumours in the Cerebrum and other organs. Two types of hamartomas found in the retina are:

- 1) Flat and soft appearing white or grey lesions in the posterior pole.
- 2) Large nodular tumours having predilection for optic disc.

Other systemic associations are aneurysms of the aorta, polycystic kidney, recurrent pneumothorax due to rupture of subpleural cysts, cor pulmonale, hepatic hamartomas, renal cell carcinoma, bony sclerosis, diffuse cutaneous reticulohistiocytosis, guttate leukoderma, poliosis, café-au-lait macules and endocrinal abnormalities in the form of thyroid disorders, adrenal dysfunction, pituitary dysfunction including acromegaly.

**Management**

Complete blood count and electrolytes, electroencephalography, echocardiography, chest radiography were done. We did not perform cataract surgery in his left eye due to poor visual prognosis. Finally patient was referred to a higher centre for C.T Scan (calcified astrocytic hamartomas may be evident on CT) and abdominal C.T Scan, MRI of brain. Treatment included of genetic counselling of the patients thoroughly. Retinal astrocytoma usually do not require treatment. Annual ophthalmic examinations are necessary to manage any complications. Proper assessment of this mentally challenged prepubertal child in Paediatric OPD and neurological consultation were carried out for the treatment of Astrocytoma, with facial acne, high degree of suspicion of the disease. His parents and other close relatives were also evaluated as this condition, having incomplete penetrance may not manifest in its full clinical form in all. Complete general, physical and ophthalmic examinations of patients and family members in conjunction with an internist or paediatrician were done.

TSC treatment consists, above all, of the management of the symptoms caused by hamartomas and prophylactic measures to avoid loss of function of the affected organ. Because it is a systemic disease, a multidisciplinary follow-up is

mandatory, with the need of assessment and follow-up in conjunction with teams of genetics, neurology, ophthalmology, pneumology, nephrology, and odontology.<sup>[1]</sup> From the dermatological point of view, multiple descriptive or surgical treatments were developed to decrease the development and remove facial angiofibromas such as dermabrasion, surgical excision, electrocautery and laser. However, these procedures tend to be uncomfortable for the patient, need to be repeated periodically to avoid recurrence of the lesions and many times need to be associated to other therapeutic methods in an attempt to optimize the results.<sup>[1,11]</sup> For the treatment of facial angiofibromas with a predominantly vascular component, intense pulsed light (IPL) has been shown particularly effective. Fibrous or protruding lesions respond better to carbon dioxide laser resurfacing, although this treatment also presents a higher risk for hypertrophic scarring.<sup>[12]</sup> Due to the progressive enlargement and recurrence of facial tumors, surgical treatment can be postponed until after adolescence, when their growth is maximum. Painful unguis fibromas can be surgically excised, cauterized or treated with laser, however, recurrence is common.<sup>[1]</sup> In TSC patients, the mTOR protein is aberrantly activated in fibroblastlike cells located in the dermis. These cells produce an epidermal growth factor, epiregulin, that simulates cellular proliferation.<sup>[11,13]</sup> This overproduction of cells along with angiogenesis result in the initial appearance and continuous progression of facial angiofibromas throughout life. After the discovery of the regulation of the mTOR pathway in the development of TSC tumors and with the advent of the target therapy using mTORC1 inhibitors, some promising studies have been highlighted, favoring the possibility of treating TSC patients according to the physiopathogenesis of the condition. Rapamycin is a natural macrolide isolated from *Streptomyces hygroscopicus* in 1965, that binds specifically to mTOR, resulting in the inhibition of mTOR activity and finally promoting the inhibition of cellular growth.<sup>[11]</sup> Rapamycin mTOR inhibitors and their derivative everolimus have been studied in TSC

patients since 2006 and are promising for the treatment of multiple tumors including renal angiomyolipomas, giant cell subependymal astrocytomas and lymphangioliomyomatosis, with secondary benefits on the cutaneous manifestations.<sup>[14-16]</sup> Randomized, double-blind, placebo-controlled clinical trials, EXIST-1 (efficacy and safety of everolimus for subependymal giant cell astrocytomas – SEGAs - associated with tuberous sclerosis complex) and EXIST-2 (everolimus for angiomyolipoma associated with tuberous sclerosis complex or sporadic lymphangioliomyomatosis) demonstrated beneficial effects of everolimus in both TSC manifestations.<sup>[17,18]</sup> These studies allowed the approval of everolimus by the European Medicines Agency (EMA) and by the Food and Drug Administration (FDA) for the treatment of adult patients with renal angiomyolipoma associated to TSC and with risk of complications (based on the size of the tumor, the presence of aneurysm and of multiple or bilateral tumors) that did not need immediate surgery. Everolimus is also indicated for the treatment of patients with SEGAs regardless of age, who require therapeutic intervention but are not eligible for surgery.<sup>[29]</sup> Either rapamycin or everolimus proved to reduce the severity of epilepsy in TSC patients.<sup>[15,20]</sup> In Brazil, these drugs are approved by the Agência Nacional de Vigilância Sanitária (ANVISA) in patients with TSC with the following indications/ everolimus for renal angiomyolipomas without indication of immediate surgery (in patients over 18 years) and SEGAs; and sirolimus for lymphangioliomyomatosis.<sup>[21,22]</sup> In regards to the cutaneous effects of mTOR inhibitors, in a retrospective study that evaluated the response to sirolimus in 14 patients with lymphangioliomyomatosis, they were also submitted to serial photographic documentation of the facial angiofibromas before, during and after the treatment, associated to microscopic and molecular studies of these lesions before and during the administration of sirolimus. The study revealed that cutaneous tumors not only improved after treatment with systemic sirolimus but also maintained the

improvement for at least 64 months of treatment.<sup>[21]</sup>

In a similar way to other studies that also evaluated the secondary cutaneous response to systemic sirolimus indicated for renal tumors, facial angiofibromas responded more favorably to the treatment than ungual fibromas and shagreen patches. Therefore, it is possible that the antiangiogenic properties of sirolimus are responsible for the apparent superior benefit in highly vascularized cutaneous tumors.

Unexpectedly, angiofibromas did not worsen after discontinuation of the treatment in this study. This is contrary to the progression of cutaneous and visceral tumors reported in previous studies after ceasing systemic therapy.<sup>[21,22]</sup> Current guidelines limit the use of oral mTORC1 inhibitors for the treatment of TSC cutaneous lesions for individuals that are not eligible to surgical approaches and whose skin lesions have a severe risk of recurrent and extensive hemorrhages.<sup>[5]</sup> However, the oral treatment with mTOR inhibitors is associated to an increased risk of infections, stomatitis being the most frequent, acne, amenorrhea and laboratory abnormalities. Considerations of these effects are important, since treatment with mTOR inhibitors should be long lasting because withdrawal of the medication results in a rebound growth of the tumor (SEGA, renal angiomyolipoma, cardiac rhabdomyoma and cutaneous lesions) in the majority of the patients.<sup>[23]</sup> A small series of cases reported benefits using topical preparations of rapamycin in facial angiofibromas, leading to the reduction in size and in the erythema and, in some cases, to the complete resolution of the cutaneous lesions. However, the long-term safety evidence is still scarce.<sup>[5]</sup> Early mTOR inhibition can prevent the development of facial angiofibromas, as suggested by a case report in a female monozygotic twin treated with systemic everolimus for SEGA since she was four years of age. Her twin sister who was not treated developed facial angiofibromas when she was six years of age, while the patient treated did not.<sup>[24]</sup> At last, it is known that many dermatological diseases cause a negative impact in the life of patients, due to stigmas caused by the

appearance of cutaneous lesions. This not only affects their emotional state, but also their social relations and daily activities. In TSC patients, we observe this impact, so it is fundamental that the medical team that follows these patients to consider not only the clinical aspects of the disease, but also the psychologic and social morbidities inherent to this condition.<sup>[25,26]</sup> In case of congenital cataracts with unilateral dense cataract merits more urgent surgery; there is no consensus regarding timing except that 6 weeks is the latest point at which elective surgery should be performed. Many authorities would advocate surgeries between 4 and 6 weeks, followed by aggressive anti-amblyopia therapy, despite which results are disappointing. If the cataract is detected after 16 weeks of age then the visual prognosis is particularly poor. Surgery involves anterior capsulorhexis, aspiration of lens matter, capsulorhexis of posterior capsule, limited anterior vitrectomy and IOL implantation, if appropriate. It is important to correct associated refractive error

### Conclusion

Management of phakomatosis cases comprises of proper assessment of mentally challenged prepubertal child in Paediatric OPD and neurological consultation is also required in cases with history of seizure disorder, who presents with facial acne, high degree of suspicion of the disease. Evaluation of the parents and other close relatives is very important as this condition, having incomplete penetrance may not manifest in its full clinical form in all. Complete general, physical and ophthalmic examinations of patients and family members in conjunction with an internist or paediatrician is mandatory.

Complete blood count and electrolytes. CT or MRI of the brain (calcified astrocytic hamartomas is evident on CT). Electroencephalography, echocardiography, chest radiography and abdominal C.T scan.

Treatment includes genetic counselling of the patients thoroughly. Retinal astrocytoma usually

need no treatment. Annual ophthalmic examinations are necessary to manage any complications.

## References

- Rodrigues DA, Gomes CM, Costa IMC. Tuberous sclerosis complex. *An Bras Dermatol*. 2012;87:184–196.
- Hinton RB, Prakash A, Romp RL, Krueger DA, Knilans TK, International Tuberous Sclerosis Consensus Group Cardiovascular manifestations of tuberous sclerosis complex and summary of the revised diagnostic criteria and surveillance and management recommendations from the International Tuberous Sclerosis Consensus Group. *J Am Heart Assoc*. 2014;3:e001493.
- Northrup H, Krueger DA, International Tuberous Sclerosis Complex Consensus Group Tuberous sclerosis complex diagnostic criteria update: recommendations of the 2012 International Tuberous Sclerosis Complex Consensus Conference. *Pediatr Neurol*. 2013 Oct;49(4):243–254.
- Sadowski K, Kotulska K, Schwartz RA, Józwiak S. Systemic effects of treatment with mTOR inhibitors in tuberous sclerosis complex: a comprehensive review. *J Eur Acad Dermatol Venereol*. 2016;30:586–594.
- DiMario Jr FJ, Sahin M, Ebrahimi-Fakhari D. Tuberous Sclerosis Complex. *Pediatr Clin North Am*. 2015;62:633–648.
- Jacks SK, Witman PM. Tuberous Sclerosis Complex: An Update for Dermatologists. *Pediatr Dermatol*. 2015;32:563–570.
- Mac Keigan JP, Krueger DA. Differentiating the mTOR inhibitors everolimus and sirolimus in the treatment of tuberous sclerosis complex. *Neuro Oncol*. 2015; 17:1550–1559.
- Ng KH, Ng SM, Parker A. Annual review of children with tuberous sclerosis. *Arch Dis Child Educ Pract Ed*. 2015;100:114–121.
- Au KS, Williams AT, Roach ES, Batchelor L, Sparagana SP, Delgado MR, et al. Genotype/phenotype correlation in 325 individuals referred for a diagnosis of tuberous sclerosis complex in the United States. *Genet Med*. 2007;9:88–100.
- Wheless JW, Almoazen H. A novel topical rapamycin cream for the treatment of facial angiofibromas in tuberous sclerosis complex. *J Child Neurol*. 2013;28:933-6.
- Koenig MK, Hebert AA, Roberson J, Samuels J, Slopis J, Woerner A, et al. Topical rapamycin therapy to alleviate the cutaneous manifestations of tuberous sclerosis complex: a double-blind, randomized, controlled trial to evaluate the safety and efficacy of topically applied rapamycin. *Drugs R D*. 2012;12:121-6.
- Weiss ET, Geronemus RG. New Technique Using Combined Pulsed Dye Laser and Fractional Resurfacing for Treating Facial Angiofibromas in Tuberous Sclerosis. *Lasers Surg Med*. 2010;42:357-60.
- Li S, Takeuchi F, Wang JA, Fan Q, Komurasaki T, Billings EM, et al. Mesenchymalepithelial interactions involving epiregulin in tuberous sclerosis complex hamartomas. *Proc Natl Acad Sci U S A*. 2008;105:3539-44.
- Davies DM, de Vries PJ, Johnson SR, McCartney DL, Cox JA, Serra AL, et al. Sirolimus therapy for angiomyolipoma in tuberous sclerosis and sporadic lymphangioliomyomatosis: a phase 2 trial. *Clin Cancer Res*. 2011;17:4071-81.
- Franz DN, Agricola K, Mays M, Tudor C, Care MM, Holland-Bouley K, et al. Everolimus for subependymal giant cell astrocytoma: 5-year final analysis. *Ann Neurol*. 2015;78:929-38.
- French JA, Lawson JA, Yapici Z, Ikeda H, Polster T, Nabbout R, et al. Adjunctive everolimus therapy for treatment-resistant focal-onset seizures associated with tuberous sclerosis (EXIST-3): a phase 3, randomised, double-blind, placebo controlled study. *Lancet*. 2016;388:2153-63.

17. Franz DN, Belousova E, Sparagana S, Bebin EM, Frost M, Kuperman R, et al. Efficacy and safety of everolimus for subependymal giant cell astrocytomas associated with tuberous sclerosis complex (EXIST-1): a multicentre, randomised, placebo-controlled phase 3 trial. *Lancet*. 2013;381:125-32.
18. Bissler JJ, Kingswood JC, Radzikowska E, Zonnenberg BA, Frost M, Belousova E, et al. Everolimus for angiomyolipoma associated with tuberous sclerosis complex or sporadic lymphangiomyomatosis (EXIST-2): a multicentre, randomised, double-blind, placebo-controlled trial. *Lancet*. 2013;381:817-24.
19. Kingswood JC, d'Augères GB, Belousova E, Ferreira JC, Carter T, Castellana R, et al. Tuberous Sclerosis registry to increase disease Awareness (TOSCA) - baseline data on 2093 patients. *Orphanet J Rare Dis*. 2017;12:2.
20. Kotulska K, Chmielewski D, Borkowska J, Jurkiewicz E, Kuczyński D, Kmiec T, et al. Long-term effect of everolimus on epilepsy and growth in children under 3 years of age treated for subependymal giant cell astrocytoma associated with tuberous sclerosis complex. *Eur J Paediatr Neurol*. 2013;17:479-85.
21. Anvisa.gov.br [Internet]. Afinitor. Drug leaflet. Suíça: Novartis Pharma Stein AG. [cited 2018 Mar 14]. Available in: [http://anvisa.gov.br/datavisa/fila\\_bula/frmVisualizarBula.asp?pNuTransacao=6303092015&pIdAnexo=2744450](http://anvisa.gov.br/datavisa/fila_bula/frmVisualizarBula.asp?pNuTransacao=6303092015&pIdAnexo=2744450).
22. Anvisa.gov.br [Internet]. Rapamune. Drug leaflet. Irlanda: Pfizer Ireland Pharmaceuticals. [cited 2018 Mar 14]. Available in: [http://www.anvisa.gov.br/datavisa/fila\\_bula/frmVisualizarBula.asp?pNuTransacao=11519742017&pIdAnexo=7326672](http://www.anvisa.gov.br/datavisa/fila_bula/frmVisualizarBula.asp?pNuTransacao=11519742017&pIdAnexo=7326672).
23. Nathan N, Wang JA, Li S, Cowen EW, Haughey M, Moss J, et al. Improvement of tuberous sclerosis complex skin tumors during long-term treatment with oral sirolimus. *J Am Acad Dermatol*. 2015;73:802-8.
24. Bissler JJ, Kingswood JC. Optimal treatment of tuberous sclerosis complex associated renal angiomyolipomata: a systematic review. *Ther Adv Urol*. 2016;8:279-290.
25. Switon K, Kotulska K, Janusz-Kaminska A, Zmorzynska J, Jaworski J. Tuberous Sclerosis Complex: From Molecular Biology to Novel Therapeutic Approaches. *IUBMB Life*. 2016;68:955-62.
26. Kotulska K, Borkowska J, Jozwiak S. Possible prevention of tuberous sclerosis complex lesions. *Pediatrics*. 2013;132:e239-42.