



## Research Article

# Expression of Alpha-Methylacyl-Coenzyme A Racemase (AMACR) in Colorectal Neoplasms

Authors

Dr S.A.K. Adil<sup>1</sup>, Dr Neha Saroha<sup>2</sup>, Dr Bharathi M<sup>3</sup>

Department of Pathology, Mysore Medical College and Research Institute, Mysore, Karnataka

\*Corresponding Author

Dr Neha Saroha

## Abstract

**Introduction:** Colorectal cancers are gaining importance globally as major cause of morbidity and mortality. AMACR is a dietary enzyme which aids in beta-oxidation of branched chain fatty acids. Hence, its expression in colorectal premalignant lesions and carcinoma suggest possible role in its carcinogenesis.

**Aim:** To study the expression of AMACR in colorectal neoplasms and its correlation with the histological grade.

**Materials and Methods:** It is a hospital based retrospective study. 30 blocks were retrieved from tissue samples previously diagnosed as colorectal neoplasms at Mysore Medical College, Mysore during a period of 2 years. AMACR expression was studied by Immunohistochemistry and correlated with histological grade. Mean, frequency and Chi-square tests were used for analysis.

**Results:** Out of 30 samples with colorectal tumours, 25 were malignant (83.3%) and 5 were benign (16.7%). Age of the study population ranged between 35-75 years. Most of the patients were above 45 years of age (86.6%). Females were affected equally as males representing 50% each. Histological grading revealed 21 cases of well differentiated tumours (84%), 1 case of moderately differentiated tumour (4%) and 3 cases of poorly differentiated tumour (12%). Overall, study showed positive AMACR expression in colorectal neoplasms (63%) and significant correlation between histological grade of carcinoma and AMACR expression.

**Conclusion:** This study showed increased expression of AMACR in colorectal carcinomas and weakly in adenomas as compared to normal colonic mucosa which suggests its possible role in colorectal carcinogenesis. Loss of AMACR immunostaining in poorly differentiated carcinomas suggests its role in tumour differentiation. AMACR can be used as possible therapeutic agent.

**Keywords:** Colorectal cancers, Alpha-Methylacyl-Coenzyme A Racemase (AMACR), Immunohistochemistry.

## Introduction

Colorectal cancer is the third most common cancer accounting for 10% of global cancer incidence. With changing lifestyle and dietary habits, two-fold rise in its incidence is estimated

by 2025.<sup>(1)</sup> A major etiological factor is lifestyle involving diet rich in fat and animal proteins like red meat.<sup>(2)</sup> Red meat and dairy products are rich in branched chain fatty acids which require an enzyme AMACR (P504S) for their oxidation.

AMACR, also known as P504S, is a well characterized enzyme, plays an important role in bile acid biosynthesis and  $\beta$ -oxidation of branched-chain fatty acids.<sup>(3)</sup> It catalyses a key step in the metabolism of fatty acids and fatty acid derivatives via conversion of (2R) fatty acids into their S- stereoisomers, which is further metabolised and degraded to produce energy; which is a hallmark of many cancer cells.<sup>(4,5)</sup>

AMACR is transported to both peroxisomal and mitochondrial compartments and is detectable in tissues like normal hepatocytes, epithelial cells of renal tubules, bronchial epithelium, salivary glands and gall bladder.<sup>(1)</sup> AMACR is overexpressed in High-grade intraepithelial neoplasia of prostate, primary and metastatic prostate cancer.<sup>(6)</sup> Also, overexpressed in HCC, Lung carcinoma, Bladder carcinoma, Lymphoma, renal cell carcinoma and melanoma.<sup>(7)</sup>

In view of the above promising data, this study aims to bring new insights into AMACR immunostaining in colorectal neoplasms and its prognosis and its future use in tailored and personalized therapy of the same.

### Objectives

The present study aims to study the expression of AMACR in colorectal neoplasms and to correlate expression of AMACR in colorectal cancer with its histological grade.

### Materials and Methods

This is a hospital-based retrospective study conducted over 2 years i.e. January 2017 to January 2019 at Mysore Medical College and Research Institute, Mysore, Karnataka. 30 blocks were retrieved which were previously diagnosed as 25 colorectal carcinomas and 5 colorectal adenomas. Non- neoplastic lesions of colon and rectum; necrotic and autolysed tissues were excluded from the study. Patient identification and other information was obtained from hospital records.

Sections of 3-4  $\mu$ m in thickness was obtained from each formalin- fixed paraffin wax embedded

tissue, using microtome. AMACR expression was studied by standard immunohistochemistry (IHC) methods.

Normal colonic mucosa was used as control. Cytoplasmic staining was scored as negative(0), weak (1+), moderate (2+) and strong(3+). The extent of staining was represented as percentages of positive staining areas in relation to the whole carcinoma area. It was scored as 0-5% (Score 0), 6-20% (Score 1), 21-40% (Score 2), 41-60% (Score 3), 61-80% (Score 4), and 81-100% (Score 5). For the purpose of statistical analysis, tumour having score >1 was considered positive.

Colorectal cancers were divided into 3 grades on the basis of arrangement of cells with regard to degree of tubular (acinar) formation-

Well- differentiated (>95% tubular formation)

Moderately- differentiated (50-95%)

Poorly- differentiated (<50%)

Statistical analysis was done, frequencies, means and chi-square test values were calculated. P value <0.05 was considered significant.

### Results

A total of 30 cases were included in this study, 25 of them were malignant (83.3%) and 5 were benign (16.7%). Age of the study population ranged from 35-75 years. Most of the patients were above 45 years of age (86.6%). Females were affected equally as Males, representing 50% each. Histological grading revealed 21 cases of well differentiated tumors (84%), 1 case of moderately differentiated tumors (4%) and 3 cases of poorly differentiated tumors (12%).

There was no AMACR expression in normal colonic mucosa which was used as control (Fig, 1). Out of 5 cases of adenoma, 20% were weakly positive (1/5) and 80% were negative (4/5) and none showed strong expression. A total of 72% (18/25) cases of carcinoma were positive and 28% (7/25) showed no expression.

Overall, colorectal neoplasms showed significant AMACR expression (63%). Statistical analysis showed no significant correlation between

AMACR expression in colorectal adenoma and carcinoma. (Table 1)

Statistical analysis revealed that there was significant correlation between AMACR expression in different grades of the tumour (  $p <$

0.05). There was loss of AMACR immunostaining in poorly -differentiated carcinomas as compared to well- differentiated carcinomas. AMACR expression in carcinoma of different grades is shown in Table 2.

**Table 1:** AMACR Expression in Colorectal Neoplasms

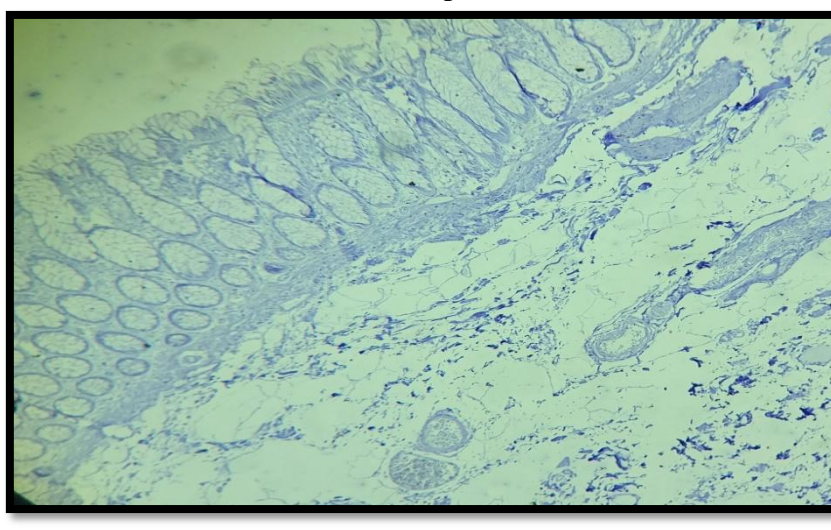
SAMPLE	AMACR				TOTAL	
	POSITIVE		NEGATIVE		N	%
	N	%	N	%		
MALIGNANT	18	72%	7	28%	25	84%
BENIGN	1	20%	4	80%	5	16%
TOTAL	19	63%	11	37%	30	100%

**Table 2:** Correlation between AMACR expression and grade of Colorectal Carcinoma

GRADE	AMACR				TOTAL	
	POSITIVE		NEGATIVE		N	%
	N	%	N	%		
WELL-DIFFERETIATED	16	76%	5	24%	21	84%
MODERATELY-DIFFERENTIATED	1	100%	0	0%	1	4%
POORLY-DIFFERENTIATED	1	33%	2	67%	3	12%
TOTAL	18	72%	7	28%	25	100%

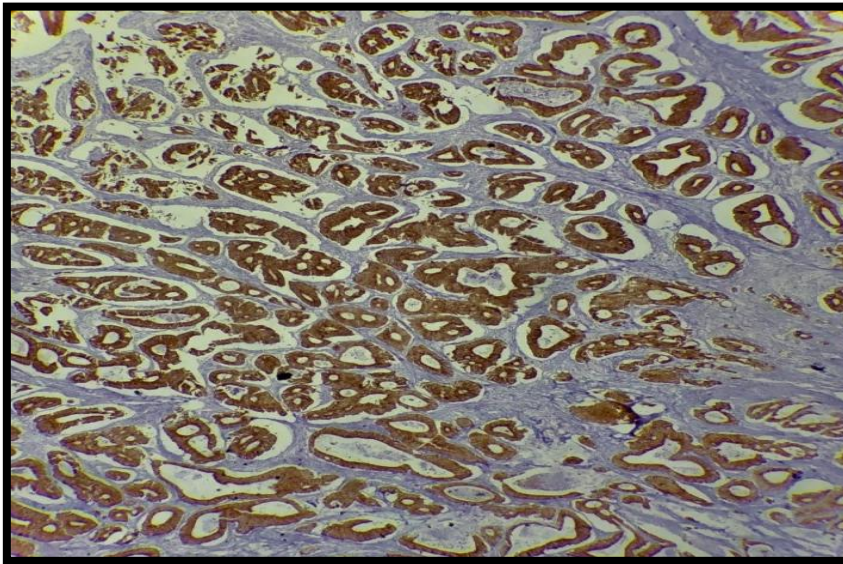
p value < 0. 05

**Figure 1:** Normal colonic mucosa with no AMACR expression

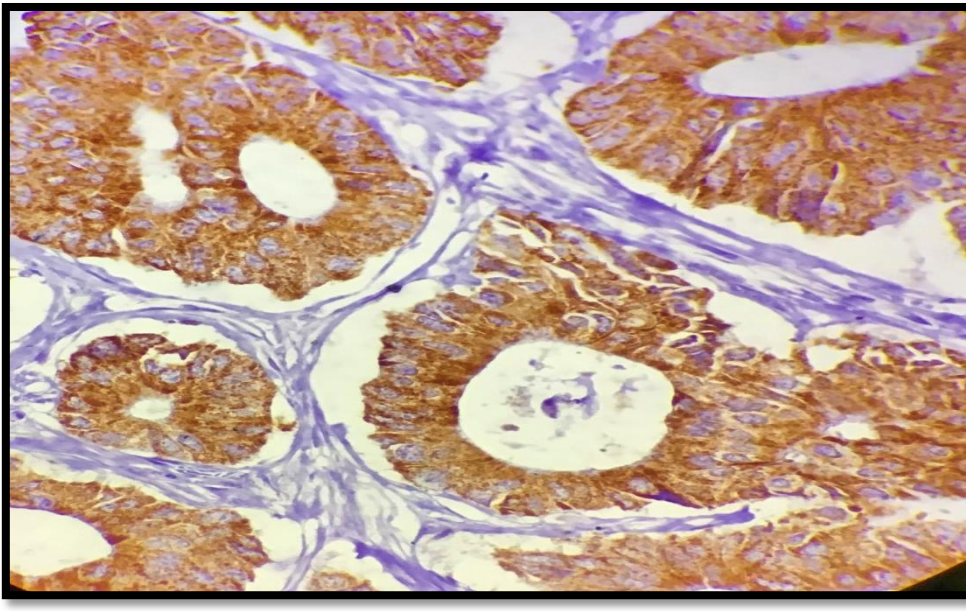




**Figure 2:** Well-differentiated Colonic carcinoma showing strong positive AMACR expression (4X)



**Figure 3:** Neoplastic glands in colon showing strong cytoplasmic AMACR expression. (40X)



### Discussion

Colorectal cancers is one of the most common cancers among men and women in Western population. There is increasing trend seen in its incidence in India most likely due to changing in lifestyle and diet.

The present study revealed increased AMACR expression in colorectal cancer cases (72%). It is consistent with previous results reported by Jiang et al (69%)<sup>(8)</sup>; Lin A et al (75%)<sup>(9)</sup>; Max et al (81.7%)<sup>(10)</sup>; Nidhi Shukla et al (66%)<sup>(11)</sup>; Shi et al (60%)<sup>(12)</sup>.

The present study revealed majority of colorectal adenomas showing negative or weak expression with AMACR (20%). The results are much lower than reported in previous studies like Jiang et al (79%); Lin A et al (64%); Nidhi Shukla et al (75%)

There is significant upregulation of AMACR in well to moderately differentiated carcinomas. But, there is low expression in cases of poorly or undifferentiated carcinomas. Present study showed AMACR expression in Grade 1- 76% (16/21); Grade 2- 100% (1/1); Grade 3- 33% (1/3). Findings are consistent with previous

hypotheses, Lin A et al, Max et al and Jiang et al who all concluded significant correlation of AMACR expression with the grade of carcinoma. It is hypothesised that AMACR is overexpressed in the development of cancer, playing an important role in providing energy for the neoplastic cells. However, as the tumors become dedifferentiated, they no longer require these sources of energy. Poorly differentiated tumors may take over other pathways to accomplish this same activity.<sup>13</sup> Supporting this hypothesis, present study showed decreased expression of AMACR in poorly-differentiated carcinomas suggesting its role in differentiation of the tumour. Thus, AMACR may serve as novel molecular marker for detection of early colorectal cancers.

### Recommendations

Similar study can be conducted with larger sample size and follow up of the cases for correlating AMACR expression with disease-free survival and overall survival.

### Conclusion

This study showed increased AMACR expression in colorectal carcinomas and weak expression in adenomas as compared to normal colonic mucosa. This suggests its role in colorectal carcinogenesis. This study established significant correlation with tumour differentiation as loss of AMACR immunostaining was seen in poorly differentiated carcinomas and thus poorer prognosis for the patient. This study points towards its prognostic significance in colorectal neoplasia and thus targeted therapy against it.

### References

1. Stewart BW, Wild CP, World Cancer Report, Lyon: IARC Press;2014
2. Jhaji K, Sood N, Malhotra V. Histopathological profile of tumours of Midgut and Hindgut- Five Year Study in Tertiary Care Hospital with review of literature. The International Journal of Pathology.
3. Ferdinandusse S et al. Subcellular localization and physiological role of alpha-methylacyl-coA racemase. J Lipid Res 2000; 41:1890-1896
4. Lloyd MD et al- Alphamethyl acyl-CoA Racemase- an 'obscure' metabolic enzyme takes centre stage. FEBS J 275: 1089-1102
5. Lloyd MD et al- Alphamethyl acyl- CoA Racemase( AMACR): metabolic enzyme, drug metabolizer and cancer marker P504S: Prog Lipid Res 52 : 220-230
6. Ouyang B et al. Alpha methylacyl- CoA racemase spliced variants and their expression in normal and malignant prostate tissue. Urology 77: 249 e1- 249 e7
7. Emam E et al. Lack of AMACR immunostaining is an independent predictor of poor prognosis in colorectal carcinoma. J Clin Exp Pathol 2016. 6:3
8. Jiang Z et al. A dietary enzyme: alpha-methylacyl-CoA racemase/P504S is overexpressed in colon carcinoma. Cancer Detect Prev 2003;27:422-6
9. Lin A, Weiser MR, Klimstra DS, Paty PB, Tang LH, Al-Ahmadie H, et al (2007). Differential expression of alpha-methylacyl-coenzyme A racemase in colorectal carcinoma bears clinical and pathologic significance. Hum Pathol 38:850-856.
10. Marx A et al (2008). AMACR expression in colorectal cancer is associated with left-sided tumor localization. Virchows Arch 453:243-248
11. Nidhi Shukla et al. Expression of Alpha-Methylacyl- Coenzyme A Racemase (AMACR) IN Colorectal neoplasia. Journal of Clinical and Diagnostic Research, 2017 Apr, Vol-11(4): EC35-EC38
12. Shi X (2007). Alpha-methylacyl-CoA racemase/P504S overexpression in colorectal carcinoma is correlated with tumor differentiation. Appl

Immunohistochem Mol Morphol 15:175–180.

13. Kuefer R, Varambally S, Zhou M, Lucas PC, Loeffler M, Wolter H. Alpha-Methylacyl-CoA racemase: expression levels of this novel cancer biomarker depend on tumor differentiation. *Am J Pathol.* 2002 Sep;161(3):841-8.