



Compound Palmar Ganglion: A Case Report

Authors

Dr Sarita Asotra¹, Dr Shikha Sharma², Dr Mukand Lal³, Dr Ankita Sharma⁴

¹Associate Professor, Department of Pathology, IGMC, Shimla

²Senior Resident, Department of Pathology, IGMC, Shimla

³Professor and Head, Department of Orthopaedics, IGMC, Shimla

⁴Junior Resident, Department of Pathology, IGMC, Shimla

*Corresponding Author

Dr Shikha Sharma

Abstract

Tuberculosis is still widely present in a developing country like our's especially more so in immunocompromised individuals. Compound palmar ganglion is also known as tuberculous tenosynovitis of flexor tendons of wrist and hand and is a rare entity. With a wide variety of differential diagnosis and non specific clinical, radiologic and histopathological findings, there is often a delay in diagnosis and treatment of compound palmar ganglion, that results into complications. The diagnosis is often confirmed on histopathological and culture investigations. We present a case of compound palmar ganglion in an 85 year old female who presented to the Orthopaedics OPD with complains of pain and swelling in the right hand and wrist without any history of trauma or any past illness. A diagnosis of compound palmar ganglion was made on histopathology. The patient has been on follow up with an uneventful course of disease.

Introduction

Compound palmar ganglion is an old term to signify tuberculous tenosynovitis of the ulnar and/or radial bursae⁽⁴⁾. Although rare, Tuberculous tenosynovitis is still a leading cause of chronic tendon sheath infection. It occurs either by direct inoculation or by hematogenous dissemination from a primary focus; lungs, lymph nodes, kidney,⁽¹⁾ spine and precipitated by immunosuppression, local / systemic steroid, alcoholism, malnutrition and trauma⁽³⁾. The palmar synovial bursa, covered by a dense palmar fascia, is not a common site for tuberculosis. But once infected, it can cause inflammation of all tendon sheaths about the hand and wrist resulting

in median nerve compression⁽²⁾. The condition is best managed in its early stages before it spreads to the underlying bones causing destruction.

Case Report

85 years old female arrived to the orthopaedics OPD with complains of pain and swelling in the right hand and wrist since last 1 month that increased gradually. No history of trauma or any past illness was recorded. On local examination, right wrist movement was painful and restricted. Finger movements were painful. Lab investigations revealed moderate anemia and raised ESR. MRI wrist showed thickened enhancing synovium along flexor tendons, distal

radioulnar joint and intercarpal joint region right hand. Flattening and compression of median nerve with palmar bowing of flexor retinaculum. Radiologic possibility of carpal tunnel syndrome along with inflammatory pathology was suggested and rheumatological correlation was advised. Rh factor by latex agglutination came to be negative. a provisional diagnosis of carpal tunnel syndrome with median nerve involvement with compound palmar ganglion was made and patient underwent carpal tunnel release and synovectomy procedure. Intraoperative sample was sent to histopathology for examination. Histopathology revealed multiple

fragments lined by flattened epithelium. Underlying stroma was fibrocollagenous along with congested blood vessels and extravasated RBCs. In addition, epithelioid cell granulomas, Langhan's type giant cells, lymphocytes, plasma cells, focal areas of necrosis were seen. ZN stain for AFB was non-contributory. Histopathological diagnosis of granulomatous disease, suggestive of compound palmar ganglion was signed out PCR was advised for further confirmation. RT-PCR however came out to be negative and CB-NAAT also was negative.

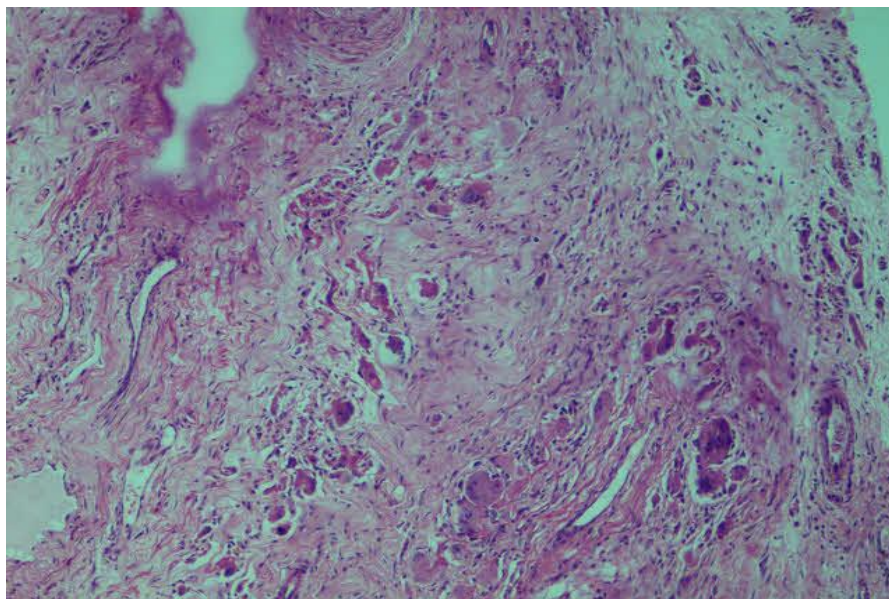


Figure 1 showing fibrocollagenous tissue along with epithelioid cell granulomas.

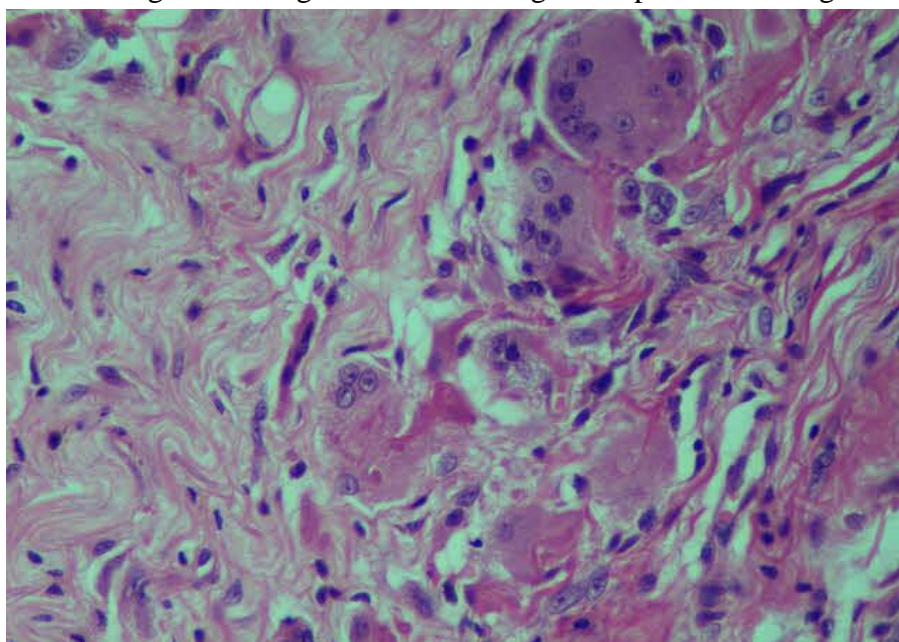


Figure 2 showing langhans type giant cells.

Discussion

Compound palmar ganglion also known as tuberculous tenosynovitis of flexor tendons of wrist and hand is a rare entity. It is seen to be more common in males and mostly involves the dominant limb⁽¹⁾. It usually involves the ulnar bursa alone or in combination with the radial bursa more frequently than the radial bursa itself.⁽⁵⁾ Tuberculosis, although not uncommon in developing countries, especially more so in immunocompromised individuals, affects various organ systems in the body, but involvement of hand and wrist is quite rare.⁽⁶⁾ TB tenosynovitis of the hand constitutes <1% of skeletal TB⁽⁷⁾. Because of its rarity the diagnosis is often delayed. Mycobacterium tuberculosis is the most common causative agent and the diagnosis is always confirmed by histopathology and culture.. The pathologic changes associated with tuberculous tenosynovitis are quite similar to those of intra-articular tuberculous synovitis. The disease reaches the synovial sheath by the direct hematogenous spread or from underlying bone or joint. The infected synovium gets edematous and filled with serous fluid and exudative material and granulation tissue. The synovium becomes hyperplastic thickened and villous. With Excessive movement and friction, the broken villi and fibrinous exudates get molded to resemble rice body or melon seed body⁽⁸⁾. Overtime granulomatous changes, tubercule formation, necrosis and fibrinous exudate appear about the shaggy synovium. If uncontrolled, the tendons become dull, adherent to each other and to the surrounding tissues, and are invaded by the synovium, and ultimately rupture. Tuberculous tenosynovitis may spread to adjacent bones and joints and to the deep spaces of the hand and forearm.⁽⁹⁾ Lab investigations are mostly negative except raised ESR and strongly positive Montoux test, radiograph of wrist and chest are mostly normal, MRI shows marked thickening increased vascularity and fluid in synovial sheath of tendons, histopathological examination shows caseous necrosis, epithelial granuloma and

Langhan's type giant cells. The differential diagnosis of compound palmar ganglion includes rheumatoid arthritis, gouty arthritis, ganglion [infected], sarcoidosis, foreign body tenosynovitis, pyogenic infection and fungal infection, pigmented villonodular synovitis of tendon sheath, amyloidosis and synovial chondromatosis^(10,11,12,13). Early diagnosis, complete debulking and appropriate anti-tubercular therapy is needed to overcome this condition.⁽¹⁴⁾

Conclusion

With such a long list of differential diagnosis and nonspecific clinical, radiological and histopathological findings, there is often a delay in diagnosis of compound palmar ganglion that results into complications. The best way to make a final diagnosis is by open biopsy and mycobacterial culture of the pathological material. According to literature the positive result of synovial fluid AFB staining, culture of mycobacterium, histology and PCR are 32%, 80%, 65% and 63% respectively and PCR can be used for early diagnosis⁽¹⁰⁾. A good clinical awareness is required with keeping tuberculosis as a common cause of chronic tenosynovitis in mind in a developing country like India, which can prevent delay in diagnosis and treatment, thus preventing the resulting complications.

References

1. Seiichi Higuchi, Shinichi Ishihara, Hiroyuki Kobayashi and Taidoh Arai: A mass lesion of the wrist: A rare manifestation of tuberculosis. [DOI: 10.2169/internalmedicine.47.0495]
2. Saleem S, Dab RH, Farooq T, Hameed S. Compound palmar ganglion with carpal tunnel syndrome. J Coll Physicians Surg Pak 2007;17(4):230-1.
3. Hitesh Lall, Suman K Nag, Vijay K Jain, Rahul Khare and Deepak Mittal: Tuberculous extensor tenosynovitis of the wrist with extensor pollicis longus

- ruptures: a case report. Journal of medical case reports 2009, 3:142.
4. Raine AJH, Ritchie HD. Eds. In: Bailey and Love's short practice of surgery. 17th ed. London: H.K. Lewis, & Co., Ltd.; 1977;220.
 5. Husseini Wali, Saleh Al-Khuwaitir, and Mohamed A. Hafeez Compound Palmar Ganglion: A Case Report and Literature Review. Annals of Saudi Medicine, Volume 6, Number 1,1986
 6. Arun Kumar K, Kanthimathi B, Krishnamurthy CS, Sujai S. Compound palmar ganglion: A tubercular manifestation of flexor tenosynovitis of the wrist. International Journal of Case Reports and Images 2012;(2):28-31.
 7. Abdelwahab IF, Bianchi S, Martinoli C, Klein M, Hermann G. Atypical extraspinal musculoskeletal tuberculosis in immunocompetent patients: Part II, tuberculous myositis, tuberculous bursitis, and tuberculous tenosynovites. Can Assoc Radiol J 2006;57:278-86.
 8. Tuli SM. Tuberculosis of the Skeletal System: Bone, Joints, Spine, and Bursal Sheaths. 3rd ed. New Delhi: Jaypee Brothers Medical Publishers; 2004.p.184.
 9. Pimm LH, Waugh W. "Tuberculous tenosynovitis". J Bone Joint Surg (Br).1957;39B:91-101.
 10. Seiichi Higuchi, Shinichi Ishihara, Hiroyuki Kobayashi and Taidoh Arai: A mass lesion of the wrist: A rare manifestation of tuberculosis.
 11. Hitesh Lall, Suman K Nag, Vijay K Jain, Rahul Khare and Deepak Mittal: Tuberculous extensor tenosynovitis of the wrist with extensor pollicis longus ruptures: a case report. Journal of medical case reports 2009, 3:142.
 12. Pei-Hung Shen, Cheng-Mien Chu, Gua-Shu Huang, Shing-Sheng Wu and Chain-Her Lee tuberculous tenosynovitis of the flexor tendons of the wrist and hand: J Med Sci 2002;22[5]:227-230.
 13. M Tyllianakis, G Kasimatis, S Athanaselis, M Melachrinou: Rice body formation and tenosynovitis of the wrist: a case report. Journal of orthopaedic surgery 2006; 14 [2]:208-11.
 14. Gaur TN, Shah M, Rao H. Compound palmar ganglion causing compressive neuropathy of the median nerve. J Orthop Allied Sci 2017;5:48-50.