



‘Mini Molars’ – Case Report & Clinical Guide Lines for Management

Authors

Dr Sajana.E.M¹, Dr Lekshmy S Devi², Dr Lakshmi Aravind³, Dr Sreeja Sreedhar⁴

¹Postgraduate Student, ²Professor and Head, ^{3,4}Professor

Department of Conservative Dentistry and Endodontics, Sri Sankara Dental College, Varkala

Abstract

Three rooted premolars offer a great clinical challenge to endodontic treatment. This article describes about the clinical diagnosis, access opening, and the endodontic management of a three rooted maxillary premolar with rubber dam isolation.

Keywords: Anatomic variations, mini molar, T shaped outline, endodontic management.

Introduction

The challenge associated with endodontic treatment is due to the morphological variations in root canal system. Knowledge regarding the frequent anatomy as well as possible variations help to avoid errors during treatment. The presence of additional roots is extra challenge, and that can influence procedural steps like radiographic assessment, cavity and access design, canal localization and biomechanical preparation of canal system⁽¹⁾. In endodontic literature, the standard anatomy of maxillary first premolar has been described to have crown with two roots – buccal and palatal. Three rooted premolars are uncommon. Its incidence reported as for maxillary first premolar 0.5%-6%⁽²⁾, whereas 0.3%- 2% for maxillary second premolar⁽³⁾. Vertucci and Gegauff found 5% of 400 maxillary first premolars to have three canals: 0.5% existed as three canals in a single root, 0.5% existed as two canals in one root and one canal in a second root, and 4% existed as one canal in each of three separate roots⁽²⁾.

The anatomy of three rooted maxillary premolar is similar to adjacent maxillary molar. So it is having synonyms – small molar, radiculospremolar, miniature three canalled molar or minimolars⁽⁴⁾. There are certain factors reported that influencing the variations in root canal morphology. They are ethnic background, gender and age⁽⁴⁾. Studies shown that variations in root canal morphology are more frequent in Caucasian population and practically less frequent in Asian population^(5,6). Whenever the mesio-distal width of the mid root image is equal to or greater than the mesio distal width of the crown then the tooth will most likely to have three roots⁽⁷⁾.

Case Report

A female patient of 28 years old, reported to the Department of Conservative Dentistry & Endodontics with chief complaint of pain in the upper left posterior region since one week. Her medical history was explored and non – contributory to the routine dental care. Extra oral examination did not provide any significant

findings. Intra oral clinical examination revealed a deep proximal caries on distal aspect of maxillary left first and second premolars (i.e. 24 & 25).

Teeth were responded positively for percussive test, and negatively for thermal vitality test. On radiographic examination, radiolucency extending to pulp horn for 24 & 25 was evident. There was increased mesio- distal width radiographically for 24 in mid root region, and a fast break was noticed in tracing root canals for 24(Figure 1). That made a suspicion for 3 roots for maxillary first premolar and confirmed by multiple angulated radiographs. The diagnosis was made as acute irreversible pulpitis in relation to 24 & 25.

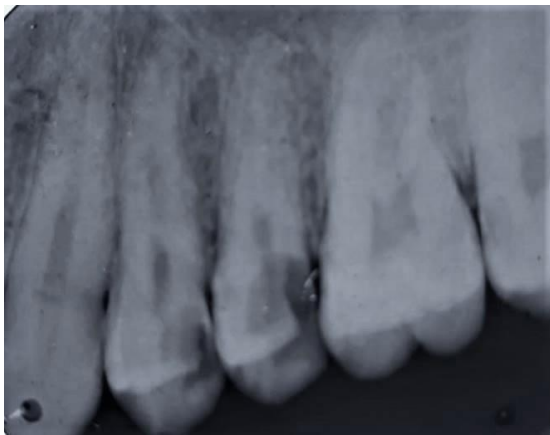


Figure 1 Preoperative radiograph showing greater MD width& a fast break for 24

Endodontic treatment for both maxillary first and second premolars was initiated. Proper anesthesia was given followed by rubber dam isolation. The access cavity preparation was initiated. Access cavity was slightly modified for 24as described by Balleri et al, by giving a cut at the bucco-proximal angle from the entrance of buccal canals to the cavosurface angle resulting in a cavity with T-shaped outline⁽⁸⁾(Figure 2).

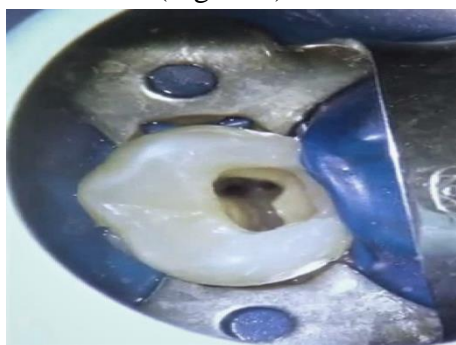

Figure 2 T-shaped outline with 2 buccal canals

The Oval shaped access preparation was made for 25. Patency was achieved for 24- using # 10 size K file for mesiobuccal and distobuccal canals, # 15 size K file for palatal canal. Patency for 25 was achieved with # 15 size K file. The working length was established with apex locator and confirmed radiographically for each root (Figure 3)

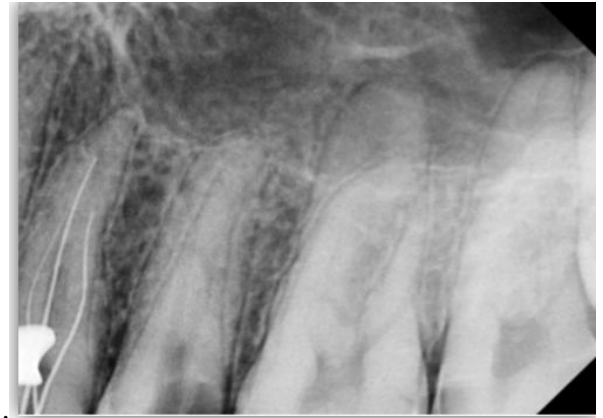

Figure 3 Establishing working length and confirmed by radiograph

Coronal flaring was carried out with GG burs sizes- 50, 70 and 90. Cleaning and shaping was carried out using Pro Taper gold file up to F3 size. Sodium hypochlorite (5.25%), saline and EDTA (17%) were used for copious irrigation followed by placement of intra canal medication for 1 week. Calcium hydroxide was used as intracanal medication. Second appointment was scheduled after 7 days, and teeth were re-entered. The canals were cleaned and irrigated and made ready for obturation. Obturation was completed with AH 26 sealer (Densply, Germany) (Figure 4).

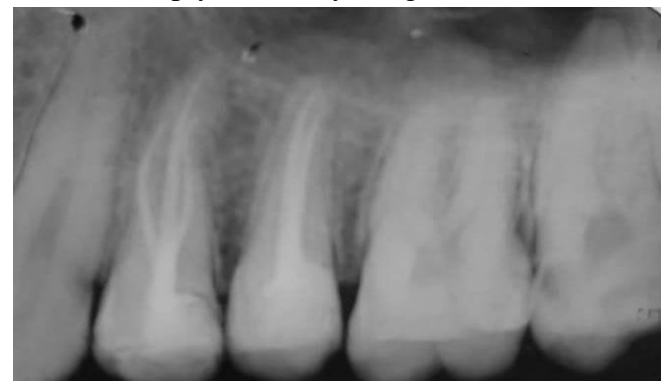

Figure 4 Post obturative radiograph

Discussion

Awareness about variations in root canal morphology, complete canal debridement and obturation are essential for success of endodontic treatment. More than 95% teeth conformed to the guidelines or laws of pulp chamber anatomy proposed by Krasner and Rankow⁽⁹⁾.

Maxillary premolars generally having two canals and variation exist is three rooted premolars. Incidence of three rooted premolars increased in last decade. It is said to be due to advancement in diagnosing systems like digital radiography, loupes and microscopes etc.

Root morphology of maxillary premolar is divided in to 3 groups:

1. Three fused roots/ fused buccal roots & partially fused or separated palatal root
2. Buccal roots fused at middle or apical third, and with a separated or partially fused palatal root
3. All three roots separated at cervical third⁽¹⁰⁾.

According to Ahmad et al 2016, root and root canal morphology can be the following,

- A. Single rooted premolar with type III(1-2-1) canal configuration
- B. Two rooted premolar with 2 buccal canals(2-2) and single palatal canal
- C. Three rooted and 3 canalled premolar⁽⁴⁾

Clinical diagnosis can be done by examination of crown. And a wide mesio-distal dimension of crown compared with its bucco-lingual dimension will suggest for presence of extra roots or root canals. Accurate pre-operative radiographs, both straight and angled are must to giving a clear cut idea about the number of roots and root canals present in tooth. The radiographical diagnosis can be done by analyzing certain features-

- i. Sudden disappearance of pulp space
- ii. Abruptly straightening / broadening of canals
- iii. Difficulty in tracing the continuity of canal/ presence of fast break
- iv. MD width of the mid root region is greater than MD width of the crown

These features give clue about extra root or canal. The confirmation should be done with angulated

periapical radiographs or with digital imaging techniques. The periapical radiographs with angle variations may facilitate diagnosis in group 1 cases, while those without angle variation favor the other 2 groups⁽⁷⁾. In some cases radiographic analysis may become inadequate, can use CBCT as a diagnostic tool to determine the canal morphology.

If presence of extra roots or canal is confirmed, then consider for a modified access preparation. The traditional oval shape for maxillary premolar should be modified to triangular shape with base on the buccal side while apex on palatal side (or vice versa in teeth with 2 palatal roots and 1 buccal roots.). Finally, cavity acquires a T- shaped outline⁽⁸⁾.

There is no difference reported in success rates for 3 rooted premolars in relation to different obturation techniques (cold lateral compaction & vertical warm compaction techniques)⁽⁴⁾.

Conclusion

Morphological variations in pulpal anatomy must be always considered before beginning treatment. Careful clinical and radiographical examination will give idea about underlying tooth internal anatomy and helpful for successful endodontic treatment. Use of an operating microscope or loop can enhance the visualization of the pulp chamber and extra canal orifices.

References

1. Soares JA, Leonardo RT. Root canal treatment of three- rooted maxillary first and second premolars—a case report. *International endodontic journal*. 2003 Oct;36(10):705-10.
2. Vertucci FJ, Gegauff A. Root canal morphology of the maxillary first premolar. *Journal of the American Dental Association* (1939). 1979 Aug;99(2):194-8.
3. Sathyanarayanan K, Srinivasan MR, Balagopal S, Poornima L. Report of occurrence and endodontic management of

- three-rooted maxillary first and second premolars in the same individual. *Indian Journal of Dental Research*. 2017 May 1;28(3):337.
4. Ahmad IA, Alenezi MA. Root and root canal morphology of maxillary first premolars: a literature review and clinical considerations. *Journal of endodontics*. 2016 Jun 1;42(6):861-72.
 5. Cardinali F, Cerutti F, Tosco E, Cerutti A. Preoperative diagnosis of a third root canal in first and second maxillary premolars: a challenge for the clinician. *Endodontic Practice Today*. 2009 Mar 1;3(1).
 6. Nallapati S. Three-canal maxillary premolar teeth: a common clinical reality. *Endodontic Practice*. 2003;6:22-8.
 7. Sieraski SM, Taylor GN, Kohn RA. Identification and endodontic management of three-canal maxillary premolars. *Journal of endodontics*. 1989 Jan 1;15(1):29-32.
 8. Balleri P, Gesi A, Ferarri M. Primer premolar superior comtresraices. *Endodontic Practice*. 1997;3:13-15.
 9. Krasner P, Rankow HJ. Anatomy of the pulp-chamber floor. *Journal of endodontics*. 2004 Jan 1;30(1):5-16.
 10. Bellizzi R, Hartwell G. Evaluating the maxillary premolar with three canals for endodontic therapy. *Journal of endodontics*. 1981 Jan 1;7(11):521-7.