



## A study on the efficacy of Levobupivacaine with Buprenorphine in comparison to Levobupivacaine alone in ultrasound guided supraclavicular brachial plexus block

Authors

Arvind<sup>1</sup>, Mohd Khalik Ansari<sup>2</sup>, Neeharika Arora<sup>3</sup>, Malti Agrawal<sup>4</sup>,  
Rampal Singh<sup>4</sup>, Gopal Krishan<sup>5</sup>

<sup>1</sup>Junior Resident, Department of Anaesthesiology, RMCH Bareilly

<sup>2</sup>Assistant Professor, Department of Anaesthesiology, RMCH Bareilly

<sup>3</sup>Professor, Department of Anaesthesiology, RMCH Bareilly

<sup>4</sup>Professor & Head, Department of Anaesthesiology, RMCH Bareilly

<sup>5</sup>Associate Professor, Department of Anaesthesiology, RMCH Bareilly

\*Corresponding Author

**Dr Mohd Khalik Ansari**

Assistant Professor, Department of Anaesthesiology, RMCH Bareilly (U.P.) India

### Abstract

**Objective:** A clinical study to determine the onset of action & duration of sensory and motor block and to study the duration of analgesia.

**Material and Methods:** Eighty ASA physical status Grade 1 and 2 patients of either sex, between 18-60 years of age & BMI 18.5- 30 undergoing elective and emergency upper limb surgeries were selected for the study. After a thorough history and examination patients were divided into two groups of 40 each, depending on the drug administration. Group A: It consists of patients who were given 25 ml of 0.5 % Levobupivacaine with 0.5 ml normal saline. Group B: It consists of patients who were given 25 ml of 0.5 % Levobupivacaine with 0.5 ml of Buprenorphine (150µg). The onset time of the sensory and motor blocks; the time required for complete sensory and motor blocks; the total duration of analgesia, the haemodynamic changes and side effects were determined and compared in both the groups.

**Results:** It was observed that addition of Buprenorphine as an adjuvant to local anesthetics for brachial plexus makes sensory (9.67±2.34 mins) and motor (13.10±3.29 mins) onset earlier than plain local anesthetic agent (sensory 12.45±3.96 mins and motor 14.865±4.08 mins) used. The duration of sensory (8.11±1.58 hrs. and 14.72±3.09 hrs) and motor (10.77±1.57 hrs. and 16.71±3.39 hrs) block was significantly longer in the Buprenorphine group than in the control group (p-value < 0.001). All patients in both groups remained hemodynamically stable with no significant difference in vital parameters at all times. The postoperative pain score and the number of patients who required rescue analgesics and mean number of supplemental analgesics required were also significantly lower in Buprenorphine group as an Adjuvant to local anesthetics.

**Conclusion:** It was concluded that the addition of 150µg (0.5 ml.) of Buprenorphine to 0.5% Levobupivacaine effectively and safely shortens the onset of sensory and motor blockade, increases the duration of sensory and motor blockade and increases the duration of postoperative analgesia without any hemodynamic disturbances.

**Keywords:** Levobupivacaine, Buprenorphine. Ultrasound, Supraclavicular brachial plexus block, Sensory and motor blockade.

## Introduction

Discovery of brachial plexus block was a milestone in the history of anaesthesia. Prior to it, general anaesthesia was administered for upper limb surgeries. Because of its airway related complications and need for stringent post-operative monitoring and care it was associated with increased cost of medical services and greater morbidity in terms of postoperative pain. Regional nerve block is a safe and well accepted technique of anaesthesia since it avoids the untoward effects associated with general anaesthesia, resulting in more favorable outcome along with increased margin of safety especially in ASA grade III and IV patients. Regional anaesthesia in the form of brachial plexus has rapid onset, predictability and dense anaesthesia and has increased its domain from operation theatre to post-operative analgesia and chronic pain management with reduction in requirements of intravenous opioid analgesics thereby reducing post-operative respiratory depression, nausea, vomiting and sedation along with reduced use of NSAIDS thereby reducing bleeding tendencies and NSAIDS induced ulcers.

**William Stewart Halsted** in 1884, first performed brachial plexus block technique by exposing the roots, in New York City at St. Luke's Roosevelt Hospital Centre. **Halsted** used local infiltration for expose the roots surgically and injected under direct vision with a small amount of 0.1 % cocaine.<sup>1</sup> The first percutaneous block was performed independently in 1911 by **Hirschel** and **Kulenkampff** using the axillary and supraclavicular routes, reportedly on himself. The technique was published later in 1928, by **Kulenkampff** and **Persky**. The **Kulenkampff** approach using the supraclavicular route gained greater acceptance as it had better standardized and larger series of cases, which were reported with greater success and had lesser complications. The supraclavicular block was given at the level of the brachial plexus trunks. Here, the three nerve structures confined to a tiny surface area carry the

entire motor, sensory and sympathetic innervations of the upper extremity.

Satisfactory surgical conditions are obtained with complete motor and sensory blockade. The concurrent sympathetic blockade reduces post-operative pain, vasospasm and edema.

Ultrasound guidance provides visualization of anatomical structure hence shorten the block performance time, reduce the number passes, ensuring high nerve block success and improved patient safety, particularly with regard to LAST as the dose of local anaesthetic required for effective block is lower.

Levobupivacaine is a pure S enantiomer of Bupivacaine, Levobupivacaine has emerged as a safer alternative for regional anesthesia than its racemic parent. Levobupivacaine has demonstrated a superior pharmacokinetic profile and less affinity and strength to myocardial depression and central nervous vital centers in pharmacodynamic studies. Levobupivacaine had a lower risk of CNS toxicity when compared with Bupivacaine and/or Dexbupivacaine. No unchanged Levobupivacaine detected in urine or feces as Levobupivacaine is completely metabolized.

Buprenorphine is a high molecular weight opioid agonist-antagonist. It is lipophilic & has high affinity for  $\mu$  receptor and longer duration of action, Buprenorphine is easily available and is cost-effective, side effects like respiratory depression and sedation are less shown by Buprenorphine as compare to other opioids.

We found limited published data on the effect of Buprenorphine as an adjuvant to Levobupivacaine for brachial plexus blocks. No study was found in literature on use of a combination of Levobupivacaine and Buprenorphine for brachial plexus block by supraclavicular approach using ultrasound guidance.

Hence, the present study was undertaken to study the efficacy of addition of Buprenorphine 150 $\mu$ g to 0.5% Levobupivacaine in comparison to Levobupivacaine alone when used in ultrasound

guided supraclavicular brachial plexus block for upper limb surgery.

### Material and Method

**Type of Study:** A prospective randomized controlled study

**Study Duration:** November 2018 to October 2019(one year)

**Sample Size:**2 groups of 40 each

Study Group A: Inj. Levobupivacaine 0.5% 25 ml + 0.5ml Normal Saline

Study Group B: Inj. Levobupivacaine 0.5% 25 ml + Inj. Buprenorphine 150µg 0.5 ml.

**Inclusion Criteria:** patients age between 18-60 years, ASA I & II adult patients of either sex, undergoing upper limb surgery under ultrasound guided supraclavicular brachial plexus block after obtaining written informed consent.

**Exclusion Criteria:** Patient's refusal, Known allergy to local anaesthetics, Infection at local site, Patient with ASA III, IV or V, History of Cardiovascular disorders, Bleeding disorders or patient on Anticoagulant therapy, Pregnant patients, Patients on chronic pain medications, Neuromuscular disorders or pre-existing neurological disease, Respiratory compromise, Hepatic failure, renal failure.

**Procedure:** After carefully explaining the procedure and obtaining a written informed consent, patients were divided randomly into 2 groups using computer generated randomization technique. Tablet Alprazolam 0.25 mg was given at night before and tablet Ranitidine 150 mg was given in the morning at night prior to surgery and 6 AM on the day of operation. IV access was secured and inj. Ondansetron 4 mg IV was given in preoperative room. In the operating room, the patient was placed in supine position, arms adducted and head tilted 45° to the opposite side. Supraclavicular brachial plexus block was performed using an ultrasound system (Toshiba, Nemio SSA-550A, Japan) using a 8–13 MHz linear high-frequency transducer to obtain the best possible transverse view of brachial plexus in transverse plane. Transducer probe was coated

with sterile gel and placed in supraclavicular region above the clavicle. Once the artery, rib, pleura, and plexus are simultaneously in view, a 22 gauge needle was inserted by “in plane” approach from the lateral side of the probe and placed above the plexus. A predetermined volume (25.5 ml) of local anesthetic solution was injected after negative aspiration into the corner pocket between the first rib inferiorly, supraclavicular artery medially, and nerves superiorly. Spread of local anesthetic was observed as distension of brachial plexus sheath. Thereafter, the needle was repositioned to distribute the solution around all nerve trunks and divisions within the plexus sheath. Needle was removed and area was cleaned with sterile paper towel and sealed with sterile dressing.

### Assessment

Onset of sensory block and motor block was assessed every two minutes starting from time of injection till complete block. Pinprick test with a blunt 23 G hypodermic needle, using a 3point scale (0- normal sensation, 1- loss of sensation of prick [analgesia], and 2- loss of sensation of touch [anaesthesia] and compared to contralateral arm.

Assessment of motor block was done at 2 min intervals till 30 min by modified Bromage 3-point score (0 - normal motor function with full flexion and extension of elbow, wrist, and fingers, 1 - decrease motor strength with ability to move fingers and/or wrist only, and Complete motor blockade with inability to move fingers). Plexus block was considered successful when Vester-Anderson's criteria: --at least two out of four nerve territories (Ulnar, Radial, Median and musculocutaneous) are effectively blocked- are fulfilled.

Pain was assessed on a rating scale (VAS), zero representing no pain and 10 meaning worst possible pain. Injection Tramadol 2mg/kg IV was given as rescue analgesic when the VAS score is more than 4.

The duration of analgesia was considered from time of complete sensory block to time of first rescue analgesia.

**Results and Observations**

Both the groups were comparable in the terms of age, sex, body mass index, ASA grade, type of surgical procedure and no statistically significant difference was found.(Table :1)

The mean onset of sensory block in between group A 12.45±3.96 mins and Group B 9.67±2.34 mins. There was highly significant difference in mean onset of sensory block in between group A and Group B ( $p<0.0001$ ) showing that the onset of sensory block was late in Group A.

The mean onset of motor block in between group A 14.865±4.08 mins and Group B 13.10±3.29 mins. There was significant difference in mean onset of motor block in between group A and Group B ( $p<0.05$ ) showing that the onset of motor block was faster in Group B.

In the comparison of mean duration of sensory blockade between the two groups, the mean duration of sensory blockade for group A was 8.11±1.58 hrs and for group B it was 14.72±3.09

hrs. the sensory blockade is longer in B group and it is statistically significant with a  $p$ -value of  $<0.001$ .

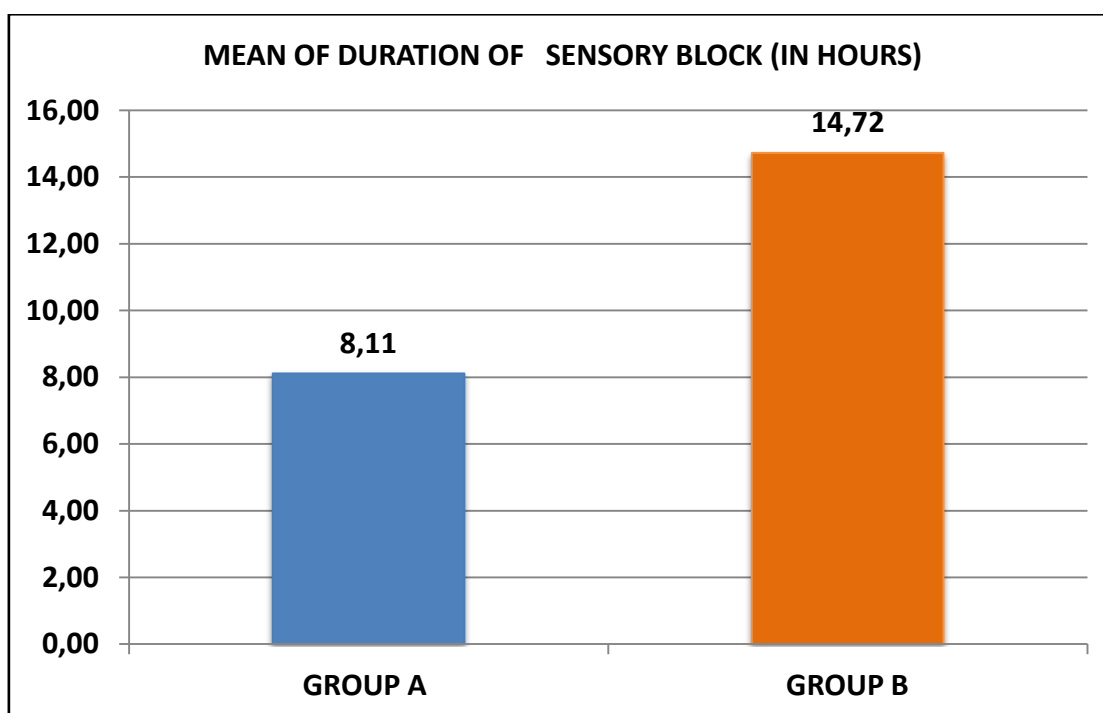
In case of comparing means of duration of motor blockade between the two groups, the mean duration of motor block in between group A 10.77±1.57 hrs. and Group B 16.71±3.39 hrs. There was highly significant difference in mean duration of motor block in between group A & Group B ( $p<0.0001$ ) showing that the duration of motor block was longer in Group B. (Figure: 2).

The mean duration of analgesia in between group A 11.01±1.57 hrs. and Group B 16.99±3.37 hrs. There was highly significant difference in mean duration of analgesia in between group A & Group B ( $p<0.00001$ ) showing that the duration of analgesia was longer in Group B.

Mean pulse rate and mean arterial blood pressure was also comparable in both the groups (Figure: 3 and 4).

**Table 1:** Demographic Profile.

Parameters	Group A (n=40)	Group B (n=40)	p-value
Age (Years)	33.58±11.10	36.40±13.67	0.248
BMI(Kg/M <sup>2</sup> )	21.58±1.56	21.00±1.58	0.103
Gender (M/F)	25/15	25/15	
ASA (I/II)	32/08	31/09	



**Figure 1:** Comparison of duration of sensory blockade between the A and B groups.

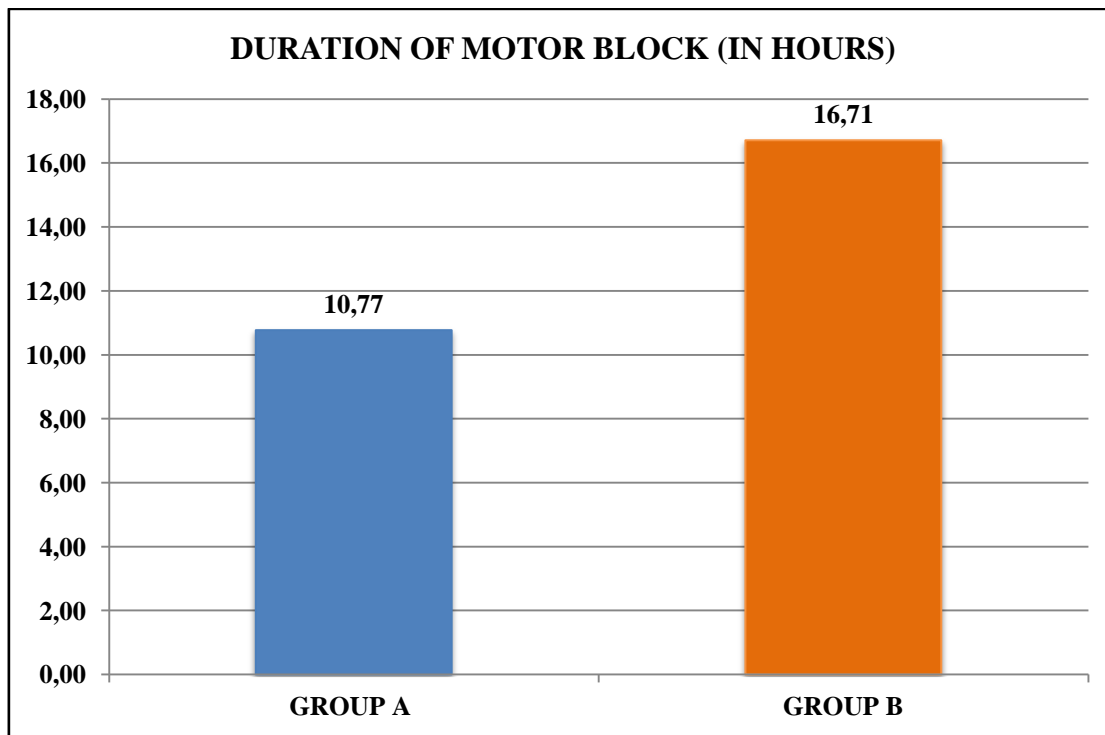


Figure 2: Comparison of duration of motor blockade between the A and B groups.

Table 2: Comparing the mean duration of post op analgesia between the A and B groups.

GROUPS	MEAN (in hours)	S. D	t-value	p-value	
GROUP A	11.01	1.57	10.173	<0.00001	Highly significant
GROUP B	16.99	3.37			

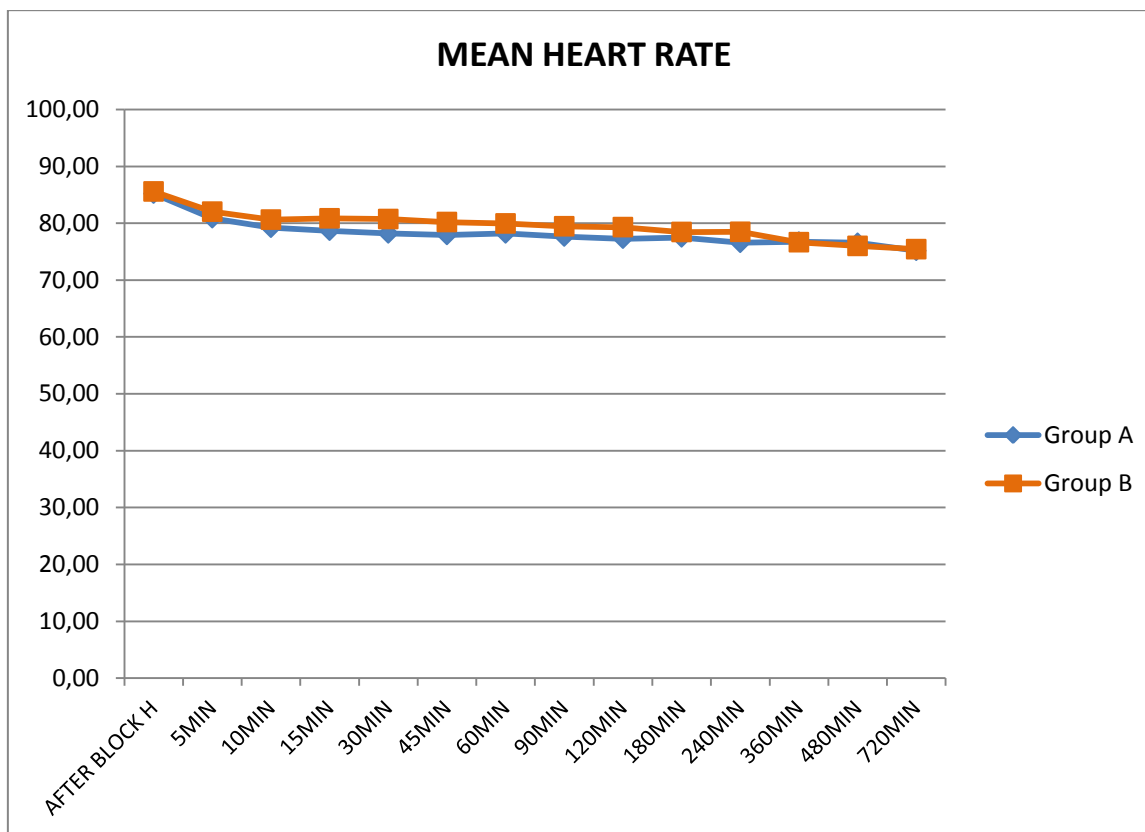
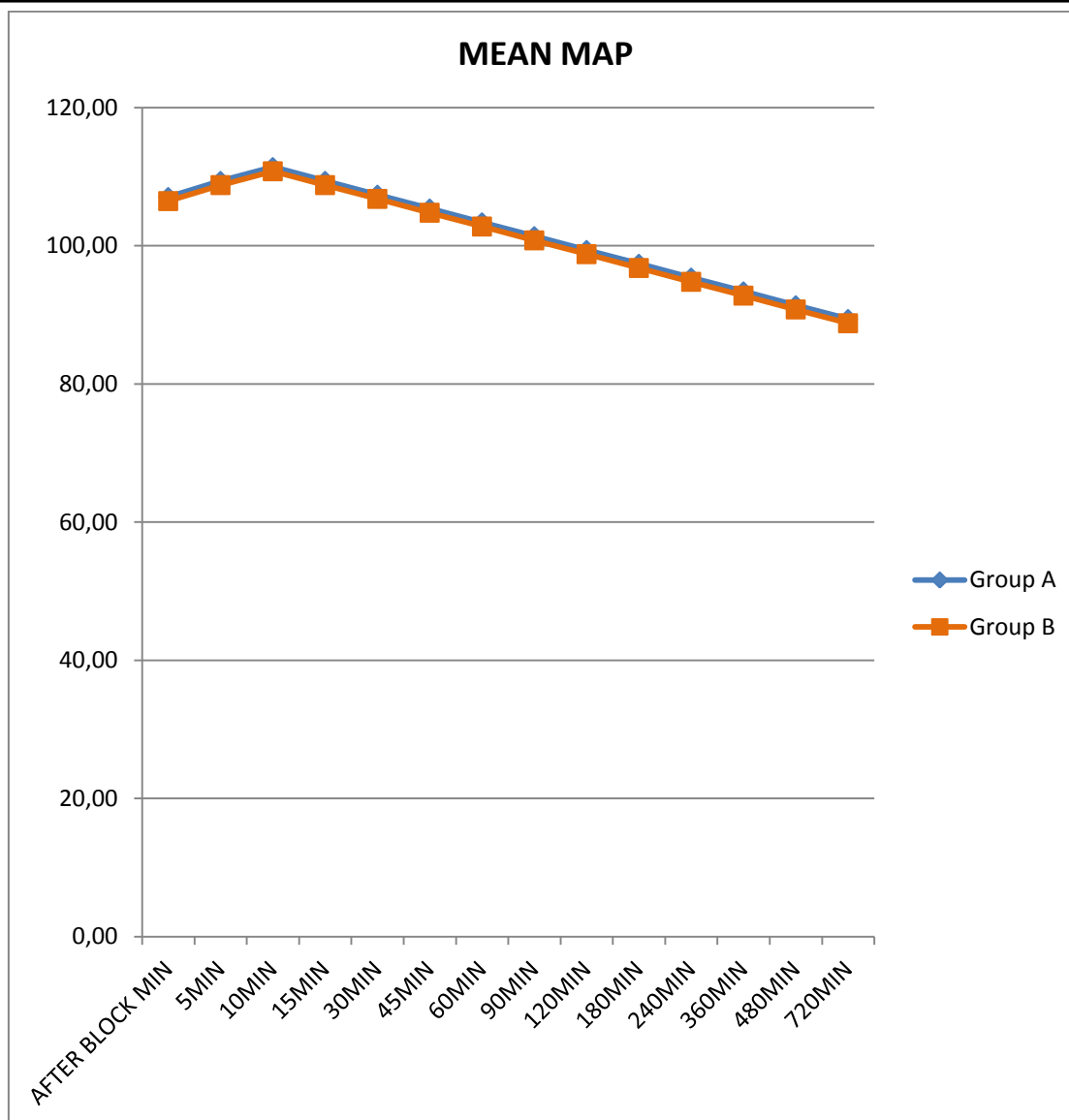


Figure 3: Comparing the mean arterial heart rate between the A and B groups.



**Figure 4:** Comparing the mean arterial blood pressure between the A and B groups.

**Discussion**

Peripheral nerve blocks are cost effective anaesthetic techniques used to provide superb anaesthesia and analgesia while avoiding airway instrumentation and the hemodynamic consequences of general and neuraxial anaesthesia. Of the various local anaesthetics used for the brachial plexus block, Bupivacaine is the most frequently used local anaesthetic as it has a long duration of action varying from three to eight hours. But Levobupivacaine due to its safer cardiovascular profile is now being preferred. The mean age, gender, ASA and BMI for Group A and for group B was comparable. The gender distribution and ASA grade were also comparable in both the groups. The patient characteristics like

gender, age, BMI and ASA in our study groups were similar to that used by **Dixit et al.** The patient age in our study varied between 30 to 40 years which was similar to their study which had a mean age of 36.2 and 37.4 years. Onset of sensory and motor blockade occurred faster in Buprenorphine group as compare to local anaesthetic group. Similar results were also found by **Behr A et al** and **Jain N et al**. We have noted that onset of sensory block was found to be early in one study that used Levobupivacaine 0.75% and another study which used Ropivacaine 0.5%, whereas it was found to be similar in studies that used other local anaesthetic agents. We have not come across any other study that has used Levobupivacaine Buprenorphine combination in



supraclavicular brachial plexus block. There are only few studies that have used ultrasound guided technique for supraclavicular block but none have used Buprenorphine as adjuvant to the local anaesthetic used. Since ultrasound guided is a more precise technique, it may have a bearing on the onset time. Levobupivacaine is known to have a short latency for sensory block than Bupivacaine.

Duration of sensory blockade is more prolonged in Buprenorphine group. The mean duration of sensory block in Group A is 8.11 hrs as compared to 14.72 hrs in Group B. The duration of motor blockade is also more in the Buprenorphine group. Group A had mean duration of motor block of 10.77 hrs as compared to Group B with 16.71 hrs. the similar results were also found by **Dixit et al** **Thakur D et al** and **Sanghvi KS et al**. Addition of Buprenorphine to local anaesthetic in brachial blocks significantly prolonged the duration of sensory and motor blockade in our study as well as in various studies done previously by others.

The mean duration of analgesia for Levobupivacaine + Buprenorphine Group was longer as compare to Levobupivacaine Group. It was found to be about two folds longer in Levobupivacaine + Buprenorphine group. **Behr Aet al**, **Dixit et al**, **Sarkar D et al**, **Thakur D et al**, **Vadhanan P et al** and **Sanghvi KS et al** were also found the similar result to our study. Buprenorphine has consistently been used to provide a longer duration of post operative analgesia as evidenced by various studies. Thus, it obviates the need for other systemic analgesics thereby avoiding their side effects and post operative sedation.

### Conclusion

It is concluded that in this randomized, single-blinded study the demographic parameters like age, height, and weight were comparable between groups. Addition of Buprenorphine makes sensory and motor onset earlier than plain Levobupivacaine 0.5%. The duration of sensory and motor block was significantly longer in the

buprenorphine group than in the control group. The duration of analgesia was significantly longer with Buprenorphine as an Adjuvant to Levobupivacaine. It was concluded that the addition of 150µg (0.5 ml.) of Buprenorphine to 0.5% Levobupivacaine effectively and safely shortens the onset of sensory and motor blockade, increases the duration of sensory and motor blockade and increases the duration of analgesia without any hemodynamic disturbances.

### References:

1. Admir Hadzic, Jerry Vloka. Peripheral nerve blocks: Principles and Practice. New York School of Regional Anesthesia 2004; 4(340).
2. Hirschel G. Die Anaesthesierung des Plexus Brachialis fuer die Operationen der oberen Extremitaet. Muenchen Med Wochenschr1911; 58.
3. Kulenkampff D (1911). "Zuranesthesierung des plexus brachialis" [On anesthesia of brachial plexus]. 1911; 38: 1337–40.
4. Lund PC, Cwik JC, Vallesteros F. Bupivacaine- a new long-acting local anesthetic agent. A preliminary clinical and laboratory report. Anesth Analg 1970; 49:103-104.
5. Miller R, Cohen N, Eriksson L, Fleisher L, Wiener-Kronish J, Young W. Miller's anesthesia. 8th ed. 2015. p. 1697
6. Stoelting RK, Hillier SC. Pharmacology and physiology in anesthetic practice. Lippincott Williams & Wilkins; 2012 Jan 11. p. 243
7. Marhofer P, Griffiths W. H. Nerve location in regional anaesthesia: finding what lies beneath the skin. Br J Anaesth, 2011; 106(1): 3–5.
8. Winnie AP: Plexus Anesthesia—Perivascular Techniques of Brachial Plexus Block. Philadelphia, WB Saunders; 1983: 68.
9. El Saied AH, Steyn MP, Ansermino JM. Clonidine prolongs the effect of

- ropivacaine for axillary brachial plexus blockade. *Can J Anaesth* 2000 Oct;47(10):962-7
10. Patrick J. Technique of brachial plexus block anaesthesia. *Br J Surg*, 1940;27: 734.
11. Popping DM, Elia N, Marret E, Wenk M; Clonidine as an adjuvant to Local Anaesthetics for Peripheral nerve and Plexus Blocks, A Metaanalysis of Randomised Trials. *Anesthesiology*, 2009;111:406-415
12. Murphy DB et al. Noval analgesia adjuncts for brachial plexus block. A systemic review. *Anaesth Analg* 2000;2000;1122-1128.
13. David Johnson, Harold Ellis. Pectoral girdle and upper limb. in: Gray's-The anatomical basis of clinical practice. 38th edn. Churchill Livingstone; 1999. 801-941.
14. Collins Vincent J. Editor. Principles of Anaesthesiology. 3rd ed. Philadelphia; Lea and Febiger; 1993.
15. Martin Berry, Lawrence H. Bemnister Susan M. Standing "Nervous System". chapter-8, Gray's Anatomy, 38th Edn, 1995; 901-1397.
16. Neal JM, Gerancher JC, Hebl JR, Ilfeld BM, McCartney CJ, Franco CD, Hogan QH. Upper extremity regional anesthesia. *Reg Anesth Pain Med* 2009; 34(2)(Mar-Apr): 134-170.
17. Stein C. Peripheral mechanisms of opioid analgesia. *Anesth Analg*. 1993;76:182-91.
18. Fields HL, Emson PC, Leigh BK, Gilbert RF, Iversen LL. Multiple opiate receptor sites on primary afferent fibres. *Nature*. 1980;284:351-3.
19. Candido KD, Winnie AP, Ghaleb AH, Fattouh MW, Franco CD. Buprenorphine added to the local anesthetic for axillary brachial plexus block prolongs postoperative analgesia. *Reg Anesth Pain Med*. 2002;27:162-7.
20. Jadon A, Panigrahi MR, Parida SS, Chakraborty S, Agrawal PS, Panda A. Buprenorphine improves the efficacy of bupivacaine in nerve plexus block: A double blind randomized evaluation in subclavian perivascular brachial block. *J Anaesth Clin Pharmacol*. 2009 Apr 1;25(2):207-10.
21. Sarkar D, Khurana G, Chaudhary A, Sharma JP. A comparative study on the effects of adding fentanyl and buprenorphine to local anaesthetics in brachial plexus block. *J Clin Diagn Res*. 2010;4:3337-43.
22. Brummett CM, Williams BA. Additives to local anesthetics for peripheral nerve blockade. *International anesthesiology clinics*. 2011;49(4):104.
23. Singam A, Chaudhari A, Nagrale M. Buprenorphine as an adjuvant in supraclavicular brachial plexus block. *Int J Biomed Adv Res*. 2012;03:571-5.
24. Behr A, Freo U, Ori C, Westermann B, Alemanno F. Buprenorphine added to levobupivacaine enhances postoperative analgesia of middle interscalene brachial plexus block. *J Anesth*. 2012;26:746-51.
25. Sanghvi KS, Shah VA, Patel KD. Comparative study of bupivacaine alone and bupivacaine along with buprenorphine in axillary brachial plexus block: A prospective, randomized, single blind study. *Int J Basic Clin Pharmacol*. 2013;02:640-4.
26. Dixit R, Chakole V, Tadwalkar G. Effect of buprenorphine on post operative analgesia in supraclavicular brachial plexus block using peripheral nerve locator. *J Evol Med Dent Sci*. 2013;2:114.
27. Patil S, Debata D, Doshi C, Vyas V, Sinha S. Effect of buprenorphine as an adjunct with plain local anesthetic solution in supraclavicular brachial plexus block on quality and duration of postoperative analgesia. *Journal of anaesthesiology*,



- clinical pharmacology. 2015 Oct;31(4):496.
28. Thakur D, Malde A. Buprenorphine for postoperative analgesia: Axillary brachial plexus block versus intramuscular administration in a placebo-controlled trial. *J Anaesthesiol Clin Pharmacol* [serial online] 2015 [cited 2020 Sep 7];31:360-4.
29. Schnabel A, Reichl SU, Zahn PK, Pogatzki-Zahn EM, Meyer-Frießem CH. Efficacy and safety of buprenorphine in peripheral nerve blocks: a meta-analysis of randomised controlled trials. *European Journal of Anaesthesiology (EJA)*. 2017 Sep 1;34(9):576-86.
30. Jain N, Khare A, Khandelwal S, Mathur P, Singh M, Mathur V. Buprenorphine as an adjuvant to 0.5% ropivacaine for ultrasound-guided supraclavicular brachial plexus block: A randomized, double-blind, prospective study. *Indian Journal of Pain*. 2017 May 1;31(2):112.
31. Vadhanan P, Ganesh N, Ahmed MH. Comparison of dexamethasone and buprenorphine as adjuvant in ultrasound-guided brachial plexus blocks: A randomized controlled trial. *Anesthesia, essays and researches*. 2018 Jan;12(1):176.
32. Priyanka GG, Basha SKF. Buprenorphine with Local Anaesthetic Combination in Supraclavicular Brachial Plexus Block Produced Prolonged Post-operative Analgesia Compared to Butorphanol with Local anaesthetic: A Prospective, Randomized, Comparative Study. *Int J Sci Stud* 2019;7(6):45-49.