



## Non-operative management in blunt splenic injury

Authors

Arvind Anchawle<sup>1</sup>, Ashish Naik<sup>2</sup>, Rahul Muske<sup>3</sup>, Ritesh Dhanbhar<sup>4\*</sup>

\*Corresponding Author

Dr Ritesh Dhanbhar

### Abstract

**Introduction:** Conservative management of splenic injury had a great success rate in past decade. Newer imaging modalities have helped in improving its outcome by refining designs. There is need of study for safety and efficacy of conservatively managed splenic injuries.

**Aim:** Study on outcome of Conservative management of splenic injuries at tertiary care hospital.

**Methods:** Retrospective study was carried out at DVVPF'S Medical College and Hospital, Ahmednagar; from October 2017 To April 2019. In this study 30 patient with splenic injury were included.

**Results:** Out of 30 cases of splenic injury, we were successfully managed 7 cases conservatively. None of the cases in our study, in which we had decided for conservative management, were subjected to an exploratory laparotomy.

**Conclusion:** Patients which are hemodynamically stable and has Grade I or Grade II injuries according to the AAST classification must be tried for Conservative management.

### Introduction

The risk of overwhelming post splenectomy infection (OPSI) prompted need for preservation of injured spleen. Non operative management of blunt injury of spleen in adults is becoming the standard of treatment for hemodynamically stable patients.<sup>[1]</sup> Billroth suggested over 100 years ago that the injured spleen has the ability of self-healing<sup>[2]</sup> This major therapeutic change was consequence of many clinical studies indicating that splenectomy increases the risk of overwhelming post splenectomy sepsis, which appears in 0.5% of all splenectomies in trauma patients and in over 20% of elective splenectomies for hematologic disorders<sup>[3]</sup>. OPSI is most frequent during the first 2 years of asplenia but there is a permanent risk of infection with a mortality of over 80%. Non operative management ranges from observation

and monitoring alone to angiography/angio embolization (AG/AE) with the aim to preserve the spleen and its function, especially in children. These considerations were carried out considering the immunological function of the spleen and the high risk of immunological impairment in splenectomised patients In this study we will try to understand how far can we conserve the spleen in a patient subjected to a blunt trauma by availability of newer diagnostic modalities such as USG, CT scan and clinical assessment of the patient.

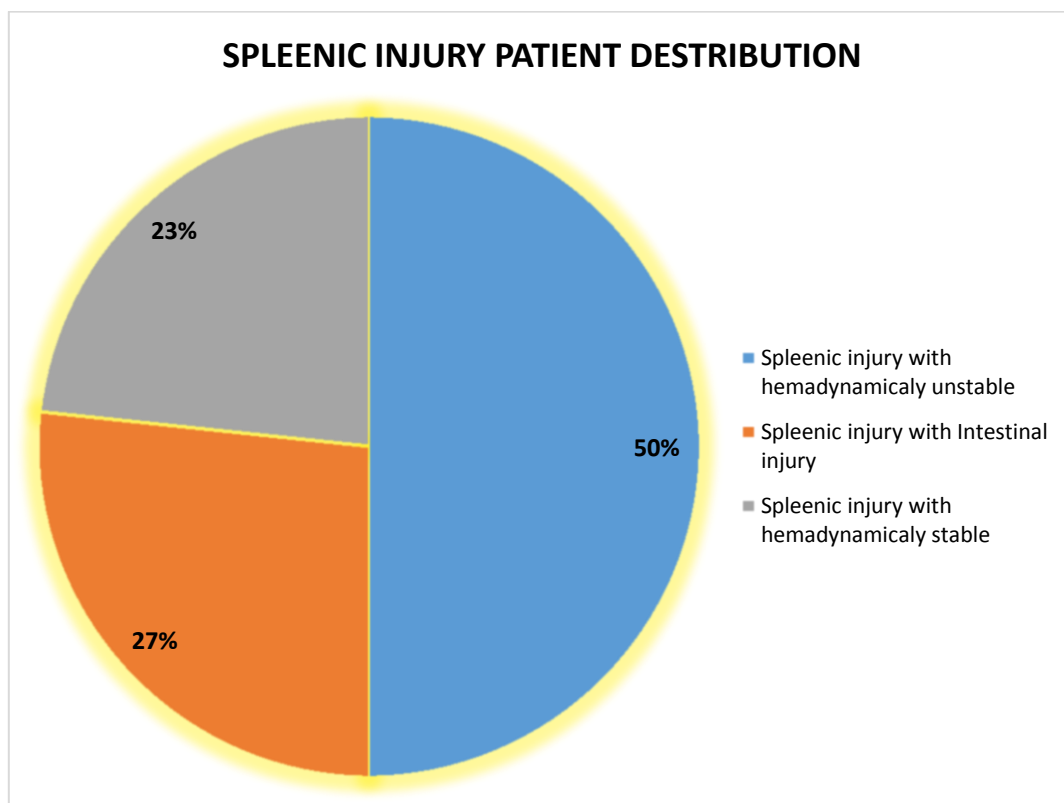
### Materials and Methods

Retrospective study was carried out at DVVPF'S Medical College and Hospital, Ahmednagar; from October 2017 To April 2019. In this study 30 patient with splenic injury were included. All of them had history of some kind of blunt trauma to

the abdomen. The grade of injury varied from Grade I to Grade V according to the ASII classification. Management of all the patients admitted with blunt injury to the abdomen and suspected splenic injury were investigated in our hospital with USG, Haemogram, X Ray chest, and if necessary CT abdomen was also utilized. If the USG showed any splenic injury, then only CT abdomen was used for further evaluation. In other cases, usually monitoring of the patient was done with daily USG examination and repeated haemograms. All the patients were admitted in the Surgical ICU for the purpose of haemodynamic monitoring.

### Results

Out of the 30 cases that were treated, 15 of them were taken immediately for splenectomy as haemoperitoneum was more than 1L and despite blood transfusion of 2 unit of PCV at the time of admission, the haemoglobin had dropped down. Along with splenic injury, 8 patient also had an associated mesenteric and bowel injury, therefore in these patient were subjected to laparotomy. We were successfully managed 7 cases conservatively. None of the cases in our study, in which we had decided for conservative management, were subjected to an exploratory laparotomy.



### Discussion

This study showed that 23.3% of splenic injury cases were successfully managed by conservative line of treatment.

Meguid et al study reported that the percentage of non-operative management since the original report has increased to 69% from an initial 36%, which reflects acceptance of non-operative treatment.<sup>[4]</sup>

The increased diagnostic accuracy of splenic injury by CT scanning and the early recognition of early postoperative and late septic complications in the splenic patient has altered the treatment.<sup>[5,6,7]</sup>

Treatment varies from institution to institution but usually includes patients with stable hemodynamic signs, stable haemoglobin levels over 12-48 hours, minimal transfusion requirements (up to 2 unit PCV), CT scan injury and patients younger than 55 years.<sup>[8]</sup>

Another study that supports the success of non operative management of splenic injury in this age group is Cocanour's retrospective review of 375 patients over a five-year period.<sup>[9]</sup> Of those patients, 29 were >55 years of age and they had higher Injury Severity Scores (ISS) and mortality rates (ISS, 29.3±2.6 vs. 19.5±2.1; mortality: 67% vs. 4%) than those patients who were <55 years of age. Although mortality rates were higher in the older patients, no deaths were attributed to the splenic injury. The authors concluded that although the older adults had more severe injuries, they had similar failure rates of non operative management compared with those of younger adults and the splenic injuries were not the direct causes of the mortalities, non operative management should not be contraindicated in this group.

A total of 1,488 adults (>15 years of age) with blunt splenic injury from 27 trauma centres in 1997 were studied through the Multi Institutional Trials Committee of the Eastern Association for the Surgery of Trauma by Peitzman et al, found that 54.8% of patients were successfully managed non operatively. In this study the failure rate of planned observation was 10.8%, with 60.9% of failures occurred within 24 hours. Successful non operative management was associated with higher Blood Pressure and Haemoglobin and had less severe injury based on ISS, Glasgow Coma Scale, grade of splenic injury, and quantity of hemoperitoneum.<sup>[10]</sup>

Non-operative management in splenic injuries is contraindicated in the setting of unresponsive hemodynamic instability or other indicates for laparotomy (peritonitis, hollow organ injuries, bowel evisceration, impalement<sup>[11]</sup>

Blunt splenic injury occurred in 23 patients age 55 years or older. Eighteen patients (78%) were selected for Non-operative management and 17 patients (94%) were successfully treated without operation.<sup>[12]</sup>

### Conclusion

The management of splenic injuries has evolved due to various advancements in the field of surgery

and interventional radio diagnostics. With properly defined criteria and accurate selection of patients, NOM of splenic injuries is appropriate. In Patients below 55 years of age and who are hemodynamically stable, with Grade I or Grade II injuries according to the AAST classification must be tried for Conservative management. With the help of newer diagnostic methods and imaging studies, removal of spleen can be avoided. Understanding that, Spleen helps in the immunological defence against encapsulated organisms this also prevents the risk of OPSI although rare, it is associated with a high mortality.

### References

1. Beuran M et al. Non-operative management of splenic trauma. *Journal of Medicine and Life* 2012; 5(1):47- 58.
2. Lucas CE. Splenic Trauma Choice of Management. *Ann. Surg.* 1991; 213: 98–112.
3. Uranüs S, Pfeifer J. Nonoperative management of blunt splenic injury. *World J. Surg.* 2001;25:1405–1407.
4. Meguid AA, Bair HA, Howells GA, Bendick PJ, Kerr HH, Villalba MR. Prospective evaluation of criteria for the nonoperative management of blunt splenic trauma. *Am Surg.* 2003;69(3): 238-42.
5. Stassen NA, Bhullar I, Cheng JD, Crandall ML, Friese RS, Guillamondegui OD, et al. Selective nonoperative management of blunt splenic injury: an Eastern Association for the Surgery of Trauma practice management guideline. *J Trauma Acute Care Surg.* 2012;73:5:4:294-300.
6. Zarzaur BL, Kozar RA, Fabian TC, Coimbra R. A survey of American Association for the Surgery of Trauma member practices in the management of blunt splenic injury. *J Trauma.* 2011;70(5):1026-31
7. Bhullar IS, Frykberg ER, Tepas JJ 3rd, Siragusa D, Loper T, Kerwin AJ. At first blush: absence of computed tomography

contrast extravasation in Grade IV or V adult blunt splenic trauma should not preclude angioembolization. *J Trauma Acute Care Surg.* 2013;74(1): 105-11.

8. H Scott Bjerke. Medscape. Article 432823 (<https://emedicine.medscape.com/article/432823-treatment>)
9. Cocanour CS, Moore FA , Ware DN , Marvin RG , Clark JM , Duke JH . Delayed complications of nonoperative management of blunt adult splenictrauma. *Arch Surg* 1998;133:619–25.
10. Peitzman, Andrew B, et al. Blunt splenic injury in adults: Multi-institutional study of the Eastern Association for the Surgery of Trauma. In: *Journal of Trauma - Injury, Infection and Critical Care.* 2000;49:2: 177-189.
11. Federico Coccolini, et al. *World Journal of Emergency Surgery.* 2017;12:40.
12. Myers JG, et al. Blunt splenic injuries: dedicated trauma surgeons can achieve a high rate of nonoperative success in patients of all ages. *J Trauma.* 2000; 48:5:801-5.

### **Abbreviation**

NOM- Non operative management.

OPSI- Overwhelming post splenectomy infection.