



A Descriptive Analysis of Traumatic Knee Injury at Tertiary Care Level

Authors

Bala Bharathi¹, Amarnath², Kurinjiselvan³

¹Post Graduate, ^{2,3}Assistant Professor

Department of Radiodiagnosis, Rajah Muthiah Medical College and Hospital, Chidambaram

Abstract

Knee joint is commonest joint involved in external injuries. MRI is a non-invasive modality that possesses higher diagnostic accuracy and better sensitivity. The results of this present study support that MRI can be very helpful in diagnosing the cruciate and meniscal ligament injuries. It can accurately detect, localize and distinguish various internal derangements of the knee joint with excellent soft tissue delineation and help in arriving at an accurate anatomical diagnosis thereby helping further management of the patients. It avoids unnecessary invasive procedure like arthroscopy and helps in managing cases appropriately. We conducted retrospective study on 120 patients having prior history of knee trauma. Our study focus early detection of various soft tissue injuries of knee and microtrabecular fracture that cannot be detected by plain film. Early detection prevent further degeneration.

Keywords: Painful Knee, MRI, ligament injuries, chondromalacia patella, bone marrow contusion, joint effusion.

Introduction

Most commonly involved joint in external injury is knee joint. It has ligamentous and meniscal structure that plays an important role in stability and mobility⁽¹⁾. Common cause of morbidity in active young individuals is internal derangement of knee joint⁽²⁾. The most widely used investigations are arthroscopy and MRI⁽³⁾. Arthroscopy is the gold standard technique in diagnosing intra articular knee lesion. It is now widely replaced by MRI, as arthroscopy is an invasive procedure and associated with complication⁽⁴⁾. MRI is a non invasive technique for early detection of ligamentous and cartilage abnormality because of its better soft tissue contrast and multi planar imaging capabilities. Early detection prevent further degeneration.

Aim

The purpose of this study is to detect meniscal, ligament, cartilage, microtubular fractures in traumatic knee injury which cannot be detected by plain film.

Material and Methods

A total number of 120 patients referred with history of knee injury were imaged with 1.5 Tesla Siemen MRI machine in the department of radiodiagnosis, Rajah Muthiah Medical College and Hospital, Chidambaram over a period of 12 months. Fast spin-echo (FSE) imaging in conjunction with fat suppression (FS) MR techniques and PD sequence, were used which extended the sensitivity and specificity of MR in the detection of articular cartilage and ligament injuries.

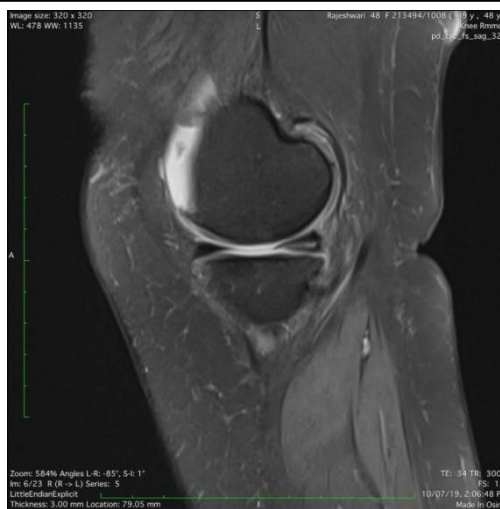

Fig 1: PD sagittal fs - Longitudinal tear in posterior horn of medial meniscus

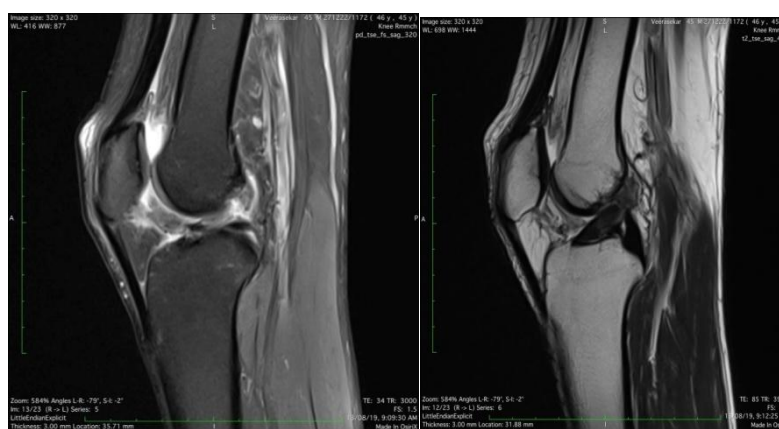

Figure 2, 3. Sagittal PD and T2 fs images with grade III tear of anterior cruciate ligament at femoral attachment site, minimal joint effusion and soft tissue injury in anterior aspect of knee joint.

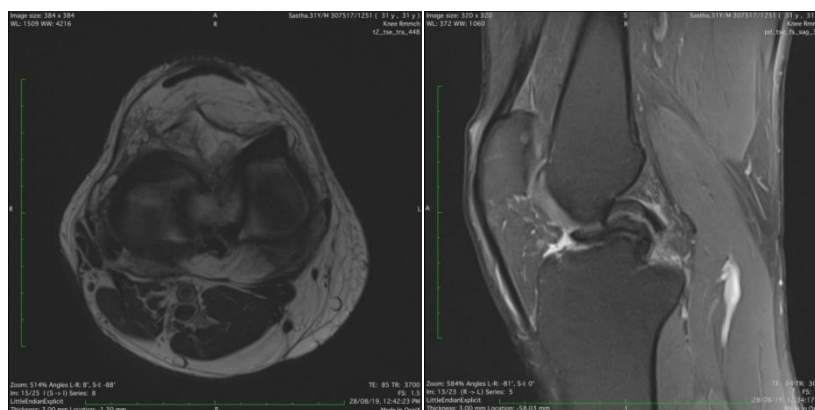


Figure 4, 5 T2 axial and PD sagittal fs images- Bucket handle tear of medial meniscus with double PCL sign.

Results

The sample population comprised of 120 outpatients with knee joint pain or swelling. Their ages ranged between 16 to 50 years, the peak age was 20 to 29 years representing Males (74.2%) while (25.8%) were females. Anterior cruciate

injury is the commonest followed by medial meniscus injury in which posterior horn is frequently affected, followed by lateral meniscus, medial patello femoral ligament, medial collateral ligament, lateral collateral ligament, posterior cruciate ligament and least commonly lateral

patella femoral ligament. Anterior cruciate ligament injury seen in 79 patient (65.8%) and was complete in 36 patients (45.5%), partial in 24 patients (30.3 %), medial meniscal injury was detected in 78 patients (65%), lateral meniscal lesions in 44 (36.6 %) medial collateral ligament in 22 (18.3 %), lateral collateral ligament in 19

patient(15.8%), posterior cruciate in 18(15%), medial patello femoral ligament in 32 patients (26.6%), lateral patello femoral ligament in 12 patients (10%), joint effusion in 76 (63.3%), bone marrow edema 50 (41.6%), osteoarthritis 21(17.5%), Baker cyst were diagnosed in 7 patients (5.8%).

Table 1: Distribution according to Age

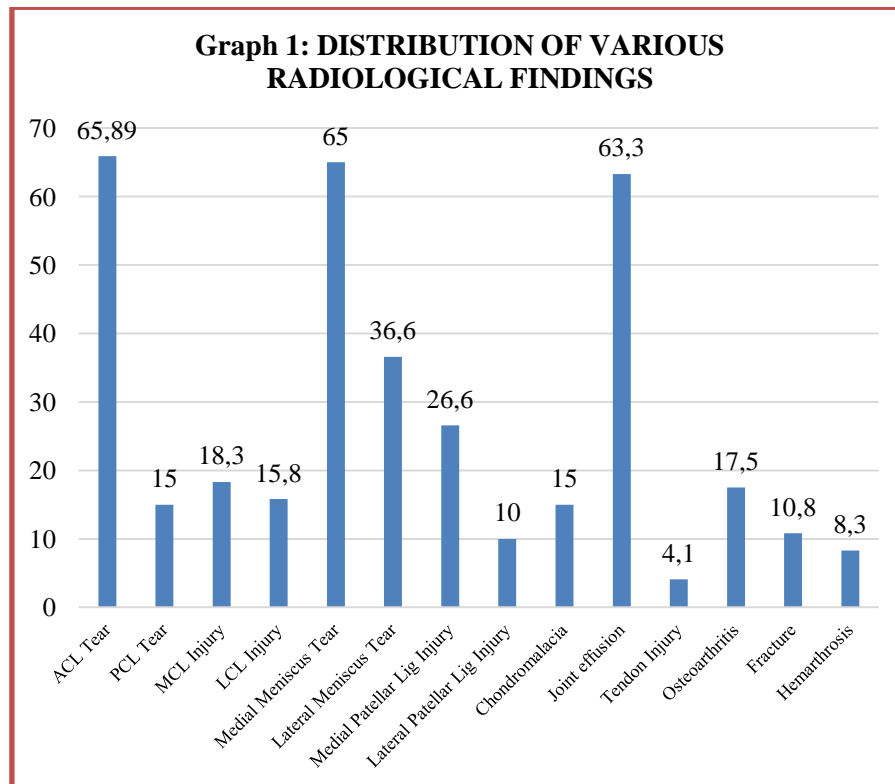
| Age Group | Frequency (n120) | Percentage % |
|--------------|------------------|--------------|
| Less than 20 | 8 | 6.6% |
| 21-30 | 40 | 33.3% |
| 31-40 | 31 | 25.8% |
| 41-50 | 25 | 20.8% |
| 51-60 | 12 | 10% |
| More than 60 | 4 | 3.3% |

Table 2: Distribution of total cases

| S. No | Radiological findings | Cases (out of 120) | Percentage |
|-------|---|--------------------|------------|
| 1 | ACL Tear | 79 | 65.8% |
| 2 | PCL Tear | 18 | 15% |
| 3 | MCL injury | 22 | 18.3% |
| 4 | LCL injury | 19 | 15.8% |
| 5 | Medial Meniscus Tear | 78 | 65% |
| 6 | Lateral Meniscus Tear | 44 | 36.6% |
| 7 | Medial patello femoral ligament injury | 32 | 26.6% |
| 8 | Lateral patello femoral ligament injury | 12 | 10% |
| 9 | Chondromalacia | 18 | 15% |
| 10 | Bone marrow contusion | 50 | 41.6% |
| 11 | Joint Effusion | 76 | 63.3% |
| 12 | Osteoarthritis | 21 | 17.5% |
| 13 | Hemarthrosis | 10 | 8.3% |
| 14 | Tendon injury | 5 | 4.1% |
| 15 | Fractures | 13 | 10.8% |

Table 3: MRI Findings of ACL Injuries

| Anterior Cruciate Ligament (ACL) Tear | | |
|---------------------------------------|-------------------------|------------|
| Results | Number of patients (79) | Percentage |
| Complete | 36 | 45.5% |
| partial | 43 | 54.5% |
| Location of ACL Tear | | |
| Tibial attachment | 21 | 26.6% |
| Femoral attachment | 52 | 65.8% |
| Mid substance | 6 | 7.6% |



Discussion

The knee is an anatomically and biomechanically complex joint. The most common indication of performing a knee MRI is to diagnose internal derangements in an injured knee. Mostly clinical presentation in diagnosis in most of the cases of acute knee injury and is inconclusive in cases with injuries of multiple ligaments/menisci, which corresponded with study done by Li DK et al⁽⁵⁾. A lot of surgeons tend to suppose that MRI is an accurate, non-invasive diagnostic method of the knee injuries, adequate to lead to decisions for conservative treatment and save patient from unnecessary arthroscopy (Major et al.2003 and Zhang et al⁽⁶⁾). The common MRI planes used in hospitals include the axial, coronal, and sagittal planes. The ACL and PCL sections are viewed as hypointense bands on T1W, T2W, and Short Tau Inversion Recovery Images (Chaudhuri *et al.*, 2013)⁽⁷⁾. Therefore, any injuries will be seen as a hyperintense form on T2W, as well as Short Tau Inversion. In a similar manner, the meniscus of the knee is observed as a hypointense structure in T1W, TW2, and Short Tau Inversion Recovery images. Also, injuries to the meniscuses are seen as a hyperintense characteristic on T2W and Short

Tau Inversion Recovery images. The above type of lesion may show itself as incomplete or complete for the tear of the knee features (Sellam, & Berenbaum, 2010)⁽⁸⁾ Most patients with chondromalacia patellae have focal increased signal in the cartilage or focal contour defects in the cartilage surface on T2-weighted MR images^[9]. In our study, there was a total of 120 study participants. The study consisted majority (74.2%) of the male participants and (25.8%) patients were female with male female ratio 3:1. This concludes that most of the male subjects were more vulnerable to bone injuries because of accidents, industrial injury⁽¹⁰⁾. The affected patients age ranges between 20 -50 years and most commonly affected were between 20-29 years. The age distribution pattern observed in the present study was comparable to the study of D S Shetty et al in which commonest age group was 21 to 30 years for both male and female. Commonest injury is Anterior cruciate ligament in 79 patient (65.8%) and was complete in 36 patients (45.5%), partial in 24 patients (30.3%), followed by medial meniscal lesions was detected in 78 patients (65%), lateral meniscal lesions in 44 (36.6%) medial collateral ligament in 22(18.3

%), lateral collateral ligament in 19 patient (15.8%), posterior cruciate in 18(15%), medial patello femoral ligament in 32 patients(26.6%), lateral patello femoral ligament in 12 patients (10%), joint effusion in 76 (63.3%), bone marrow edema in 50 (41.6 %), osteoarthritis in 21(17.5%), Baker cyst were diagnosed in 7 patients (5.8%), chondromalacia in 18 (15%) and tendon tear in 5 (4.1%). In medial meniscal injury, posterior horn is commonly injured. Singh et al also found that commonest meniscal injury is posterior horn of medial meniscus. Horizontal tear was commonest (41%) followed by radial tear (21.7%), longitudinal tear (15.3%), oblique tear(15.3%) complex tear (8.9%) and bucket handle tear (3.8%) in medial meniscus. Commonest type of tear in lateral meniscus was horizontal tear (40%) followed by vertical radial tear (20.4%) complex tear (18.1%), longitudinal tear (11.3 %), and oblique tear (11.3%). Bone contusion was commonly associated with ACL injury (76%), followed by medial meniscus injury (66%), lateral meniscus injury(34%) and 22% with PCL injury. One patient had complete PCL tear. Therefore, the use of MRI can help in the identification of the exact cause of the pain and inform proper treatment plans (Roemer *et al.*, 2011)⁽¹¹⁾. It is the best's modality for investigating or diagnosing complete ACL (Yadav, & Kachewar, 2014)⁽¹²⁾.

Conclusion

There are many causes of traumatic knee pain. Correct treatment can be given if exact and correct diagnosis is made. MRI of the knee is the excellent non invasive technique for knee injury. Because of its excellent contrast resolution and multiplanar imaging capabilities various soft tissue injuries of knee joint can be fully evaluated as arthroscopy may not be useful for the inferior surface and peripheral meniscus tears. Commonest injuries detected in our study are anterior cruciate ligament tear, tear of posterior horn of medial meniscus.

References

1. Sanches Vaz CE, Pires De Camargo O, José De Santana P, Valezi AC. Accuracy of magnetic resonance in identifying traumatic intraarticular knee lesions. *Clinics*. 2005; 60(6):445–50.
2. Akisue T, Kurosaka M, Yoshiya S. Evaluation of healing of the injured posterior Cruciate Ligament: analysis of Instability and Magnetic Resonance Imaging. *Arthroscopy*, 2001; 17(3): 264–269.
3. Andrew H Sonin, Fitzgerald SW, Friedman H, et al. PCL injury: MRI diagnosis and pattern of injury. *Radiology*, 1994; 167: 121- 12.
4. Arumugam V, Ganesan GR, Natarajan P. MRI Evaluation of Acute Internal Derangement of Knee. *Open Journal of Radiology*, 2015 May 26; 5(02): 66.
5. Li DK, Adams ME, McConkey JP. Magnetic resonance imaging of the ligaments and menisci of the knee. *Radiologic clinics of North America*. 1986;24(2):209– 27.
6. Major MM, Beard LN, Helms CA. (2003): Accuracy of MRI of knee in adolescent. *AJR. Am J Roentgenol*; 180:17–9.
7. Chaudhuri S, Joshi P, Goel M, No RH, Ramnagari A. Role of MRI in the evaluation of traumatic knee injuries. *Journal of Evolution of Medical and Dental Sciences*. 2013; 2(7):765-772.
8. Sellam J, Berenbaum F. The role of synovitis in pathophysiology and clinical symptoms of osteoarthritis. *Nature Reviews Rheumatology*. 2010; 6(11):625.
9. Thomas R. McCauley¹, Ruben Kier¹, Kevin J. Lynch², Peter Jokl². Chondromalacia Patellae: Diagnosis with MR Imaging. *AJR* 158:101-105, January 1992.
10. Khan Z, Faruqi Z, Oguynbiyi O, Rosset G, Iqbal J. Ultrasound assessment of internal derangement of the knee. *Acta Orthopaedica Belg.*, 2006; 72: 72-6.
11. Roemer FW, Guermazi A, Felson DT, Niu J, Nevitt MC, Crema MD, *et al.* Presence of MRI-detected joint effusion and synovitis

increases the risk of cartilage loss in knees without osteoarthritis at 30-month follow-up: the MOST study. *Annals of the rheumatic diseases*, 2011, 150243.

12. Yadav R, Kachewar SG. Role of MRI in the evaluation of painful knee. *International Journal of Medical Research and Health Sciences*. 2014; 3(1):84-87.