



## Morphological Study on the Synostosis of First and Second Rib

Authors

**Dr K. Pushpakala<sup>1</sup>, Dr G.B. Lakshmi Gayathri<sup>2\*</sup>**

<sup>1,2</sup>Assistant Professor, MD Anatomy, Institute of Anatomy, Madurai Medical College

\*Corresponding Author

**Dr G.B. Lakshmi Gayathri**

Assistant Professor, MD Anatomy, Institute of Anatomy, Madurai Medical College

### Introduction

A rib is a highly vascular cancellous bone enclosed in a thin layer of compact bone, which are thicker on its surfaces and thinner in its borders. There are twelve pairs of bony arches which form the osseous framework of thorax, and articulates with the vertebral column posteriorly<sup>(15)</sup>. The twelve pairs of ribs develops in the ninth week of intrauterine life, from the costal processes of the thoracic vertebrae<sup>(11)</sup>. Congenital anomalies of the ribs are very rare. An unusual anomaly of the fusion of first and second ribs i.e., Synostosis or the bicipital ribs had been said to have an incidence of 0.3%, as reported from a study based on chest radiographs<sup>(7)</sup>.

Synostosis of the first rib is a rare anatomical peculiarity which occurs due to fusion of the shafts of these distinct ribs, mostly happening in relation to first rib as, fusion of the first rib with the cervical rib or as its fusion with the second rib<sup>(18)</sup>. Rib anomalies like forked ribs or fused ribs involving first rib mainly result from the misexpression of specific Hox 3 genes<sup>(5)</sup>.

The synostosis of the first and second ribs is usually asymptomatic, but may also cause musculoskeletal pain, intercostal nerve entrapment or any significant vascular pathology. Since the first rib is involved, the bicipital rib may be a rare

cause of thoracic outlet syndrome. Such an anomaly may be associated with many syndromes like Klippell-Feil syndrome, Poland syndrome, Neurofibromatosis, Spondylocostal dysostosis etc<sup>(21)</sup>.

In this paper we report a case of bicipital rib, and by presenting this, we attempt to highlight on the evolution, morphological implications and clinical significance of the bicipital rib. The knowledge of its prevalence is essential for the Anatomists from academic point of view and also important for Clinicians, Surgeons and Radiologists for early diagnosis and surgical intervention.

### Materials and Methods

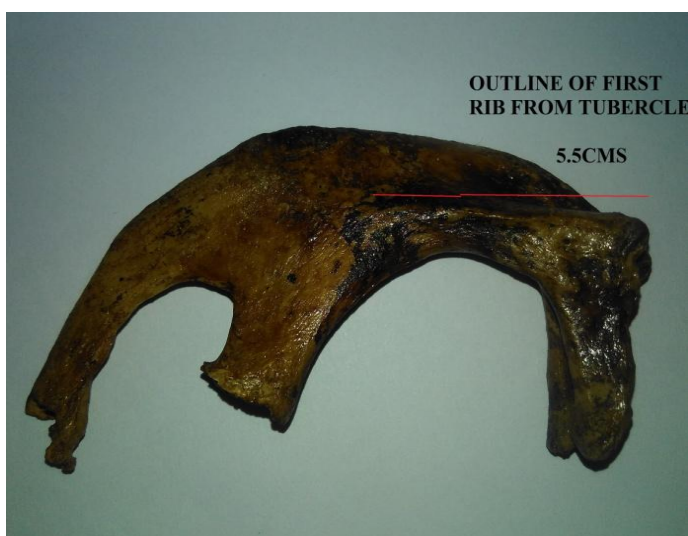The morphological pattern of the fusion of first and second ribs were studied in about 100 thoracic cage skeletons, from the osteology lab of the Institute of Anatomy of Madurai Medical college. The anomaly of the synostosis of the first and second rib, was obtained on the right side of only one thoracic cage skeleton, where the other side revealed normal first and second ribs. The line of fusion in the observed specimen was very obvious and prominent. The specimen was well examined, photographed and relevant anatomic features and measurements were recorded.

### Observations and Results

The morphometric analysis of the specimen revealed the fusion of the first and second ribs from a point 2.5cms beyond the tubercle of the first rib (fig-1). Fusion was found to be from above downwards, as if they were overlapping. First rib outline was visible 5.5cms from the tubercle (fig- 2). Fusion of the two ribs has took place along the outer border of the shaft of the first rib and the inner border of the shaft of the second rib, so that they had formed a large plate of bone gradually spreading in width with a maximum of 5.25cms and resulting in the obliteration of three- fourth of the first intercostals space (fig- 3).

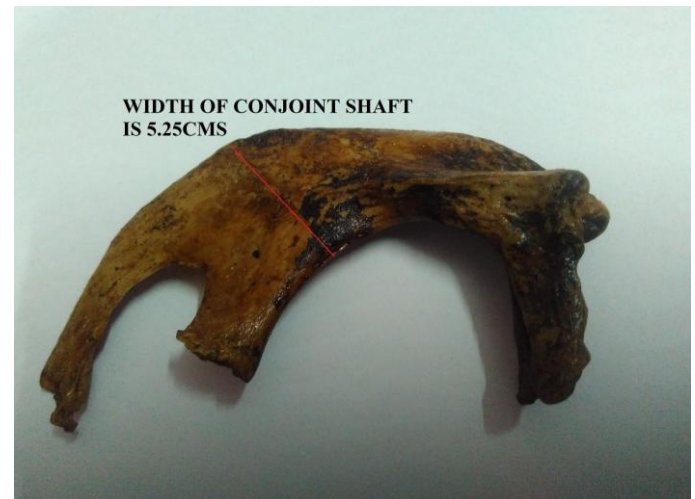

**Fig – 1** showing conjoint first and second ribs with the fusion occurring 2.5cms from the tubercle of the first rib.



**Fig – 2** showing the clear outline of the outer border of first rib of about 5.5cms from its tubercle.

Costal ends of both the ribs were found to be separate. Impression of scalenus medius was present over the superior surface of the first rib and scalene tubercle was made out in the inner border of the first rib with serratus anterior tuberosity on the outer border of second rib. (fig- 4).

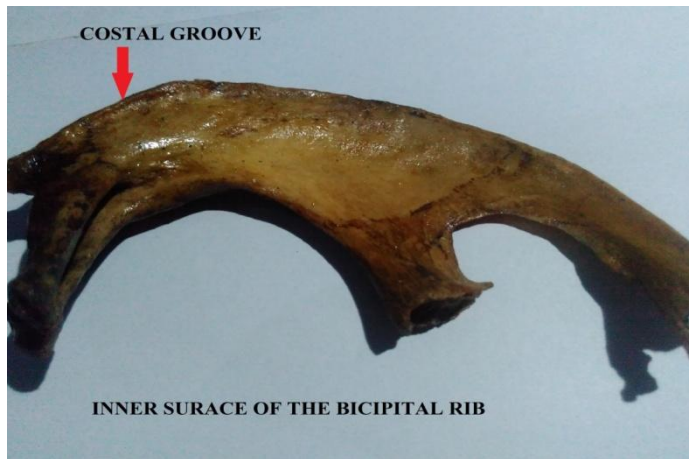

**Fig – 3** showing the maximum width of conjoint shaft of about 5.25cms.

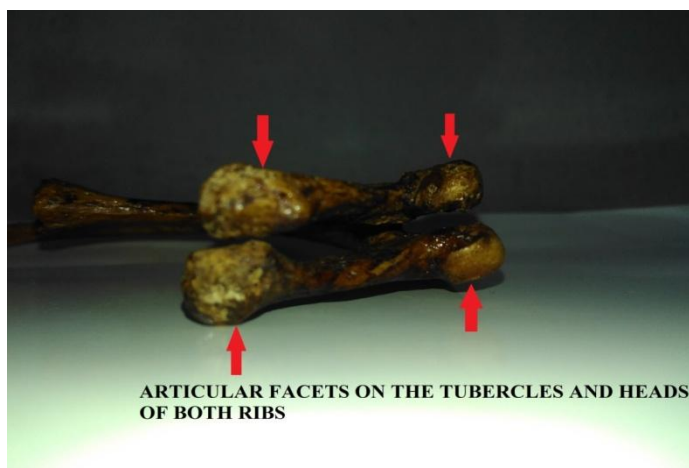


**Fig – 4** showing the scalene tubercle and serratus anterior tuberosity on the outer border of second rib.

The posterior part of the inner surface of the second rib had a costal groove (fig- 5). Single rounded articular facets were seen on the heads and tubercles of the upper and lower fragments of the conjoint ribs (fig- 6).



**Fig – 5** shows the costal groove in the posterior end of second rib in the undersurface of the bicipital rib.



**Fig - 6**

### Discussion

Ribs are developed from the mesenchymal processes of the primitive vertebral arches in the thoracic region. Any malsegmentation of the axial skeleton during the 20<sup>th</sup> day of intrauterine life may lead to multiple anomalies of the vertebrae and ribs<sup>(9)</sup>. Anita<sup>(1)</sup> mentions that mal-expression of some of the myogenic determination factors like MyoD, Myogenin, Myf5 and MRF4 could be the potential cause of these anomalies which were detected in the medial half of somites prior to the myotome formation.

The various developmental anomalies of the first rib includes a) floating ribs, b) central defects due to the bridging of ligamentous bands, c) synostosis with the second rib, d) bifurcated or bifid rib etc<sup>(20)</sup>. Among this, the bicipital rib or the

synostosis anomaly occurs when a cervical rib fuses with vertebral end of the first rib or if the first rib becomes rudimentary and fuses with the second rib<sup>(16)</sup>. Contrarily in the present case, the first rib appeared to be of normal caliber and was not found to be rudimentary.

Rib anomalies may be associated with the variations in the disposition of the vessels and nerves<sup>(17)</sup>. First rib synostosis anomalies may cause compression of the Brachial plexus and the Subclavian artery, when they pass through the narrow space created by it<sup>(3)</sup>. Also in such anomalies, the first and the second thoracic nerves will get stretched upon the shaft of the fused rib causing the neurological symptoms of thoracic outlet syndrome<sup>(6)</sup>. This congenital anomaly of the first rib, may lead to the post fixation of brachial plexus with a large contribution from T2. In such cases when the shoulder girdle sags, its traction affects the lower trunk causing neurological symptoms<sup>(13)</sup>. Rib fusion also causes scoliosis and restriction of chest wall expansion<sup>(8)</sup>.

Bicipital rib is a rare congenital variation usually detected on radiography in a living subject. Such pathological variant often indicates an underlying systemic disease and also becomes an uncommon cause of thoracic outlet syndrome.

Professor W M Turner<sup>(18)</sup> had stated in his article that the first case of bicipital ribs was recorded in 1740 by Dr.M Hunauld, which he communicated to the Royal Academy of Sciences in Paris. Turner<sup>(18)</sup> himself had mentioned in his study that such anomaly is presented in man and Cetecea species.

Ramazan<sup>(14)</sup>, in his study on 650 patients had observed 18% of cases with union of the midpoint of the shaft of 1<sup>st</sup> and 2<sup>nd</sup> ribs, using multidetector computed tomography procedure. He also mentions that older studies had revealed 0.3% incidence of fusion of ribs. Jyoti's<sup>(10)</sup> case report on such kind of anomaly states that the fusion had started 1.5cm from the tubercle of first rib. The fusion in her case was found more anteriorly than that found in the present case. Anita<sup>(1)</sup> had given an incidence of 0.1% for this anomaly when she

detected such a specimen out of 1000 ribs. The presence of osseous tunnel in the fusion of 1<sup>st</sup> and 2<sup>nd</sup> ribs was the unique finding in the specimen as reported by Gupta<sup>(8)</sup>. He denotes the risk of entrapment of the first intercostals nerve when it passes through such tunnel. Similar kind of bicipital rib with the complete fusion of 1<sup>st</sup> and 2<sup>nd</sup> ribs except the head and tubercle was noted by Anupama<sup>(2)</sup>. The case report given by Vidhya<sup>(19)</sup> is almost similar to the present case report with the costal groove in the under surface of the second rib. The observations of Loganayaki<sup>(12)</sup> regarding bicipital ribs in her 4 specimens, clearly states the thoracic outlet syndrome to be the main consequence of such anomaly. The present study is in similar occurrence with her second specimen and the estimated incidence is 0.5%.

In the present study, the anomaly of the synostosis of the first and second ribs, were fused at the posterior ends and are free at the anterior ends. Hence it is mentioned to be as the Bicipital rib. After studying the specimen, few assumptions were made regarding the consequences of this malformation. The first intercostal space is obliterated which would have lead to the anomalous pathway of the neurovascular bundle or may have caused the compression of the neurovascular structures. Due to fusion, abnormal articulation of the thoracic vertebrae with the ribs might have occurred which would have created an abnormal thoracic cage. The reported anomaly in the present study, has also the possibility of causing the signs and symptoms of thoracic outlet syndrome.

A knowledge of this anatomical variations is important for Clinicians and Orthopaedic Surgeons during the differential diagnosis with other diseases, such as a chest wall tumors or costal fracture and for counting the ribs. The bicipital rib may cause severe neurological and vascular compromise and such a defect should be corrected surgically without delay<sup>(4)</sup>.

## Conclusion

Synostosis of the first and second rib is an important variable anomaly to be noted not only by the Anatomists, but the knowledge of its incidence should also be known to the Radiologists, Clinicians and Surgeons. It is usually asymptomatic and may be incidentally detected during routine chest radiography. It may cause musculoskeletal pain due to the conjoint shaft or intercostal nerve entrapment which occurs from the obliteration of the intercostals space due to synostosis<sup>2</sup>. It can also be the indirect cause for thoracic outlet syndrome. It was mentioned in many studies that such type of rib anomaly is found to be a constant component of some 22 kinds of syndromes<sup>(21)</sup> When a patient presents with the signs and symptoms of neurovascular compression, the possibility of the synostosis defect of the first rib should be kept in mind. Also thorough investigation, without neglecting any underlying systemic disorder should be done when a rib anomaly like bicipital rib is detected. A prompt decision for proper surgical interventions should be made to correct the pathologic consequences of such rib abnormalities.

## References

1. Anita R et al. Synostosis of First and Second Rib – Case Report. Journal of Anatomical Society of India 2009; 58(2): 189- 191.
2. Anupama K et al. An unusual case of Synostosis of first and second Rib. Int J Anat Res 2013;02:104-06.
3. Atasoy E et al. Thoracic Outlet Syndrome: Anatomy. Hand Clin, 2004; 20: 7-14.
4. Baumgartner F et al. The rudimentary first rib: A cause of thoracic outlet syndrome with arterial compromise. Arch Surg 1989; 124: 1090–1092.
5. Bruce M Carlson. Human Embryology and Developmental Biology. 4<sup>th</sup> Ed; Mosby Elsevier, 2009: Page 192-193.

6. Dale, W.A. and Lewis, M.R. Management of thoracic outlet syndrome. *Ann Surg*, 1975: 181:575–585.
7. Etter, L.E. Osseus abnormalities of the thoracic cage seen in forty thousand consecutive chest photo roentgenograms. *Am J Roentgenol*, 1944 :51:359–363.
8. Gupta V et al. Synostosis of first and second thoracic ribs: Anatomical and radiological assessment. *International Journal of Anatomical Variations* 2009: 2:131-133.
9. Helegman D et al. Sacral ribs: A case report. *Orthopedics* 1987: 10 (10): 1439-1442.
10. Jyothi K.C. et al. Bicipital rib – a case report. *Int J Cur Res Rev*, June 2013:Vol 05 (11) Page 100.
11. Keith L Moore. *The Developing Human Clinically Oriented Embryology*. 6<sup>th</sup> Ed, Saunder's Company, 1998: page 414-48.
12. Lokanayaki.V. Bicipital Ribs- A Report of Four Cases. *People's Journal of Scientific Research*, 2013:Vol. 6(2); page 51-54.
13. Plessis DJ. *Bones In: A Synopsis of Surgical Anatomy*. 11th edition. John Wright & sons Ltd. The Stonebridge Press, Bristol,1975: 224-250.
14. Ramazan Davran et al. Congenital abnormalities of the ribs: evaluation with multidetector computed Tomography. *J Pak Med Assoc*, 2017:Vol. 67, No. 2.
15. Standring, S. *Gray's Anatomy- The Anatomical Basis of Clinical Practice*. 40thEd, Elsevier Churchill Livingstone. Edinburgh, London. pp. 924.
16. Thomas MA, Jamieson EB: *Osteology*. In: *Cunningham's textbook of Anatomy*. JC Brash, EB Jamieson, (Eds.); 7th End.; Oxford University press London, 1937: pp,132.
17. Todd T.W. Costal anomalies of the thoracic inlet, their interpretation and significance. *Anat Anz*, 1912: 41: 257–271.
18. Turner W M . Cervical ribs and the so called Bicipital Ribs in man, In relation to corresponding structures in the Cetacea. *J Anat Physiol*, 1883:17(3) : 384-400.
19. Vidya K et al. Synostosis of First and Second Ribs: A Case Report. *South Asian Anthropologist* 2015: 15(1): 15-17.
20. White, J.C et al. Congenital malformations of the first thoracic rib: A cause of brachial neuralgia which simulates the cervical rib syndrome. *Surg Gynecol Obstet* 81:643–659.
21. Winter RM, Baraister M. *Multiple congenital anomalies A diagnostic compendium: Ed 1<sup>st</sup>*, Chapman and Hall Medical, London, 1991: pp 1263, 1264.