



A Comparative Study of Icthammol Glycerine with Antibiotic Ear Drops in Furunculosis

Authors

Dr Harshvardhan¹, Dr Surbhi²

¹Senior Resident, Patna Medical College and Hospital

²Junior Resident 3, Patna Medical College and Hospital, Patna, India

Abstract

Furunculosis is a localised form of infection of sole hair follicle. Since hair follicle is present only in the cartilaginous segment therefore furuncle is seen only on the lateral segment of external auditory canal. Staphylococcus is the chief infective organism. Diagnosis is mainly clinically by presenting symptoms and otoscopic examination. Topic antibiotics have tried but with varied results.

Material & Methods: *This is a randomized clinical trial study done in our ENT OPD at Patna medical college, Patna. After proper examination and consent.*

Objective: *To compare the efficacy of ichtmmol glycerine and antibiotic ear drops active against staphylococcus aureus in treatment of furunculosis of ear.*

Results: *Though the results of both the treatments were alike at the end of treatment period, symptoms improvement with ichtammol glycerine was much quicker and before than antibiotic ear drops.*

Keywords: *Furuncle, Furunculosis, Antibiotic, Icthammol Glycerine.*

Introduction

Furunculosis is localized otitis externa. It is caused by staphylococcal infection of a single hair follicle. Oral antibiotics are the treatment of choice before abscess formation. Incision and drainage are recommended if an abscess forms. Severe associated soft-tissue infection or cellulitis is an indication for systemic antibiotic therapy. The clinical efficacy of glycerine-ichtammol in otitis externa may be due to an anti-inflammatory action of ichtammol or a dehydrating effect of glycerine on the oedematous ear canal. A study of the antibacterial property of glycerine-ichtammol showed inhibition of selected gram positive organisms (Streptococcus pyogenes and Staphylococcus aureus) by ichtammol and

glycerine-ichtammol combination, but only negligible antibacterial activity against Pseudomonas aeruginosa and Escherichia coli. Candida albicans was also weakly inhibited.

Material and Methods

This is randomized clinical trial which was conducted in department of otolaryngology, Patna medical college over a period of one year from December 2017 to November 2018. Patients presenting in the ENT outpatient department were examined and were elected for study purpose after written consent. Case was confirmed after complete history followed by otoscopic examination of ear. Dry mopping was done in required cases. Main presenting symptoms for

diagnosis were ear pain, ear heaviness and discharge.

Inclusion Criteria

- 1) Age group between 12 to 50
- 2) Clinically confirmed cases of furunculosis with other disease excluded
- 3) Those giving consent for study and regular follow up
- 4) Localised infection

Exclusion Criteria

- 1) Age less than 12 years and more than 50 years.
- 2) History of chronic otitis media.
- 3) Uncontrolled diabetes mellitus .
- 4) Those no giving consent for study upon them

Patients were randomly allocated between group 1 and group 2 of 50 patient each. Group 1 patient was provided with ichthammol glycerine ear wick which was changed every day and group 2 was given antibiotic ear drops. Each patient was given an oral antibiotic coverage with amoxicillin group for one week. Trial subject was evaluated on visual analog scale based on symptoms i.e ear pain, ear heaviness and discharge. Ear was examined on all the follow up days 3,5,and 7.After all the patients were completed with their follow up of 2 week ,result was analysed. Results were checked and compared to adjust p values.

Results

Total number of patients which were examined in this study was 100.Fifty patients were randomly allotted in each group. Symptoms in both the group was noted at the start of study. Common symptoms in both the groups were were asked from each patient in each group. Groups which was divided was group 1 and group 2.Group 2 was given antibiotic ear drops and group 1 patients ear was packed with ichthammol glycerine 10% 24 hourly. Both the groups patients were followed up on 3rd ,5th and 7th day and symptoms was recorded from each patient followed by otoscopic examination of ear canal ,if required dry mopping of the canal was done.fig1

	GROUP 1	GROUP 2
PAIN	48	49
HEAVINESS	50	50
DISCHARGE	46	48

Fig 1

On day 1 both the groups patients had equal symptoms. When compared to symptom on day 1 to day 3, change was significant (P<.05). Statistically significant difference was seen in both the groups. Group 1 showed more improvement in pain and heaviness than group 2. Discharge has also decreased more in group 1 compared to group 2.fig 2

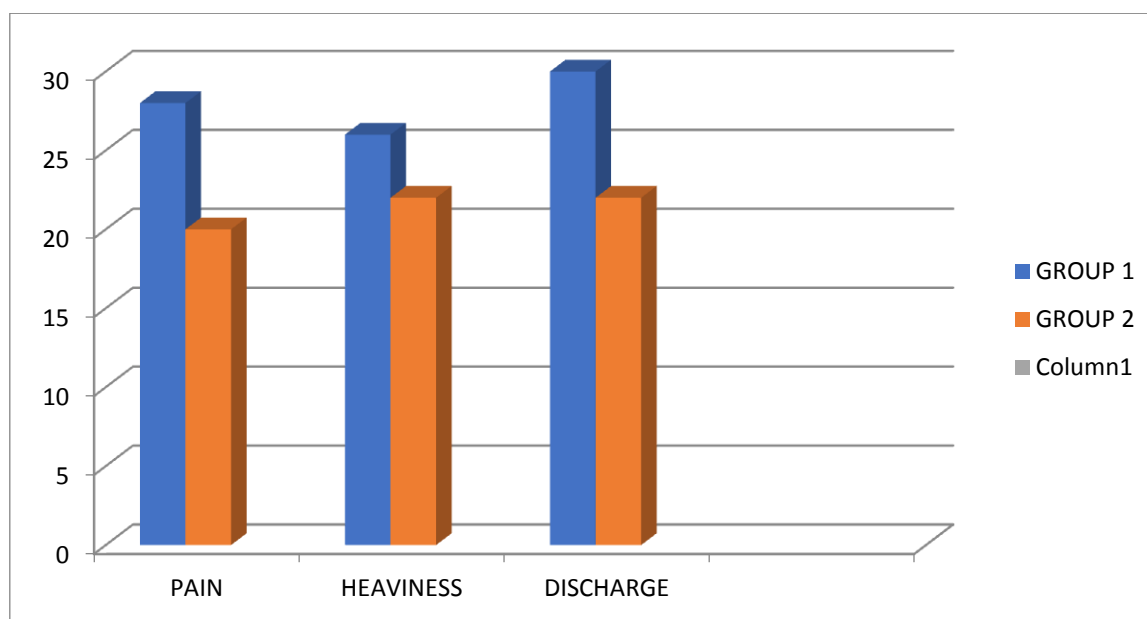


Fig 2

When examined on day 5th, both the group showed much more improvement in symptoms. Group 1 showed almost absolute resolution of most of the symptoms. Discharge was scanty in most of the patients. Symptoms of pain and

heaviness in both the groups was comparable and showed diminish in both the groups. However number of patients with improved symptoms were more in group 1. fig 3

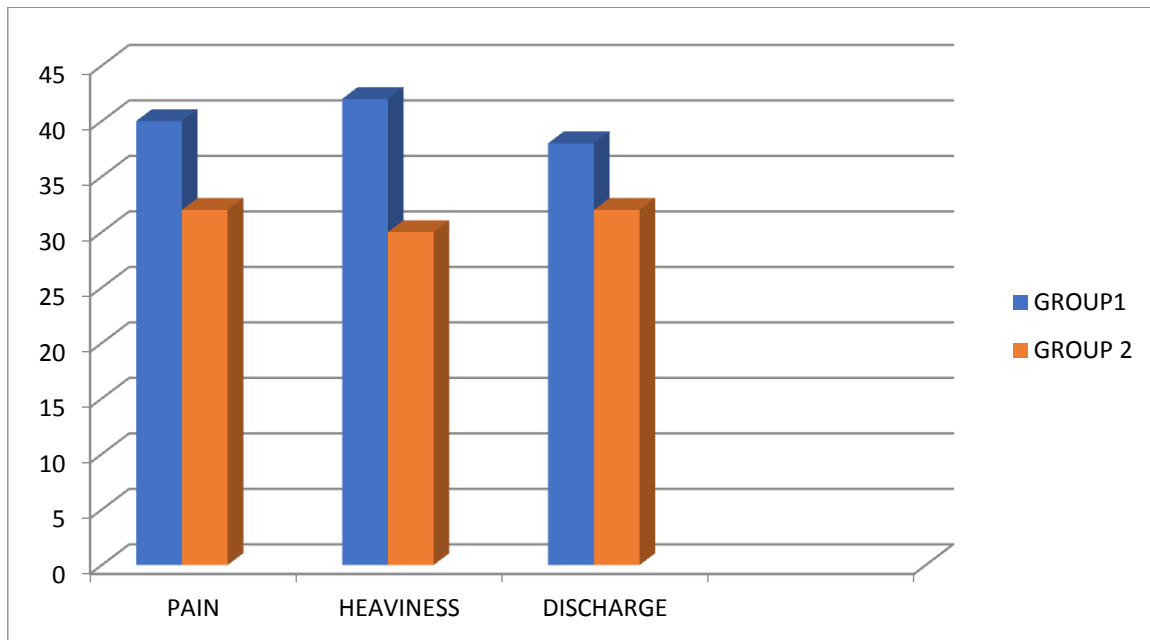


Fig 3

Follow up on day 7th, results were akin. Group 1 and group 2 both had recovered in their pain, heaviness and discharge symptoms. There was complete resolution of symptoms in both the groups in maximum number of patient. Although the number of patient with complete resolution of

symptoms was more in iccthamol glycerine group. fig 4
Canal edema was seen to turn down soon with icthmmol glycerine wick but was later on with the use of drops.

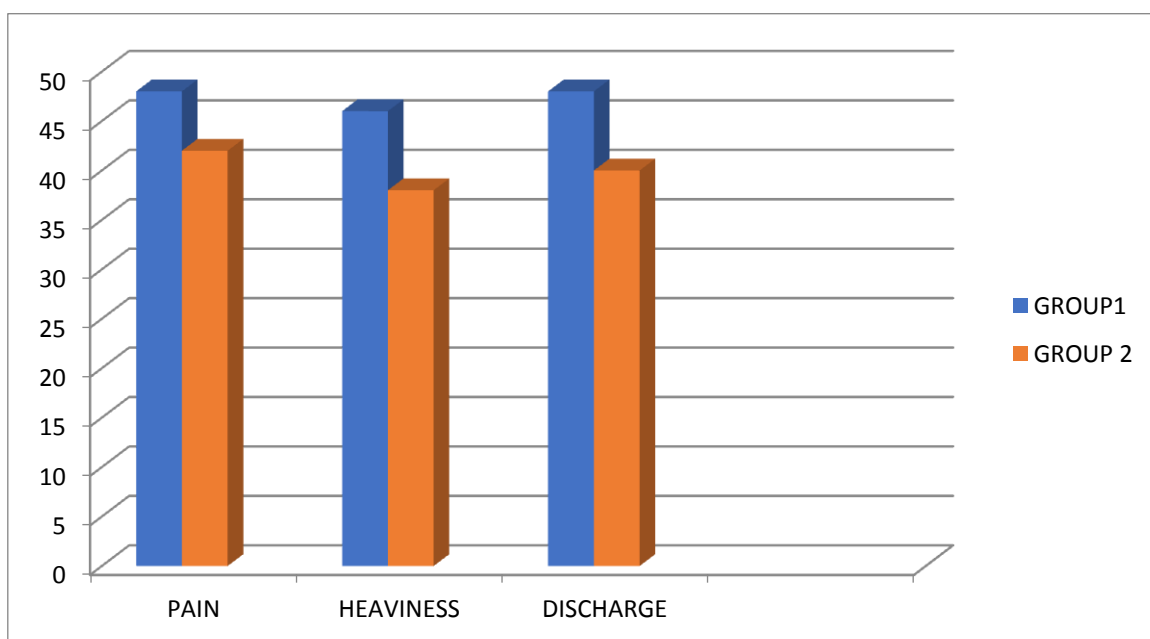


Fig 4

Discussion

Furunculosis is a local form of otitis externa and is a infection of single hair follicle. Hair follicle being present only on the outer part of external auditory canal, therefore a furuncle happens to occur only on the outer part of canal which is cartilaginous part. Bacteria invades hair follicle and leads to well confined deep skin infection. Further progression leads to pustule, abscess and may be associated with cellulitis and edema. Bacteria multiplies inside the ostium of hair follicle¹. Key presenting symptom is pain, patient often feels heaviness in the ear with scanty serous discharge. Tragal tenderness is mostly present. Otosopic examination usually establishes the diagnosis. Staphylococcus aureus (*S. aureus*) is the most widespread organism causing furunculosis. The *S. aureus* frequently express genes for Panton–Valentine leucocidin (PVL)² Leucocidal toxins isolated from pathogenic strains of *S. aureus* trigger lysis of phagocytic cells and may have an central role in cutaneous infection³. Sporadic cases of furunculosis happen when pathogenic organisms are introduced into the canal in the circumstance of other local risk factors. Several conditions emerge to be associated with recurrent furunculosis including hypogammaglobulinaemia, diabetes mellitus and dysphagocytosis^{4,5}.

If untreated, the infection usually progresses to a localized abscess, which then discharges into the external ear canal. Providing there is enough drainage, the infection will resolve of your own accord. The infection can also extend towards the deeper tissues, where it may cause a diffuse soft-tissue infection spreading to the pinna, post-auricular skin and parotid gland. Recurrent infection can cause enduring scarring and fibrosis of the external canal with following meatal stenosis. Eventually, this may also dispose to chronic disseminated otitis externa.

Furunculosis of the external canal is exquisitely painful and suitable analgesics should be obtainable to all patients. No data exists that compares the efficacy of different analgesics. A

recent systematic review of treatment for otitis externa specifically excluded furunculosis from consideration.⁶ Oral or systemic antistaphylococcal antibiotics like penicillinase-resistant penicillin, macrolide, cephalosporin, clindamycin or quinolone and topical treatment (antibiotics, astringents, hygroscopic dehydrating agents) are used for treatment.

Oral antibiotic treatment is recommended in the early stages of the disease. Severe spreading soft-tissue infection should be treated with intravenous antibiotic therapy. Incision and drainage is advocated if abscess is formed. Topical treatment is preferable, if abscess has discharged, surgically or spontaneously. Topical antibiotics active against staphylococcus are usually prescribed. Placing a wick into the ear canal facilitates treatment in the presence of severe canal oedema and narrowing. Glycerol and ichthammol solution has a precise antistaphylococcal action^{7,8} and is hygroscopic, thus causing dehydration of the canal tissue. Aluminium acetate solution is an astringent as well as a hygroscopic agent. Other choices are eradication therapy with nasal mupirocin or with oral flucloxacillin or azithromycin for 14 days. Bacterial intervention therapy which is intentionally implanting a non-pathogenic strain of *S. aureus* (strain 502A is the most popular) to recolonize the nares and skin.

It has been reported that correction of specific biochemical abnormalities (e.g. hypoferraemia, low serum zinc) may lead to a marked drop in the incidence of infections.

Conclusion

Furunculosis is a localised form of infection of single hair follicle. Oral antibiotic treatment is suggested in the early stages of the disease. Topical treatment is preferable. Topical antibiotics active against staphylococcus are usually prescribed. Insertion of a wick into the ear canal facilitates treatment in the presence of severe canal oedema and narrowing. Glycerol and ichthammol solution has a specific antistaphylococcal action and is hygroscopic, thus

causing dehydration of the canal tissue. The result of using topical antibiotic ear drop is comparable to ichthammol and glycerine but signs and symptoms improve faster and earlier with glycerine and ichthammol than with topical antibiotics.

References

1. Abe Y, Akiyama H, Arata J. Furunclelike lesions in mouse experimental skin infections with *Staphylococcus aureus*. *J Dermatol* 1993; 20: 198–202.
2. Durupt F, Mayor L, Bes M, et al. Prevalence of *Staphylococcus aureus* toxins and nasal carriage in furuncles and impetigo. *Br J Dermatol* 2007; 157: 1161–7.
3. Szmigielski S, Prevost G, Monteil H, et al. Leukocidal toxins of staphylococci. *Zentralbl Bakteriologie* 1999; 289: 185–201.
4. furunculosis: Bacteriological findings and epidemiology in 100 cases. *Scand J Infect Dis* 1981; 13: 115–19.
5. Wertheim HF, Melles DC, Vos MC, et al. The role of nasal carriage in *Staphylococcus aureus* infections. *Lancet Infect Dis* 2005; 12: 751–62.
6. Kaushik V, Malik T, Saeed SR. Interventions for acute otitis externa. *Cochrane Database Syst Rev* 2010; 20: CD004740. 10
7. Ahmed K, Roberts ML, Mannion PT. Antimicrobial activity of glycerine-ichthammol in otitis externa. *Clin Otolaryngol Allied Sci* 1995; 20: 201–3.
8. Nilssen E, Wormald PJ, Oliver S. Glycerol and ichthammol: medicinal solution or mythical potion? *J Laryngol Otol* 1996; 110: 319–21.