



Mischievous Lymph Node in Peadriatic Age Group

Authors

Roopali Jandial¹, Ritu Bhagat^{2*}, Kuldeep Singh³

¹Demonstrator, Department of Pathology, Government Medical College, Jammu, India

^{2*}Demonstrator, Department of Pathology, Government Medical College, Jammu, India

³Head of the Department, Department of Pathology, Government Medical College, Jammu, India

*Corresponding Author

Dr Ritu Bhagat

Department of Pathology, Government Medical College, Jammu, J&K, India

Abstract

Introduction: Assessment of a child with lymphadenopathy is a common clinical consequence for the pediatricians. They are considered enlarged when their diameter transcends 1cm for cervical and axillary nodes and more than 1.5 cm for inguinal nodes.

Method and Material: This prospective study was carried out over a period of one year in the department of Pathology, Government Medical College, Jammu, India. All pediatric cases (upto 17 years) with palpable lymph nodes attending the cytology section of the department were included. The aim of this study is to evaluate the role of FNAC in the diagnosis of pediatric lymphadenopathy and to study diverse cytomorphological patterns and their incidence in lymph node aspirates.

Results: A total of 129 cases were studied. The age range we included was 0-17 years. Majority of the patients with lymphadenopathy were in the age group of 6-10 years 52%. The male to female ratio was found to be 3:1. The most common group of lymph nodes involved was cervical group 94%. Sixty-seven cases presented with multiple lymph node enlargement. Non neoplastic group of lesions dominated the study, most common diagnosis was non specific reactive lymphadenitis with 60.5% cases. Among the neoplastic lesions one case each of Hodgkin lymphoma, non Hodgkin lymphoma and metastatic tumour were seen over the study period.

Conclusion: The FNAC is a cost effective diagnostic procedure to diagnose majority of cases. This helps in avoiding unnecessary invasive procedures and associated complications.

Keywords: Children, Lymph node, Peadriatics, Reactive.

Introduction

Assessment of a child with lymphadenopathy is a common clinical consequence for the pediatricians.¹ Lymph nodes are a part of reticuloendothelial system which serve as the point of termination for lymphatic vessels draining lymph from most tissues of the body. It is ideally first line of defense against pathogens

because of presence of abundant phagocytic cells, antigen presenting cells and lymphocytes, as a result, most of the children present with small palpable cervical, axillary and inguinal lymph nodes.^{1,2,3} They are considered enlarged when their diameter transcends 1cm for cervical and axillary nodes and more than 1.5 cm for inguinal nodes. Other deep seated lymph nodes usually are

not palpable or visualized with plain radiographs only.⁴ Palpable supraclavicular nodes are always considered abnormal.^{2,5} In the last few years, FNAC has appeared as a consistent diagnostic procedure in the paediatric age group, thus precluding the need for excision biopsy.^{6,7}

The aim of this study is to evaluate the role of FNAC in the diagnosis of pediatric lymphadenopathy and to study diverse cytomorphological patterns and their incidence in lymph node aspirates.

Method and Material

This prospective study was carried out over a period of one year in the department of Pathology, Government Medical College, Jammu, India. All pediatric cases (upto 17 years) with palpable lymph nodes attending the cytology section of the department were included. FNAC was done on the representative lymph nodes as per the standard protocol and under strict aseptic precautions. An informed consent was taken from parent or attending guardian of all patients before performing the procedure. Relevant clinical details including age, sex, site and investigations were recorded. The site and size of the lymph nodes being aspirated was measured. A 21-24 gauge needle attached to 10 ml syringe mounted on Cameco handle was used for the procedure. The overlying skin was cleaned with ethanol. The mass was then fixed between the index and middle finger and then needle was inserted into the swelling and full suction pressure was applied. The needle was moved briskly in different directions in the swelling till a spot of material was visualized in the stem of the needle. The negative pressure of the syringe was released, and the needle was taken out. The needle was removed from the syringe and the aspirated material was expelled out on clean glass slides. For smaller lymph nodes (≤ 1 cm) non-aspiration technique i.e. needling of the swelling was done. At least 4 good aspirate smears were prepared. Two smears were alcohol fixed and stained with Papanicolaou stain (PAP stain) and another two smears were air dried

and stained with Giemsa stain. All cytological smears were evaluated based on adequacy, cellularity, type of cells, arrangement of cells and nuclear as well as cytoplasmic features. Background was evaluated in all smears for any necrosis or inflammatory cells. All cases revealing granulomas/necrosis were further evaluated with Ziehl-Neelson (ZN) staining to rule out any Acid-Fast bacilli (AFB).

Results

A total of 129 cases of lymph node FNAC in pediatric age group were studied. The age range we included was 0-17 years. The study group was further divided into three age groups – 0-5 years, 6-10 years and 11-17 years. Majority of the patients with lymphadenopathy were in the age group of 6-10 years 67/129 cases (52%), followed by 11-17 years age group 43/129 cases (33%) and least in 0-5 years age group 19/129 cases (15%). Lymphadenopathy was much more commonly observed in male children 97/129 cases (75%) than in female children 32/129 cases (25%). The male to female ratio was found to be 3:1. Table 1

Table 1: Showing age distribution

| Age group (years) | No. of cases | Percentage% |
|-------------------|--------------|-------------|
| 0-5 | 19 | 15 |
| 6-10 | 67 | 52 |
| 11-17 | 43 | 33 |
| Total | 129 | 100 |

Out of 129 cases, the most common group of lymph nodes involved was cervical group 121/129 cases (94%) followed by axillary lymph nodes in 4/129 cases (3%), supraclavicular lymph nodes enlargement was found in 03 cases (2%) and inguinal lymph nodes in only 01 case (0.8%) respectively.

In our study, out of 129 cases 67 cases (52%) presented with multiple lymph node enlargement as compared to solitary lymph node enlargement seen in 62/129 (48%) cases. Table-2

Table 2: Distribution according to group of lymph node involved

| Lymph node groups | No. of cases | Percentage % |
|-------------------|--------------|--------------|
| Cervical | 121 | 94 |
| Axillary | 04 | 03 |
| Supraclavicular | 03 | 02 |
| Inguinal | 01 | 0.8 |
| Total | 129 | 100 |

Various cytomorphological diagnosis were obtained during the study period. These were further divided into non- neoplastic and neoplastic lesions.

Non neoplastic group of lesions dominated the study, among non neoplastic lesions most common diagnosis was non specific reactive lymphadenitis with 60.5.% cases, followed by granulomatous lymphadenitis 14.7% cases, tuberculous lymphadenitis 13.2% cases and suppurative lymphadenitis 9.3% cases.

Among the neoplastic lesions one case (0.8%) each of Hodgkin lymphoma, non Hodgkin lymphoma and metastatic tumor were seen over the study period. Table 3

Table 3: FNAC diagnosis in Lymph node

| Diagnosis | No. of Cases | Percentage % |
|-------------------------------------|--------------|--------------|
| Non specific reactive lymphadenitis | 78 | 60.5 |
| Granulomatous lymphadenitis | 19 | 14.7 |
| Tuberculous lymphadenitis | 17 | 13.2 |
| Suppurative lymphadenitis | 12 | 9.3 |
| Hodgkin lymphoma | 01 | 0.8 |
| Non hodgkin lymphoma | 01 | 0.8 |
| Metastatic tumor | 01 | 0.8 |
| Total | 129 | 100 |

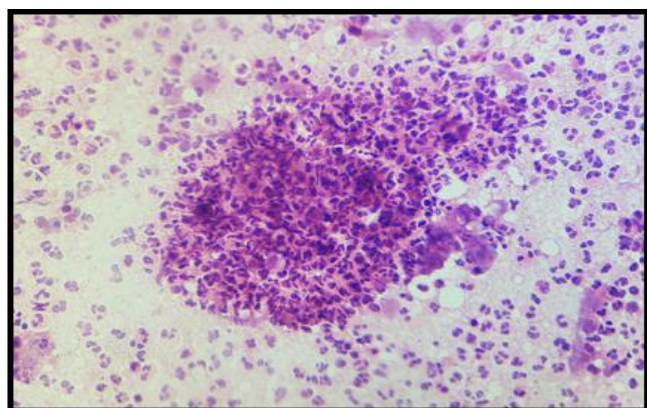


Figure 1: A microphotograph showing an acute suppurative lymphadenitis from an axillary lymph node aspirate (MGG;40X)

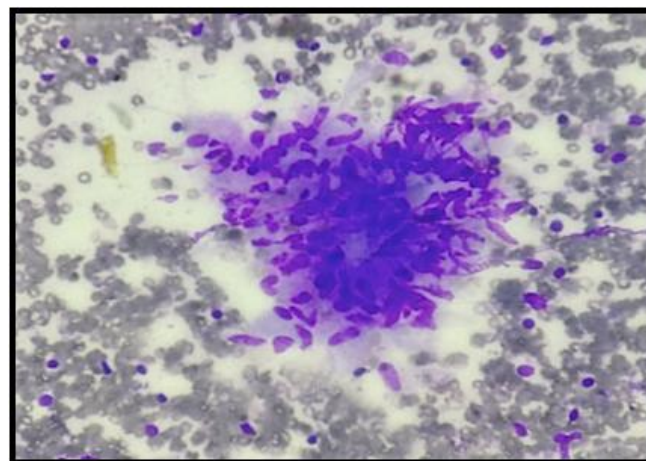


Figure 2: A microphotograph showing a well formed epithelioid cell granuloma from a cervical lymph node aspirate (MGG; 40X)

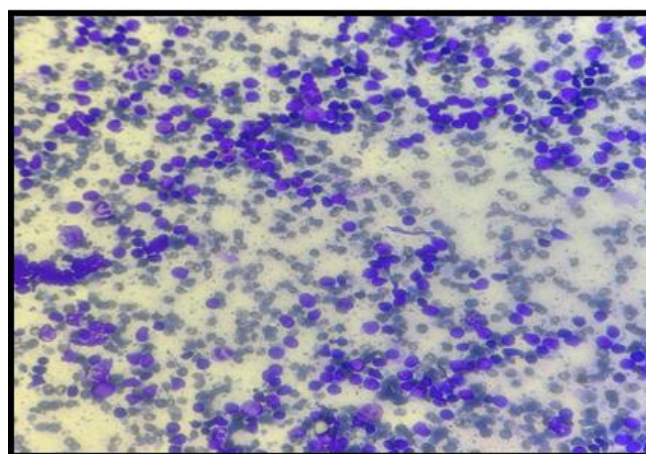


Figure 3: A microphotograph showing a reactive lymph node having mixed lymphoid population from a cervical lymph node aspirate (MGG;10X)

Discussion

LAP is a common clinical presentation encountered in pediatric population. The etiology in these cases may vary from a benign etiology to a malignant condition. FNAC plays a very important role in evaluating superficial lymph nodes as these are easily accessible for the procedure. Further, FNAC is also advocated due to the ease of the procedure, a relatively non-invasive procedure, quick diagnosis and cost effectiveness.⁸ Being the most cost-effective procedure with rapid diagnosis, FNAC is the most frequently used procedure for palpable lesions worldwide.

Our study shows that FNAC is a beneficial initial

investigating tool in children with persistent peripheral lymphadenopathy to distinguish between benign and malignant disease.

In the present study, maximum number of patients were in the age group of 6-11years (52%) followed by 11-17 years age group (33%). Wakely PE Jr et al⁹ also observed FNACs in <16 years age group and found that majority cases were seen in age group of 6-11 years (34.82%). Similar results were seen in a study done by Ponder TB et al.¹⁰

Our study showed that, incidence in males (75%) was more than that in females (25%) with male to female ratio 3:1. Similar results were obtained in studies of Bezabih M et al¹¹ and Mitra S et al.¹² Many studies showed almost equal incidence in males and females as seen in the study by Haque MA and Talukder SI¹³ and Pandit AA et al.¹⁴ A study done by Ahmad T et al¹⁵ showed reverse ratio (0.47:1) with predominance of females in the study group.

In the present study, cervical group of lymph nodes was most commonly involved (94%), followed by axillary group (03%). Multiple lymph node involvement (52%) was more frequently seen as compared to solitary lymphadenopathy (48%) in our study. Other studies done by Haque MA and Talukder SI¹³, Pandit AA et al¹⁴, Steel BLS et al¹⁶ and Hussain M et al¹⁷ also showed predominantly cervical lymph node involvement. In a study done by K Alamet al¹⁸ maximum number of aspirations were done from cervical lymph nodes (74.2%). The reason behind this may be the easy accessibility of cervical lymph nodes for examination and evaluation.

Non-neoplastic lesions (98%) dominated the study over neoplastic lesions (2%). Similar results were seen in studies done by Kumral A et al¹⁹ and Wakely PE Jr et al.⁹

Among the non-neoplastic lesions in this study, non-specific reactive lymphadenitis was the most common finding 78/129 (60.5%), followed by granulomatous lymphadenitis 19/129 (14.7%), tuberculous lymphadenitis 17/129 (13.2%) and suppurative lymphadenitis 12/129 (9.3%). Other

studies showing similar results with non-specific reactive hyperplasia as the predominant pattern, were done by Lake MA and Oski FA²⁰, Annam V et al²¹ and Hag IA et al.²²

In our study, only 03/129 cases (2%) were neoplastic, out of which one case each of Hodgkin's lymphoma, non Hodgkin lymphoma and metastatic were noted. Other studies involving children with lymphadenopathy where similar incidence of neoplastic lesions was seen along with predominance of lymphomas were done by Bhandari B and Jain AM²³, Lake MA and Oski F²⁰, Annam V et al²¹, Wakely PE Jr et al⁹, Hussain M et al¹⁷ and Ponder TB et al.¹⁰

Conclusion

The FNAC is a cost effective diagnostic procedure to diagnose majority of cases and to sort suitable cases which need further management or referral to higher centers. This helps in avoiding unnecessary invasive procedures and associated complications. Reactive lymphadenitis is self-limiting and most common cause of LAP in children. While interpreting, a cyto-pathologist must keep in mind the clinical, radiological and laboratory details.

References

1. Lymphadenitis and Lymphangitis. In: Case Based Pediatrics For Medical Students and Residents. New York: Churchill Livingstone. 2003:34.
2. EU Regulations for Clinical Studies in Pediatric Patients. EU Pediatric Patient Guidelines. (EC) No. 1901/2006 (amended by 1902/2006).
3. Andrew W. Bazemore. Lymphadenopathy and Malignancy. *Am Fam Physician*. 2002;66:2103-11.
4. Chesney P. Cervical Adenopathy. *Pediatrics in Review*. 1994;15:276-284.
5. Kliegman M. Robert, Behrman E. Richard. The Lymphatic System. In: Nelson Textbook of Pediatrics 18 Ed. Elsevier. 2007;2:2093.

6. Handa U, Mohan H, Bal A. Role of fine needle aspiration cytology in evaluation of paediatric lymphadenopathy. *Cytopathology*. 2003;14: 66 – 69
7. Ajmal F, Imran A. Comparison of FNAC vs excision biopsy for suspected tuberculous cervicallymphadenopathy. *Annals King Edward med coll*. 2003; 9:216-8.
8. Hafez NH, Tahoun NS. Reliability of fine needle aspiration cytology (FNAC) as a diagnostic tool in cases of cervical lymphadenopathy. *J Egypt Natl Canc Inst* 2011;23: 105-114.
9. Wakely PE Jr, Kardos TF, Frable WJ. Application of fine needle aspiration biopsy to pediatrics. *Hum Pathol*. 1988;19:1383-6.
10. Ponder TB, Smith D, Ramzy I. Lymphadenopathy in children and adolescents: role of fine-needle aspiration in management. *Cancer Detect Prev*. 2000;24:228-33.
11. Bezabih M, Mariam DW, Selassie SG. Fine needle aspiration cytology of suspected tuberculous lymphadenitis. *Cytopathology*. 2002;13:284-90.
12. Mitra S, Ray S, Mitra PK. Fine needle aspiration cytology of supraclavicular lymph nodes: Our experience over a three-year period. *J Cytol*. 2011;28:108-10.
13. Haque MA, Talukder SI. Evaluation of fine needle aspiration cytology (FNAC) of lymph node in Mymensingh. *Mymensingh Med J*. 2003;12:33-5.
14. Pandit AA, Candes FP, Khubchandani SR. Fine needle aspiration cytology of lymph nodes. *J Postgrad Med*. 1987;33:134.
15. Tariq Ahmad, Mohammad Naeem, Siddique Ahmad, Ambreen Samad, Amir Nasir. *J Ayub Med Coll Abbottabad*. 2008;20:34-37.
16. Steel BL S, Schwartz MR, Ramzy I. Fine needle aspiration biopsy in the diagnosis of lymphadenopathy in 1,103 patients. Role, limitations and analysis of diagnostic pitfalls. *Acta Cytol*. 1995;39:76-81.
17. Mukhtar Hussain, Akram Shad Chisti, Rubina Mukhtar, Hanif Khan, Hussain Siddiqui, Haroon Kd Pasha. Peripheral Lymphadenopathy in Children, Comparison of Fine Needle Aspiration Cytology with Open Biopsy. *Ann King Edward Med Coll*. 2005;11:398-9.
18. K Alam, V Maheshwari, N Haider, FA Siddiqui, A Jain, AH Khan: Fine needle aspiration cytology (FNAC), a handy tool for metastatic lymphadenopathy. *The Internet Journal of Pathology*. 2010;10:21-28.
19. Kumral A, Olgun N, Uysal KM, Corapcioğlu F, Oren H, Sarialioğlu F. Assessment of peripheral lymphadenopathies: experience at a pediatric hematology-oncology department in Turkey. *Pediatr Hematol Oncol*. 2002;19:211-8.
20. Lake MA, Oski FA. Peripheral lymphadenopathy in childhood. *Am J Dis Child*. 1978;132:357-359.
21. Annam V, Kulkarni MH, Puranik RB. Clinicopathologic profile of significant cervical lymphadenopathy in children aged 1-12 years. *Acta Cytol*. 2009;53:174-8.
22. Hag IA, Chiedozi LC, al Reyees FA, Kollur SM. Fine needle aspiration cytology of head and neck masses. Seven years' experience in a secondary care hospital. *Acta Cytol*. 2003;47:387-92.
23. Bhandari B, Jain AM. Lymph node biopsy in infants and children A new bedside method. *Arch of Dis Child*. 1970; 45:510-512.