



Case Report

Tuberculosis of the Breast- A Rare Entity

Authors

Mohit Rajpal¹, Amrita Kulhria^{2*}, Amit Sammi³

¹Senior Resident, Department of Pathology, B.P.S. Government Medical College For Women, Khanpur Kalan, Sonapat Haryana

²Senior Resident, Department of Pathology, B.P.S. Government Medical College For Women, Khanpur Kalan, Sonapat Haryana

³Assistant Professor, Department of Pathology, Adesh Medical College and Hospital, Ambala, Haryana

*Corresponding Author

Amrita Kulhria

Addresses: Department of Pathology, B.P.S. Government Medical College For Women, Khanpur Kalan, Sonapat Haryana. 131305, India

Abstract

Introduction: Tuberculosis of the breast is an uncommon disease accounting less than 0.1% of breast conditions in developed countries and 3–4% in regions, where the disease presents with high incidence (India, Africa). Misdiagnosis is common in biopsy and aspiration smears as it is usually paucibacillary. In most cases, cultures are also negative. It often mimics breast carcinoma and pyogenic breast abscess both clinically and radiologically.

Case Report: We report a case of mammary tuberculosis in a 25 year old lactating female, who presented in surgery OPD at Adesh Medical College and Hospital with painful lump in the left breast since one year.

Conclusion: Mammary tuberculosis is a rare disease. It can be deceptive to radiologist and surgeons as it can mimic carcinoma. Definitive diagnosis relies on demonstration of acid fast bacilli either on microscopy, culture or molecular studies such as polymerase chain reaction. Polymerase chain reaction has good sensitivity for detection.

Introduction

Tuberculosis of the breast is relatively rare, with reported incidence of 3-4.5% in developing countries like India and less than 0.1% of all breast lesions in Western countries.^{1,2} The first case of breast tuberculosis was reported by Sir Astley Cooper who named it as “scrofulous swelling of the bosom”.³ It usually affects lactating and multiparous women, although there

have been cases reported in prepubescent males, or in elderly women.² It has a multifaceted clinical presentation, often mimicking carcinoma and pyogenic breast abscess.

Case Report

A 25 year old lactating female presented in surgery opd at Adesh Medical College and hospital with painful lump in the left breast since

one year, with history of increase in size of the lump since two to three months. It was associated with fever since 3 days. There was no history of cough with expectoration and weight loss. Physical examination revealed a palpable firm, irregular lump in the subareolar region of the left breast, measuring about 4 cm, accompanied by ulceration of the overlying skin and discharging sinuses (Figure 1).

Laboratory workup revealed normocytic normochromic RBC picture (Ht 40%, Hb 12 g/dl), leucocytosis with lymphocytosis, Erythrocyte Sedimentation Rate =50 mm/ 1st h. Mammography report was not available with patient. The patient was sent for FNAC with clinical differentials of carcinoma or abscess. FNAC was done under aseptic precautions using standard techniques. Smears were stained with Leishman stain. Smears showed extensive areas of necrosis and numerous neutrophilic inflammatory cells, few histiocytes and degenerated inflammatory cells (Figure 2). Smears were subjected to modified Ziehl Neelsen staining and to our surprise there were occasional acid fast bacilli (Figure 3). The diagnosis of tubercular breast abscess was made.

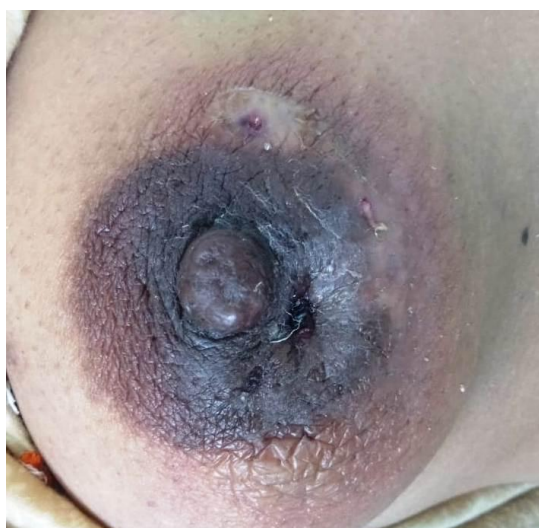

Figure 1: Discharging sinus in nipple areola area.

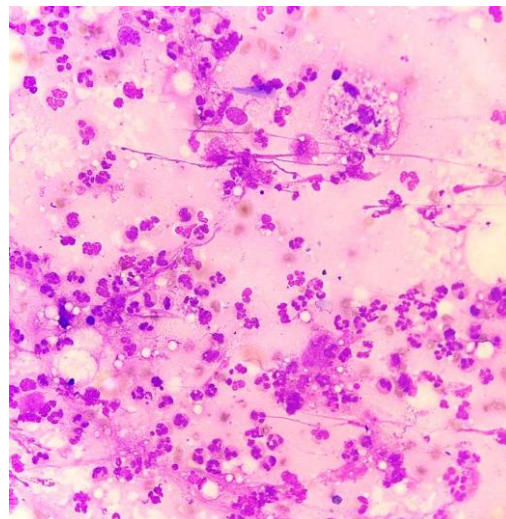


Figure 2: Microphotograph showing dense neutrophilic infiltrate and histiocytes (H&E; 40X).

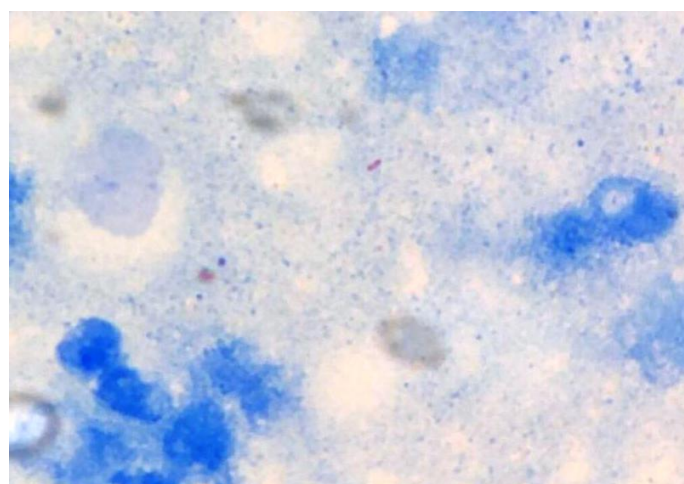


Figure 3: Microphotograph showing occasional acid fast bacilli on Modified Ziehl Neelsen stain (ZN stain; 100X).

Discussion

Tuberculosis of the breast is a rare entity as survival and multiplication of the tubercle bacilli is difficult in breast.^{4,5} Lactating women are most commonly affected probably due to the increased blood supply to the breasts.² It seldom infects male.⁶ The patients commonly present with a lump that may be painful or not associated with pain, most often in central quadrant. The lump can mimic breast carcinoma, being hard, with irregular border, fixed to either the skin or the muscle or even to the chest wall.^{7,8} Fistula, discharging sinuses, nipple or skin retraction, ulceration can be other presenting signs, but

breast discharge is uncommon.² Mammary tuberculosis is usually secondary to pulmonary tuberculosis but there has been reports of primary breast tuberculosis where it is considered to be caused by infection of the breast through skin abrasions.^{2,4} The routes of secondary tuberculosis of breast are hematogenous, lymphatic, by direct extension from the thoracic wall or the axillary lymph nodes.^{4,7,9}

Breast tuberculosis was originally classified by Makennn *et al.* into five categories: Acute miliary, Nodular, Sclerosing, Disseminated and Tuberculous mastitis obliterans.¹⁰ Nodular is the most common type which was present in our case. It presents as a localized lump with or without sinuses in one quadrant of the breast.

It is difficult to make definitive diagnosis of breast tuberculosis on radiological and clinical grounds. The gold standard is demonstration of *M. tuberculosis* by Ziehl Neelsen either by microscopy, culture or molecular studies (PCR). Microscopy and culture of *M. tuberculosis* has limitations of false-negative results in paucibacillary samples.⁴ Polymerase chain reaction (PCR) is highly sensitive for the diagnosis of breast tuberculosis.

Conclusion

Mammary tuberculosis is rare disease. It can be deceptive to radiologist and surgeons as it can mimic carcinoma. Other diseases of the breast such as fatty necrosis, plasma cell mastitis, periareolar abscess, idiopathic granulomatous mastitis and infections like actinomycosis and blastomycosis are to be considered with dealing with tubercular mastitis.^{1,4}

Financial Support and Sponsorship: Nil.

Conflicts of Interest: There are no conflicts of interest

References

1. Luh SP, Chang KJ, Cheng JH, Hsu JD, Huang CS. Surgical treatment for primary mammary tuberculosis – report of three

- octogenarian cases and review of literature. *Breast Journal* 2008; 14: 311–12.
2. Maroulis I, Spyropoulos C, Zolota V, Tzorakoleftherakis E. Mammary tuberculosis mimicking breast cancer: a case report. *Journal of Medicine Case Reports* 2008; 2: 34.
3. Cooper A. *Illustrations of the diseases of the breast.* London: Longman, Rees, Orme, Brown and Green; 1829.
4. da Silva BB, Lopes-Costa PV, Pires CG, Pereira-Filho JD, dos Santos AR. Tuberculosis of the breast: analysis of 20 cases and a literature review. *Transactions of the Royal Society of Tropical Medicine and Hygiene* 2009; 103: 559–63.
5. Madhusudhan KS, Gamanagatti S. Primary breast tuberculosis masquerading as carcinoma. *Singapore Medical Journal* 2008; 49:3–5.
6. Mirsaeidi SM, Masjedi MR, Mansouri SD, Velayati AA. Tuberculosis of the breast: report of 4 clinical cases and literature review. *East Mediterranean Health Journal* 2007; 13: 670–76.
7. Jah A, Mulla R, Lawrence FD, Pittam M, Ravichandran D. Tuberculosis of the breast: experience of a UK breast clinic serving an ethnically diverse population. *Annals of the Royal College of Surgeons of England* 2004; 86: 416–19.
8. Teo TH, Ho GH, Chaturverdi A, Khoo BK. Tuberculosis of the chest wall: unusual presentation as a breast lump. *Singapore Medical Journal* 2009; 50: 97–99
9. Fadaei-Araghi M, Geranpayeh L, Irani S, Matloob R, Kuraki S. Breast tuberculosis: report of eight cases. *Archives of Iranian Medicine* 2008; 11: 463–65.
10. Kakkar S, Kapila K, Sing MK, Verma K. Tuberculosis of the breast. A cytomorphological study. *Acta Cytol* 2000; 44: 292-96.