



## Evaluation of the Diagnostic Role of Ultrasonography Compared to Magnetic Resonance Imaging in Plantar Fasciitis

Authors

**Mai Darwish, Mohammed E. Eid, Tamer Y. Gaweesh, Abdelaziz El Nekeidy**

Department of Radio-diagnosis, Faculty of Medicine, Alexandria University, Egypt

### Abstract

**Objective:** *The aim of the study was to assess the role of ultrasonography in the diagnosis of plantar fasciitis in comparison to the diagnostic magnetic resonance imaging (MRI) in patients with chronic heel pain.*

**Methods:** *This study was conducted on 21 patients clinically diagnosed as plantar fasciitis from November 2013 till February 2015. Five age- and sex-matched asymptomatic volunteers served as a control group. Patients were examined by sagittal ultrasonography and conventional MRI (T1WI, T2WI and PDW-SPAIR sequences). MRI was considered the gold standard for diagnosis. And the sonographic appearances of the plantar fascia were compared with MRI findings. Plantar fascia thickness was also measured by both imaging modalities.*

**Results:** *The plantar fascia was thicker in symptomatic feet (2.50 – 9.30 mm;  $6.00 \pm 1.54$ ) than in the control group (1.70 – 3.80 mm;  $3.08 \pm 0.91$ ) as measured by ultrasound. Other sonographic signs used for the diagnosis of plantar fasciitis in the study were compared to MRI findings. The diagnostic accuracy was 85.71% for abnormal focal thickening and abnormal echogenicity within the plantar fascia, 76.19 % for soft tissue edema and the lowest diagnostic accuracy of ultrasound was in the detection of associated calcaneal spur (38.10%). Compared with MRI, ultrasonography showed 89.47 % sensitivity and 50% specificity in assessing plantar fasciitis, with overall diagnostic performance of 85.71%. These findings were tabulated and discussed in relation to other literature.*

**Conclusion:** *Although MRI is the modality of choice in the diagnosis of plantar fasciitis, diagnostic accuracy of ultrasound is comparable to that of MRI and it could be the initial imaging modality to confirm clinically suspected plantar fasciitis. MRI may be reserved for equivocal cases, symptomatic cases with negative ultrasound results and when complex pathology is suspected.*

**Keywords:** *MRI, plantar fasciitis, ultrasound.*

### Introduction

Plantar fasciitis is the most common cause of chronic plantar heel pain,<sup>(1)</sup> typically presented as morning pain on the undersurface of the heel, on weight bearing or pain at the beginning of activity after a period of rest.<sup>(2)</sup> It is known to affect

middle-aged women and younger, predominantly male, runners.<sup>(3)</sup> It can arise either from repetitive stress or as an enthesopathy in association with sero-negative spondyloarthropathies.<sup>(4,5)</sup> A thorough clinical examination usually provides correct diagnostic orientation, however it maybe

mimicked by a number of disorders.<sup>(6)</sup> The role of radiology is to make an accurate diagnosis as early as possible because effective treatment of plantar fasciitis requires precise diagnosis and differentiation from other causes of heel pain.<sup>(7)</sup> The imaging techniques available are plain radiography, magnetic resonance imaging (MRI) and ultrasound (US).<sup>(8)</sup> Radiography may reveal a plantar calcaneal spur, however the etiologic significance of this spur remains controversial.<sup>(4,9)</sup> Direct imaging of the plantar fascia is possible with MRI and US.<sup>(8)</sup> These methods have revealed that the plantar fascia is thicker in patients with plantar fasciitis than in those without plantar fasciitis.<sup>(10,11)</sup> The advantages of US compared to MRI are that it is a readily available cost-effective approach that is also well tolerated by patients.<sup>(12)</sup> In this study, we compare high-resolution ultrasound to MRI to assess its value as an alternative modality to confirm a clinical diagnosis of plantar fasciitis using the MRI findings as a reference standard.

### Patients and Methods

This study was conducted on 21 patients (7 males and 14 females) aged 30 to 58 years (42.76 ± 6.88) years clinically diagnosed as plantar fasciitis and were referred to the department of Radiodiagnosis, Faculty of medicine, Alexandria University. Selection criteria excluded patients with histories of local inflammation, trauma and/or heel surgery and patients with systemic diseases e.g. Diabetes Mellitus or chronic ischemia. Five age- and sex- matched asymptomatic volunteers served as a control group to provide a baseline to the normal appearance of the plantar fascia. Each patient was subjected to: Full history taking and thorough clinical examination. Informed consent was obtained from each subject imaged under the research protocol. Radiologic examination was fulfilled prospectively from November 2013 till February 2015. Sonograms and MR images were evaluated independently by 2 different radiologists. MR images were interpreted by an

experienced musculoskeletal radiologist. Ultrasonography was performed by a 4-year radiology resident who was taught how to approach the sonographic examination of the plantar fascia before the study. Sonographic and MRI examinations were performed on the same day.

Sagittal ultrasonography of the heel was performed with a Phillips HD11 XE (Best, Netherlands) scanner using a 12-MHz linear transducer. Tissue harmonics settings were used. The patients lay supine or sat with their legs flexed and rested on the examination table; their feet were supported on the table with their ankles dorsiflexed to 90°. Thickness of the plantar fascia was measured at a standard reference point, where the plantar fascia crosses the anterior aspect of the inferior border of the calcaneus.

Conventional MRI of the foot was performed on a 1.5T Philips Gyroscan Achieva (Best, Netherlands) closed configuration whole body scanner using an extremity coil. A limited protocol specially designed for the study was used: Sagittal mortice oblique T1WI (TR: 500-650 msec, TE: 20 msec), Sagittal mortice oblique PDW-SPAIR images (TR: 3000- 5500 msec, TE: 30 msec), Coronal T1WI (TR: 500-650 msec, TE: 20 msec), Coronal T2WI (TR: 3500 msec, TE: 100 msec) and Coronal PDW-SPAIR images (TR: 3000-5500 msec, TE: 30 msec). In the sagittal oblique view the direction of the oblique plane ran parallel to the long axis of the mortice joint. Images were interpreted by dedicated workstation & post processing software. Measurements were taken at the same location on MRI as taken on ultrasound. The maximum thickness of the plantar fascia, presence or absence of focal thickening, abnormal signal intensity, and adjacent soft tissue edema were recorded in both modalities. Associated calcaneal spurs and/or any other incidentally detected pathology that might be responsible for the patient complaint was reported. The medical ethics was considered. The patient was aware of the examination, patient's approval was obtained.

**Statistics**

MedCalc® statistical software (Ostend, Belgium) was used for the calculation of mean values, standard deviations and range for age, body weight and sonographic and MRI measurements of the plantar fascia. Frequency distribution for sex was also calculated. Findings related to plantar fasciitis from both imaging modalities were compared and the sensitivity, specificity and diagnostic accuracy of ultrasonography were assessed.

**Results**

The study showed that the thickness of the plantar fascia in symptomatic feet as measured by ultrasound and MRI, respectively (2.50 – 9.30 mm; 6.00± 1.54) and (2.40–9.40 mm; 6.00± 1.58) was significantly thicker than in the control group (1.70 – 3.80 mm; 3.08± 0.91). (Table 1)

Abnormal focal thickening of the plantar fascia and intra-fascial abnormal signal were detected by both MRI and ultrasonography in 17 patients (81%), by MRI only in 2 patients (9.5 %),

False positive result by ultrasound in one patient (4.75%), When MRI was considered as a reference, the statistical diagnostic accuracy of ultrasound was 85.71%. Adjacent soft tissues edema was detected by both ultrasonography and MRI in 12 patients (57.14%) and by MRI only in 5 patients (23.81%), with a statistical diagnostic accuracy of ultrasound reaching 76.19 %.Underlying bone marrow edema wasn't detected by ultrasound in any of the cases; however it was detected by MRI in 7 cases (33.33%), (statistical diagnostic accuracy of 66.67 %). Bony calcaneal spurs were detected by both ultrasound and MRI in 5 heels (23.81%). Thirteen heels (61.90%) showed bony calcaneal spurs by MRI only (statistical diagnostic accuracy 38.10 %). (Tables 2 and 3). In our study, the diagnosis of plantar fasciitis by ultrasonography was established when the plantar fascia thickness was more than 4 mm with reduced echogenicity. According to the statistics and considering MRI as the gold standard for the diagnosis, ultrasound proved to have sensitivity of 89.47% and 50% specificity in the diagnosis of plantar fasciitis, with overall diagnostic accuracy of 85.71%.(Table 4)

**Table (1):** Descriptive analysis of the studied cases according to thickness of planter fascia measured by ultrasound and MRI in symptomatizing and control groups (n=26)

Thickness of planter fascia	Ultrasound		MRI	
	Symptomtizing group (21 heels)	Control group (5 heels)	Symptomtizing group (21 heels)	Control group (5 heels)
Min. – Max.	2.50 – 9.30	1.70 – 3.80	2.40– 9.40	1.50 – 4.0
Mean ± SD	6.00± 1.54	3.08±0.91	6.00± 1.58	3.04± 1.06
Median	5.70	3.60	5.80	3.50

**Table (2):** Distribution of the studied cases according to incidence of diagnostic signs in ultrasound and MRI (n=21)

	Ultrasound only	MRI only	Both positive	Both negative	Total
Focal thickening	1	2	17	1	21
Intra-fascial abnormal signal	1	2	17	1	21
Soft tissue edema	0	5	12	4	21
Calcaneal spur	0	13	5	3	21

**Table (3):** Diagnostic accuracy of ultrasound for different diagnostic signs compared to MRI

Ultrasound statistics	Diagnostic accuracy %
Focal thickening	85.71
Intra-fascial abnormal signal	85.71
Soft tissue edema	76.19
Underlying calcaneal BM edema	66.67
Calcaneal spur	38.10

**Table (4a):** Descriptive analysis of overall diagnostic performance of ultrasound compared to MRI according to No. of cases (n=21)

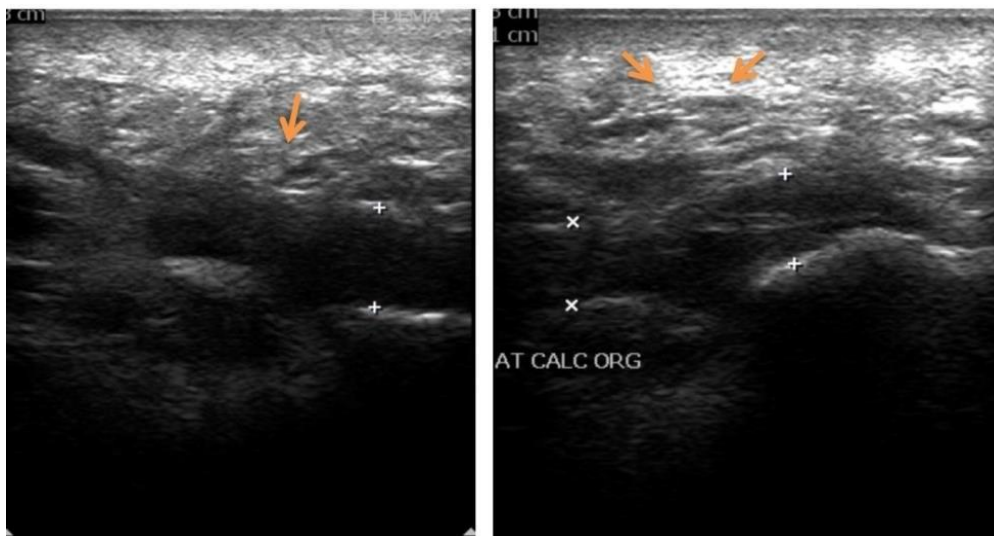
	True positive	True negative	False positive	False negative
No. of cases	17	1	1	2

**Table (4b):** Descriptive analysis of overall diagnostic performance of ultrasound compared to MRI according to percent

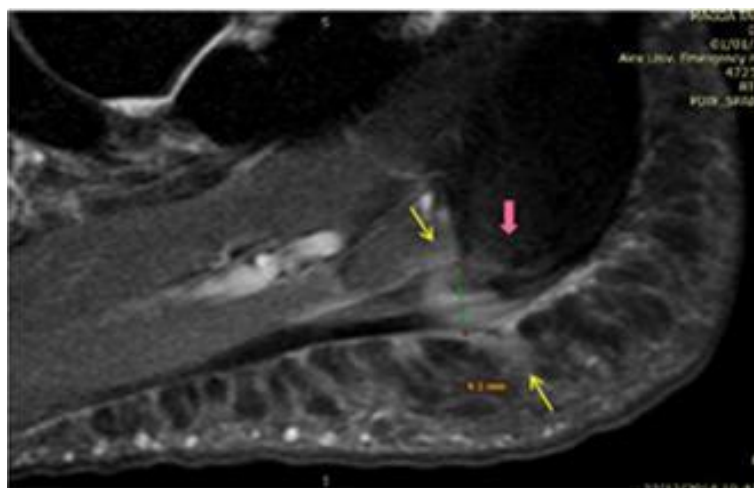
Sensitivity	Specificity	Accuracy
89.47 %	50%	85.71%

**Case (1)**

**Illustrative cases**



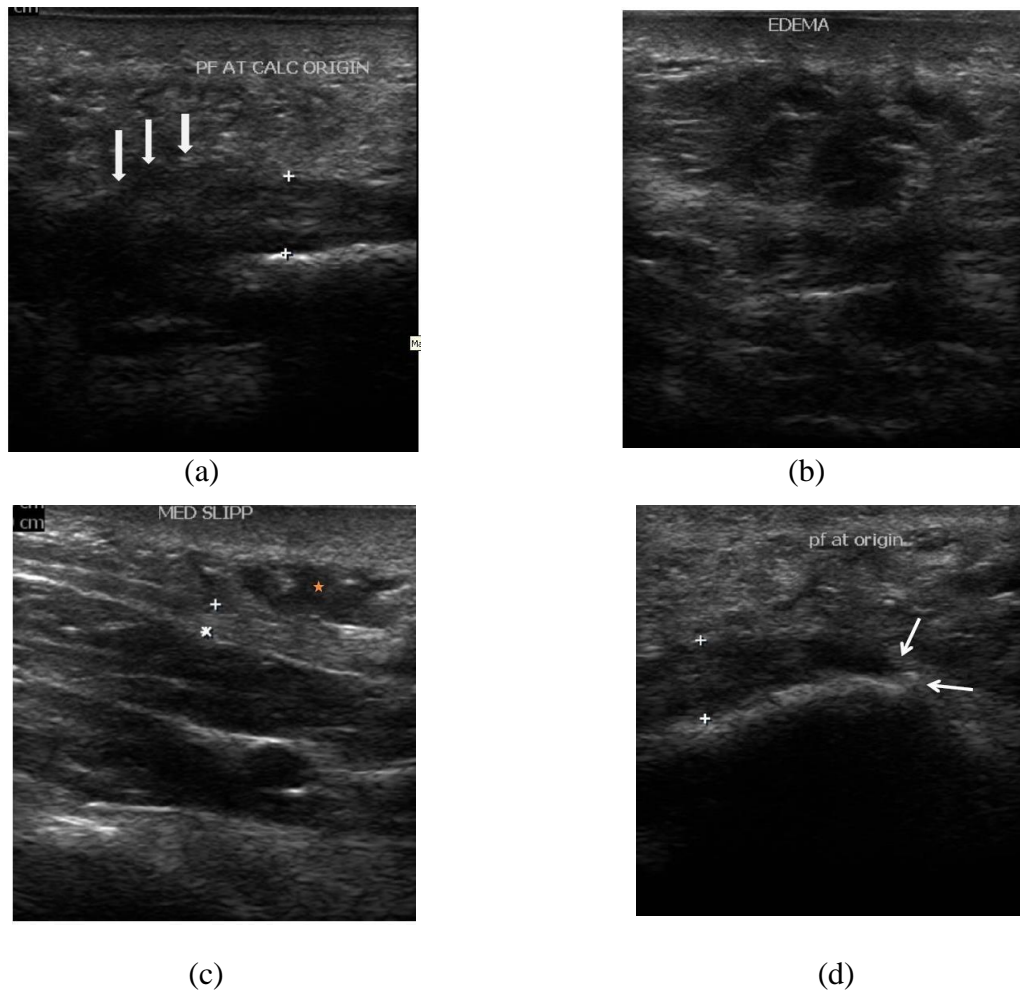
**Figure 1:** A 50 year old female patient presented by right heel pain, sagittal ultrasonography of the right heel revealed prominent focal thickening of the plantar fascia (9.2 mm) at its calcaneal origin showing hypo-echoic changes (cursors). Associated soft tissue edema is also noted (arrows).



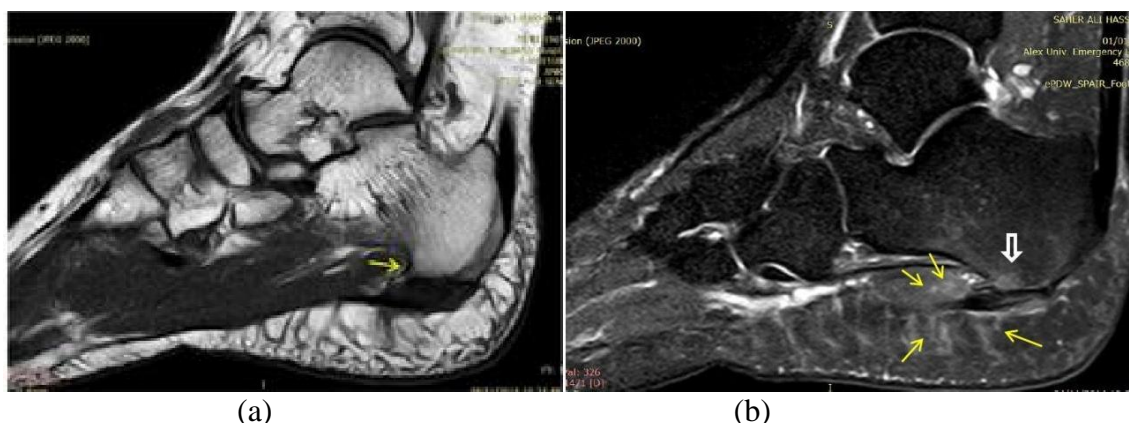
**Figure 2:** Sagittal (PDW - SPAIR) MR images of the same patient showing focal thickening of the plantar fascia at its calcaneal origin (9.5 mm) with abnormal high signal intensity, this is associated with signal intensity changes in the peri-fascial soft tissues reflecting soft tissue edema (thin arrows).Hyper-intense signal of the underlying calcaneal attachment indicates calcaneal bone marrow edema (thick arrow).



Case (2)



**Figure 3:** A 49 year old female patient presented by left heel pain that was worst in the morning and after prolonged physical activity. Sagittal ultrasonography of the left heel revealed (a) prominently thickened hypo-echoic plantar fascia at its calcaneal origin measuring (7.1 mm) (cursors) with loss of edge sharpness of the fascia (thick arrows). (b) Associated subcutaneous edema, (c) localized fluid collection (star) and (d) bony calcaneal spur (thin arrows) were also noted by ultrasonography.



**Figure 4:** (a) T1-weighted sagittal MR image of the plantar fascia showing focal thickening of the plantar fascia. Associated calcaneal spur was also noted (arrow). (b) Sagittal PDW-SPAIR image showing: the increased intra-substance signal intensity of the thickened plantar fascia with surrounding hyper-intense peri-fascial soft tissue edema (thin arrows). The abnormal high marrow signal intensity at the calcaneal insertion reflecting underlying bone marrow edema was also noted (thick arrow).

## Discussion

Classically the diagnosis of plantar fasciitis was based on the patient's history and clinical examination, it is typically presented as morning pain on the undersurface of the heel that eases by walking and increases with prolonged physical activity. <sup>(2)</sup> However, this is mimicked by a number of disorders. <sup>(13,14)</sup> Therefore different imaging modalities have been used for confirming the diagnosis of plantar fasciitis. In the current study ultrasonography and MRI were used to confirm the diagnosis of plantar fasciitis and to evaluate efficacy of ultrasound in the detection of plantar fasciitis compared with MRI findings in 21 patients clinically diagnosed as plantar fasciitis.

Reported normal measurements of the plantar fascia varied; in the current study, mean thickness of the plantar fascia in the control group was (3.08mm±0.91) by ultrasound and (3.04mm± 1.06) by MRI. It was reported by Afrikat et al. as (3.62 ± 0.68 mm), <sup>(15)</sup> by Abdel-Wahab et al. (1.7mm ± 0.06)<sup>(16)</sup> and by Cardinal et al.(2.6 mm ± 0.48).<sup>(14)</sup> Reported values of fascia thickness in plantar fasciitis also varied; in the current study the mean value was (6.27mm± 1.28) and (6.29mm± 1.29) by ultrasound and MRI, respectively. Blankenbaker and Smet reported a mean value of 5.2 mm, <sup>(17)</sup> Gibbon et al. 4.68 mm,<sup>(18)</sup> Berkowitz et al. 7.4 mm,<sup>(13)</sup> Cardinal et al. 5.2 mm <sup>(14)</sup> and Abdel-Wahab et al. 4.9 mm.<sup>(16)</sup> These differences may be related to the small number of patients in each study. In our study the imaging characteristics of plantar fasciitis were: fascial thickening exceeding 4 mm with signal changes of the plantar fascia manifested as hyper-intense signal in T2WI and PDW-SPAIR images &/or intermediate signal in T1WI by MRI and reduced echogenicity by ultrasound. Many previous studies also used these criteria as diagnostic parameters in plantar fasciitis.<sup>(13-15,19-26)</sup> Other imaging findings that indicate plantar fasciitis included edema of the adjacent fat pad and underlying soft tissues and limited marrow edema within the medial calcaneal tuberosity.<sup>(22)</sup> We correlated sonographic findings with those of MRI. In the current study, abnormal focal thickening of the plantar fascia and intra-fascial abnormal signal were

detected in 81% of patients by ultrasound and MRI, in

9.5 % of the patients by MRI only due to the lower sensitivity of the ultrasound in the detection of minimal thickening and minimal signal intensity changes, and in one patient (4.75%) by ultrasound only (false positive) that maybe due to a technical reason. One patient (4.75%) showed normal thickness and echogenicity of the plantar on ultrasound and MRI, although the patient was clinically diagnosed as plantar fasciitis, which was due to associated heel pad fibrosis that was responsible for the pain. The hypoechoic changes of the plantar fascia by ultrasonography were frequent findings in our study (81%). These findings were in accordance with those of Cardinal et al.<sup>(14)</sup>, Akfirat et al.<sup>(15)</sup>, Sabir et al.<sup>(26)</sup>, Tsai et al.<sup>(27)</sup> and Abdel-Wahab et al.<sup>(16)</sup> However; the hypoechoic changes were not constant features as reported by Gibbon and Long.<sup>(24)</sup>

Peri-fascial edema and/or edema in the adjacent soft tissues were detected by ultrasonography in 57.14% of the patients and by MRI in 81% of the patients; this was due to the higher sensitivity of MRI in detecting minimal fluid signal changes. It was reported by ultrasonography by Abdel-Wahab et al in 60.8% of the patients, <sup>(16)</sup> and by Sabir et al. in 29.9% of the patients. <sup>(26)</sup> However it wasn't a frequent finding as reported by Gibbon and Long (5%),<sup>(24)</sup> by Akfirat et al. (10%)<sup>(15)</sup> and by Ozdemir et al. in 2.5% of the cases. <sup>(28)</sup> The difference is mostly because we considered peri-fascial edema and/or edema in the adjacent soft tissues a single finding, because both are part of fascial and peri-fascial inflammation.

We reported Bony calcaneal spurs by ultrasonography in 23.81% of the cases, Gibbon and Long reported them in 24 % of the cases <sup>(24)</sup> and Ozdemir et al. in 51% of the cases. <sup>(28)</sup>

In the current study, the diagnosis of plantar fasciitis by ultrasonography was established when the plantar fascia thickness was more than 4 mm with reduced echogenicity. According to the statistics and considering MRI as the gold standard for the diagnosis of plantar fasciitis; 80.96% of the cases gave positive findings in both

ultrasound and MRI (true positive) and 4.76% of them gave negative results by both ultrasound and MRI despite the clinical diagnosis of plantar fasciitis (true negative). Sabir et al. reported (true positive) in 37.93% of the cases and true negative results in 45.5% of the cases. <sup>(26)</sup> This may be attributed to the proper selection of cases in the current study, in which the clinical presentation typically matches the classical pain of plantar fasciitis as well as the advanced machines used in the current study. In our study, 4.76% of the cases gave false positive sonographic findings, while Sabir et al. reported positive results in 7.58% of the cases. <sup>(26)</sup> This may be due to the advanced ultrasound devices used in the current study using tissue harmonics settings.

In the current study 9.52% of the cases gave positive findings by MRI that weren't detected by ultrasound (false negative), which agreed with Sabir et al. who reported false negative results in 8.96% of the cases. <sup>(26)</sup>

We compared ultrasound and MRI with respect to their accuracy and validity in the detection of plantar fasciitis. That was held as well by Sabir et al. <sup>(26)</sup> and Abdel-Wahab et al. <sup>(16)</sup> Ultrasound sensitivity and specificity were reported to be 80.9% and 85.7%, respectively, in Sabir et al. <sup>(26)</sup>

In the current study, sensitivity was higher reaching 89.47% and specificity was as low as 50%. The statistical diagnostic accuracy of ultrasound was also reported to be 69.5% in the study carried out by Abdel-Wahab et al. <sup>(16)</sup> However in the current study it was reported to reach 85.71%. Those differences may be due to the different number of cases in each study.

### Conclusion

Increased plantar fascia thickness and hypoechoic plantar fascia are consistent sonographic findings in patients with plantar fasciitis, which are sufficient information for the physician to confirm an initial diagnosis of plantar fasciitis. Therefore, ultrasonography can be the first step for plantar fasciitis because it is noninvasive, less expensive, readily available, easier, and faster than other

imaging modalities. These all suggest that ultrasonography is capable of confirming or excluding plantar fasciitis. However, it still can't substitute MRI in the diagnosis of plantar fasciitis, because it can't detect minimal thickening and minimal signal changes of the plantar fascia. Equivocal cases of plantar fasciitis and symptomatic cases with negative ultrasound results should undergo further assessment with MRI. Also patients with other heel pathologies mimicking the pain of plantar fasciitis couldn't be adequately diagnosed only on ultrasound basis.

### References

1. Singh D, Angel J, Bentley G, Trevino S. Fortnightly review: plantar fasciitis. *Br Med J* 1997; 315:172-5.
2. Ragab EMS, Othman AMA. Platelets rich plasma for treatment of chronic plantar fasciitis. *Arch Orthop Trauma Surg* 2012; 132: 1065–70.
3. Tanz SS. Heel pain. *ClinOrthop* 1963; 28:169-78.
4. Karr SD. Subcalcaneal heel pain. *OrthopClin North Am* 1994; 25:161–73.
5. Gerster JC, Vischer TL, Bennani A, Fallet GL. The painful heel: comparative study in rheumatoid arthritis, ankylosing spondylitis, Reiter's syndrome, and generalized osteoarthritis. *Ann Rheum Dis* 1977; 36:343–8.
6. Buckup K. Clinical tests for musculoskeletal system. New York: Thieme; 2004.
7. Barret SL, O'Malley R. Plantar fasciitis and other causes of heel pain. *AmFam Physician* 1999; 59:2200–6.
8. McMillan AM, Landorf KB, Barrett JT, Menz HB, Bird AR. Diagnostic imaging for chronic plantar heel pain: a systematic review and meta-analysis. *J Foot Ankle Res* 2009;2:32.
9. Schepsis A, Leach RE, Gorzyca J. Plantar fasciitis: etiology, treatment, surgical results, and review of the literature.

- ClinOrthopRel Res 1991; 266:185–96.
10. Cheng JW, Tsai WC, Yu TY, Huang KY. Reproducibility of sonographic measurement of thickness and echogenicity of the plantar fascia. *J Clin Ultrasound* 2012; 40: 14–9.
  11. Wu CH, Chang KV, Mio S, Chen WS, Wang TG. Sonoelastography of the plantar fascia. *Radiology* 2011; 259: 502–7.
  12. Fabrikant JM, Park T. Plantar fasciitis (fasciosis) treatment outcome study: plantar fascia thickness measured by ultrasound and correlated with patient self-reported improvement. *Foot* 2011; 21: 79–83.
  13. Berkowitz JF, Kier R, Rudicel S. Plantar fasciitis: MR imaging. *Radiology* 1991; 179:665–7.
  14. Cardinal E, Chhem RK, Beauregard CG, Aubin B, Pellitier M. Plantar fasciitis: sonographic evaluation. *Radiology* 1996; 201: 257–9.
  15. Akfirat M, Sen C, Gunes T. Ultrasonographic appearance of the plantar fasciitis. *Clin Imaging* 2003; 27(5):353-7.
  16. Abdel Wahab N, Fathi S, Al Emadi S, Mahdi S. High resolution ultrasonographic diagnosis of plantar fasciitis: a correlation of ultrasound and magnetic resonance imaging. *Int J Rheum Dis* 2008;11(3):279-86.
  17. Blankenbaker DG, De Smet AA. The role of ultrasound in the evaluation of sports injuries of the lower extremities. *Clin Sports Med* 2006; 25: 867–97.
  18. Gibbon WW. Plantar fasciitis: US imaging (letter). *Radiology* 1992; 182: 285.
  19. Kier R. Magnetic resonance imaging of plantar fasciitis and other causes of heel pain. *MagnReson Imaging Clin N Am* 1994; 2: 97–107.
  20. Narvaez JA, Narvaez J, Ortega R, Aguilera C, Sanchez A, Andia E. Painful heel: MR imaging findings. *Radiographics* 2000;20(2):333-52.
  21. Theodorou DJ, Theodorou SJ, Resnick D. MR imaging of abnormalities of the plantar fascia. *Semin Musculoskelet Radiol* 2002; 6(2):105–18.
  22. Roger B, Grenier P. MRI of plantar fasciitis. *EurRadiol* 1997; 7:1430–5.
  23. Kane D, Greaney T, Shanahan M, Duffy G, Bresnihan B, Gibney R, et al. The role of ultrasonography in the diagnosis and management of idiopathic plantar fasciitis. *Rheumatology* 2001; 40(9):1002-8.
  24. Gibbon WW, Long G. Ultrasound of the plantar aponeurosis (fascia). *Skeletal Radiol* 1999; 28(1):21-6.
  25. Erdem CZ, Sarikaya S, Erdem LO, Ozdolap S, Gundogdu S. MR imaging features of foot involvement in ankylosing spondylitis. *Eur J Radiol* 2005; 53: 110–9.
  26. Sabir N, Demirlenk S, Yagci B, Karabulut N, Cubukcu S. Clinical utility of sonography in diagnosing plantar fasciitis. *J Ultrasound Med* 2005; 24: 1041–8.
  27. Tsai W, Chiu MF, Wang C, Tang F, Wong M. Ultrasound evaluation of plantar fasciitis. *Scand J Rheumatol* 2000; 29: 255–9.
  28. Ozdemir H, Yilmaz E, Murat A, Karakurt L, Poyraz AK, Ogur E. Sonographic evaluation of plantar fasciitis and relation to body mass index. *Eur J Radiol* 2005; 54(3):443-7.