



## A rare case of Primary Leptomeningeal Precursor B cell Lymphoblastic Lymphoma in a Pediatric Patient – Case report and Literature review

Authors

**Malathi Mukunda Pai, Ashwini Nargund, Akkamahadevi Patil, Padma Maneya\*\*,  
Madhumathi Davanam Sathyanarayan\***

Division of Cytology & \*Division of Haematopathology, Department of Pathology,

\*\*Department of Paediatric Oncology, Kidwai Cancer Institute, Bengaluru, Karnataka, India

Corresponding Author

**Dr Ashwini Nargund**

Associate Professor, Department of Pathology, Dr M H Marigowda road, Kidwai Cancer Institute, Bengaluru, India

### Abstract

*We present a 4 year obese child, with no mass lesion in brain/CNS, normal chest, abdomen & normal peripheral smear, Bone marrow aspirate. There was Subdural Collection and enhancement. CSF cytology showed lymphoma/leukemic infiltration, Immunophenotyping was Precursor B cell lymphoma involving meninges. FISH study showed abnormal signal pattern for BCR-ABL gene indicating trisomy 9.*

**Keywords:** CSF cytology; obese child; Immunophenotyping, B cell lymphoma.

### Introduction

Non-Hodgkin lymphoma represent 15% of all childhood cancers, of which 35% are lymphoblastic lymphomas (5% B-cell LL) .CNS involvement occurs in about 5% of children with B-cell LL (lymphoblastic lymphoma). Primary leptomeningeal lymphoma (PLML) is a rare malignancy that exclusively involves the meninges without invasion into cerebral parenchyma or systemic involvement. The estimated incidence of PLML is 7% of all CNS lymphoma, which itself comprises approximately 2% of all primary brain tumours and 0.8% of all lymphomas. PLML usually presents with symptoms of increased intracranial pressure, rapidly progressive meningeal signs, and cranial nerve involvement. It is considered to have a poor

prognosis, with frequent systemic dissemination. Diagnostic methods for this rare disease include a thorough cytological examination of CSF, MRI, and CSF Immunophenotyping (IPT) including cytogenetics and/or leptomeningeal biopsy. We describe a rare case of PLML in a child who presented with obesity.

### Case Report

A previously healthy child was referred from neurology centre to our institute in the year 2016 to rule out CNS-LCH (Langerhan cell histiocytosis). She was 4 years and complained of progressive weight gain since 1 year, progressive diminution of vision since 6 months, transient weakness of right side of body since 1 week ago .Progressive weight gain since 1 year. This was

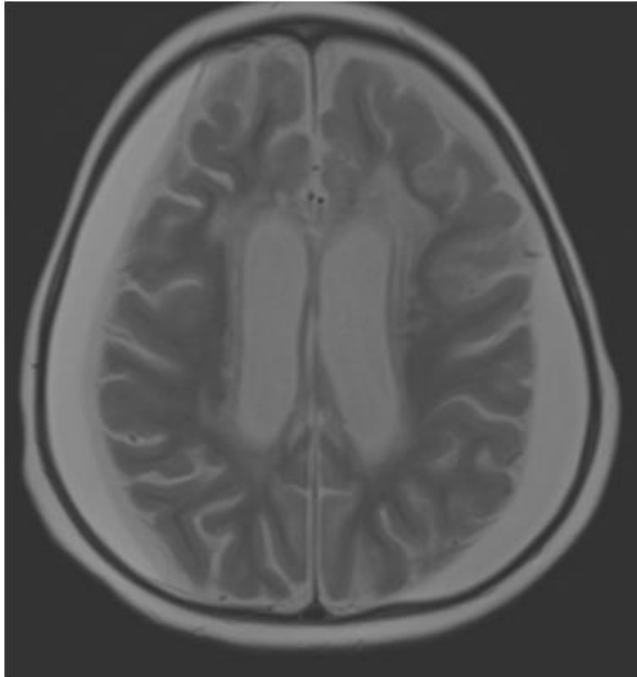
not associated with excessive hunger, no activity changes as compared to peers. Progressive diminution of vision since 6 months. Initially loss of interest in viewing television, subsequently recognized people with auditory cues only. Transient weakness of right side of body since 1 week ago lasted few hours. Followed by complete recovery of power and movement. No history of headache, altered behavior or seizures. Patient was born to parents of non-consanguineous marriage. She was born after an uneventful pregnancy and delivery. Her birth weight was 3kg. Developmental mile stones and immunisation was appropriate for age. The patient's weight, height, and head circumference were 27 kilograms (>97th percentile), 95 centimetres (3rd percentile), and 51 centimetres (>50th percentile) respectively.

**Clinical examination**, she was obese, conscious, alert and active. Vitals were as follows: BP – 90/60mmHg, PR – 120/min, RR – 20/min, Temp – 98.6 F. There was no evidence of dysmorphic features, no skin changes (Striae/acanthosis), no pallor, no peripheral lymphadenopathy, no external bleeds. BCG scar was present. Systemic examination revealed normal higher mental functions. Under Cranial nerves, bilateral fundus examination revealed optic atrophy, perception of light was preserved, and she was unable to count fingers. Rest of the cranial nerves were normal. Motor and sensory system was normal. No meningeal signs. Per Abdomen, there was no organomegaly. Cardiovascular system and respiratory systems were normal. She was referred from neurology center to rule out CNS-LCH to our Tertiary Cancer hospital.

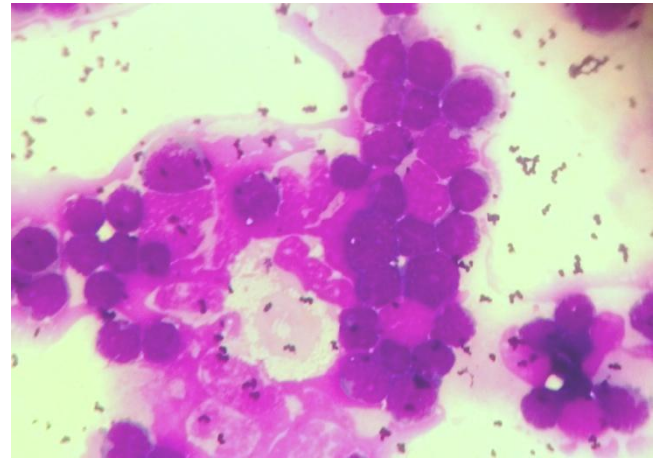
**Laboratory investigations:** Haemogram was within normal. Peripheral smear showed normocytic normochromic blood picture. All the biochemical & serological tests were normal except raised LDH of 565 U/ml. Bone marrow aspiration revealed normal Trilineage haematopoiesis. Cytogenetics of BMA showed 46, XX, normal Karyotype. Chest X-ray, Ultra

sound Abdomen, including CECT chest & abdomen were normal. Bone scan was normal. MRI Brain (Fig 1 & 2) showed subdural collection following CSF signal intensity noted in bilateral front parietal region measuring 12mm and 80 mm on right and left side respectively. Radiological findings were 1) Mild thickening and enhancement of infundibular stalk with absence of post pituitary bright spot. 2) Mild thickening of optic nerve at optic chiasm and optic chiasma. 3) Diffuse dural leptomeningeal enhancement. 4) Cortical atrophy. 5) Opacities of B/L maxillary and ethmoidal sinuses. The differential diagnosis rendered were 1) Intracranial LCH. 2) Granulomatous disease. 3) Leukaemia/lymphoma. 4) Chronic bilateral subdural collection.

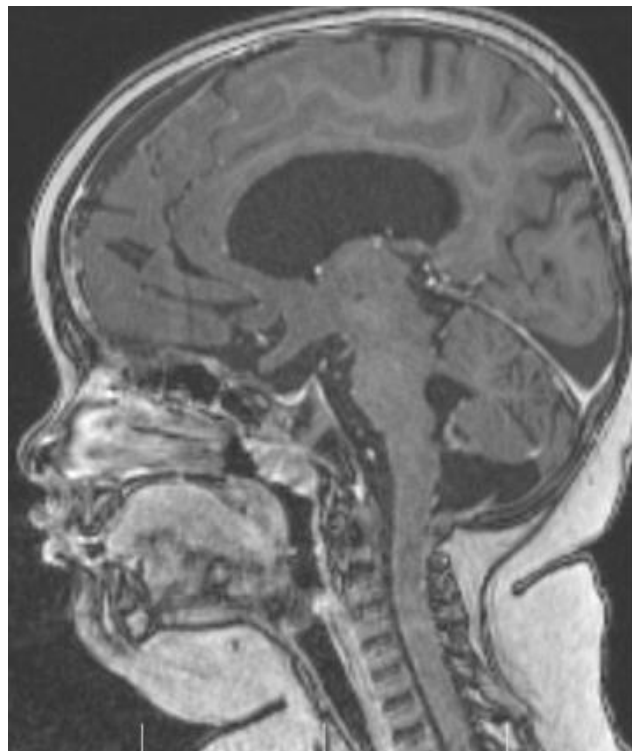**CSF Examination** revealed cell count of 650 cells /mm<sup>3</sup>, 98% abnormal lymphoid cells and 2% polymorphs. Cytomorphology showed large atypical lymphoid cells (blasts) having high N/C ratio and scant cytoplasm (Fig.3&4). Cytological impression of Lymphoma/Leukemic infiltration was given. Additional IPT and cytogenetic assay on CSF sample was suggested. IPT of CSF was done. The dim CD45 gated cells were positive for Tdt, CD19, CD79a and negative for CD34 CD10, CD5, cCD3, CD7. Correlating cytomorphology and IPT a diagnosis of Primary Leptomeningeal Precursor B cell lymphoblastic lymphoma was given (Fig.5). FISH on CSF was done. Probe hybridisation showed juxtaposition of red signals which does not indicate rearrangement of MLL gene at 11q23 and normal signals for TEL and RUNX1. Abnormal pattern for BCR and ABL gene was seen. (Fig. 6). FISH impression of abnormal signal pattern for BCR/ABL with 3R/2G signals indicating trisomy of 9 possibly hyperdiploidy clone was offered. Final Diagnosis of Primary Leptomeningeal Precursor B cell lymphoblastic lymphoma, Stage IV. Treatment options were given to patient's parents. Parents were not ready for the treatment and opted alternative therapy; however she succumbed to the disease in July 2017.



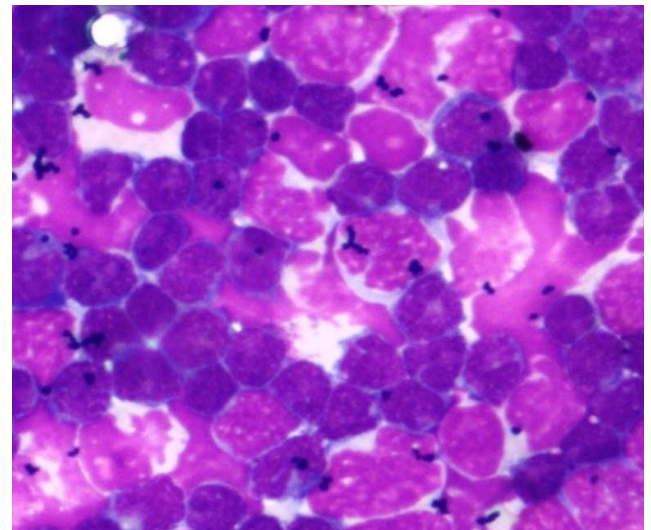
**Figure 1:** T2 axial image shows bilateral hyperintense subdural collection, with mass effect on the Brain and diffuse cerebral atrophy.



**Figure 3:** Photomicrograph of CSF smears showing lymphoblasts in sheets-MGG x100(first sample)



**Figure 2:** T1 Sagittal contrast image shows thickening of the optic apparatus



**Figure 4:** Photomicrograph of CSF smears showing lymphoblasts in sheets-MGG x100 (second sample)

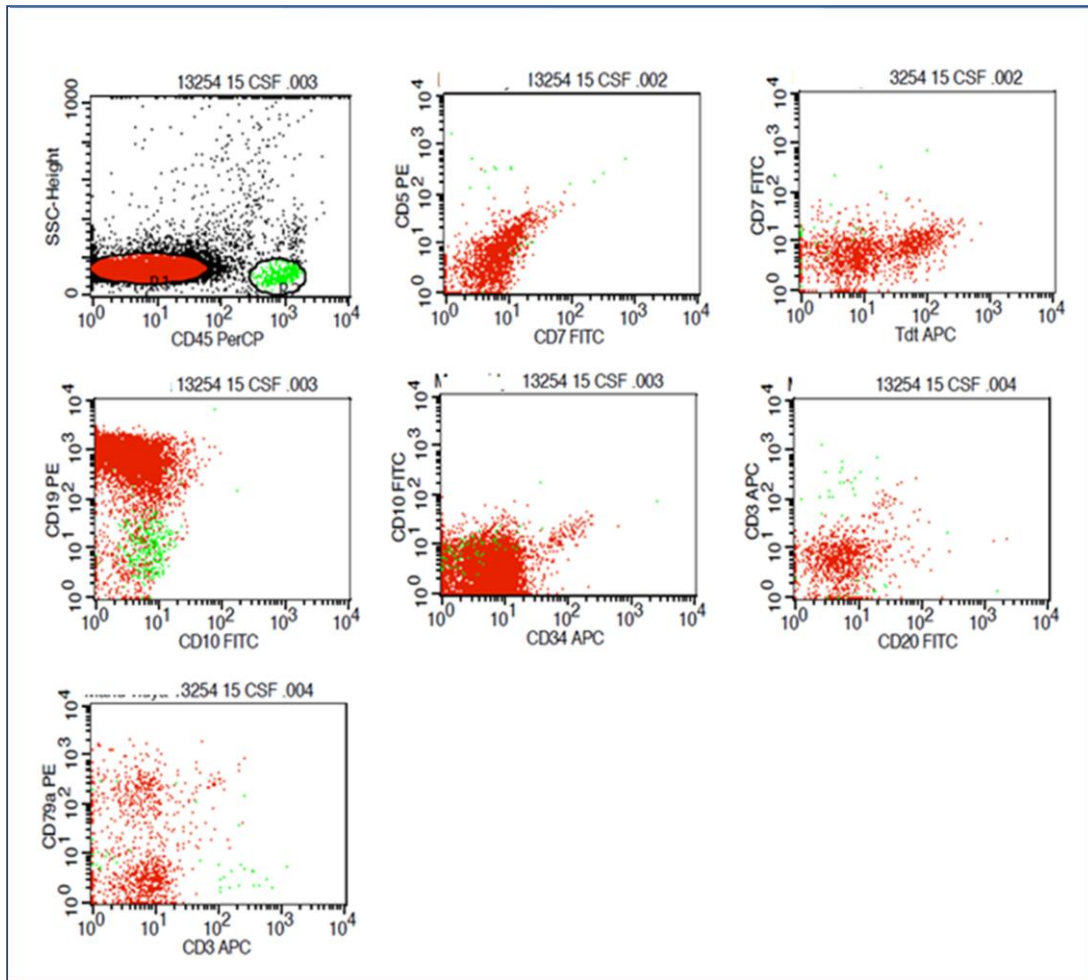


Figure 5: Immunophenotyping of CSF

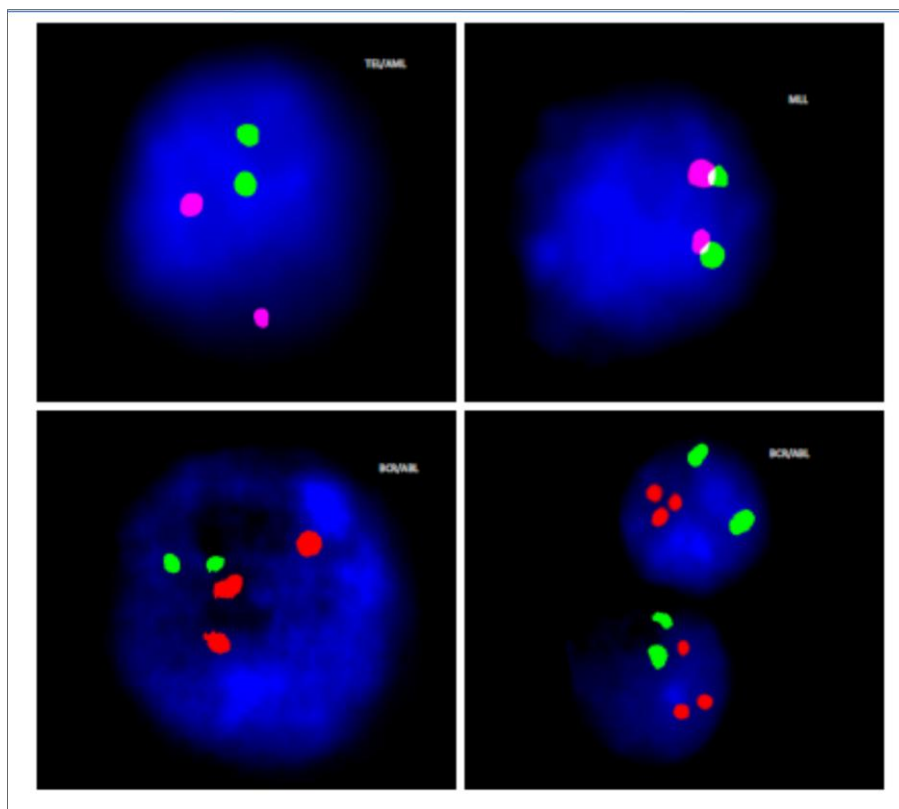


Figure 6: CSF FISH showing abnormal signal pattern for BCR-ABL gene indicating trisomy 9.

**Table 1:** Comparison study of PLML with other studies

Sl no	Case report /series	Age	No of cases	Diagnosis
1	<b>Troy C. Quigg et al</b>	3 yrs /M	1	B cell LL
2	Oussama Ablaetal	6yrs/M	1	B cell LL
3	Felice etal	12yrs F/7yrs F/4yrs/M	3	B cell LL
4	Oussama Ablaetal	Children/Adol	2	B cell LL
5	Taylor etal		1	LL
6	Our case	4yrs /F	1	B cell LL

## Discussion

Non-Hodgkin lymphoma represent 15% of all childhood cancers, of which 35% are lymphoblastic lymphomas (5% B-cell LL). CNS involvement occurs in about 5% of children with B-cell LL. Primary leptomeningeal lymphoma (PLML) is a rare malignancy that exclusively involves the meninges without invasion into cerebral parenchyma or systemic involvement. The estimated incidence of PLML is 7% of all CNS lymphoma, which itself comprises approximately 2% of all primary brain tumours and 0.8% of all lymphomas. Primary leptomeningeal lymphomas are extremely rare in immunocompetent children and to the best of our knowledge only hand full of cases have been described in the world literature. In our patient, the clear morphology of lymphoblast observed in CSF cytopsin smears, confirmed by CSF immunophenotyping as B-precursor lymphoblasts. FISH on CSF sample also confirmed abnormal signals for BCR and ABL gene. Pub med search revealed very few cases of Primary leptomeningeal lymphoblastic lymphoma (Table 1) <sup>(1,2,3,4,5)</sup> in paediatric age. Similar case was reported by Troy et al<sup>(1)</sup>. He reported an unusual diagnostic presentation of hypothalamic obesity syndrome in a toddler found to have CNS+ precursor B-cell lymphoblastic lymphoma (B-cell LL). Child responded to intensive chemotherapy and resolution of his hypothalamic obesity. He described that Hypothalamic obesity syndrome occurs as a consequence of damage to the ventromedial hypothalamus (VMH) which serves to process information about diet, nutrients, and adiposity from peripheral hormones insulin, leptin, and ghrelin. VMH dysregulation of feeding and satiety results in hyperphagia with caloric

intake significantly greater than caloric expenditure and subsequent intractable weight gain. The VMH promotes feeding through efferent neuropeptide Y and agouti-related peptide signalling and satiety via a-melanocyte stimulating hormone and cocaine-amphetamine regulated transcript. Felice et al<sup>(3)</sup> in 2000 described three paediatric case of PLML lymphoblastic lymphoma. All 3 patients remain in complete remission with long follow-up. Considering that B-cell precursor cells are good responders to ALL therapeutic strategies, and our case harbouring hyper diploid clone (good prognostic factor), She could have had good response to chemotherapy if was opted.

We conclude that this case highlights the need for CSF evaluation in patients presenting with obesity to evaluate for underlying PLML. Cytological examination combined with Immunophenotyping of CSF sample permits rapid diagnosis with high level of accuracy resulting in immediate efficient treatment planning.

## Funding

This research did not receive any specific grant from funding agencies in the public, commercial, or not-for-profit sectors.

## References

1. Troy C. Quigg et al. Hypothalamic Obesity Syndrome: Rare Presentation of CNS+ BCell Lymphoblastic Lymphoma *Pediatr Blood Cancer*. 2012 November; 59(5): 930–933
2. Oussama Abla etal Leptomeningeal Precursor B-Cell Lymphoblastic Lymphoma in a Child With Minimal Bone

Marrow Involvement J Pediatr Hematol  
Oncol 2004;26:469–472

3. Felice, et al BRIEF REPORT Diagnosis and Successful Treatment of Childhood Primary Leptomeningeal Lymphoma Medical and Pediatric Oncology 2000 34:361–363
4. Oussama Abla, et al Primary CNS Lymphoma in Children and Adolescents: A Descriptive Analysis from the International Primary CNS Lymphoma Collaborative Group (IPCG) Clin Cancer Res. 2011 January 15; 17(2): 346–352
5. Jennie W. Taylor Primary leptomeningeal lymphoma International Primary CNS Lymphoma Collaborative Group report Neurology 2013; 81:1690–1696
6. OUSSAMA ABLA et al Primary central nervous system lymphoma in children Neurosurg Focus 21 (5):E8, 2006.