



Reconstructive Challenges in Albino Patients – Our Experience

Authors

Dr K. Raja^{1*}, Dr M. Choundappan²

¹Senior Assistant Prof, Dept. of Plastic Surgery, Madurai Medical College

²Senior Resident, Dept. of Plastic Surgery, Madurai Medical College

Abstract

This article presents a case series of albino patients who underwent reconstruction in our department mainly for malignancies. We describe the postoperative course of the patients with an emphasis on the HPE examination of the skin which showed the changes of photo damage. Albinism is a inherited group of disorders characterized by abnormal melanin synthesis. We look at the role of melanin, melanocytes in wound healing and their role in the final outcome of these patients. A simple single staged procedure is ideal for these patients as their postoperative course is unpredictable even though it may not satisfy all the requirements of these patients.

Keywords: Albinism, Solar elastosis, melanocytes, melanin.

Introduction

Albinism is a group of disorders of inherited abnormalities of melanin synthesis with an incidence of 1:40000. It is due to defective production of melanin to tyrosine. The differing gene mutations cause a heterogenous manifestation. Melanin is important in preventing photodamage to the skin, thereby affecting wound healing. In this article we report our centre's experience with albino patients who have undergone reconstructive surgery. We look at the selection of flap, postoperative course and eventual long term results of these patients. In our article, we have included two patients who needed reconstruction following excision of malignancies.¹

Case Summaries

13 year old male child presented with complaints of ulcer over his right medial canthal region which

was proven to be Basal cell carcinoma of medial canthus. He had oculocutaneous albinism. His vision was below normal. The size of the lesion was 0.8 x 0.8 located over the medial canthus. The post-excisional defect included Upper eyelid medial third, lower eyelid medial half, medial canthus. A paramedian forehead flap was used to cover the defect with a plan to divide it into 2 eyelids at a second stage.²

Appropriate measurements were taken and flap marked and raised. Intraoperatively, the skin was very delicate and irrespective of the suture material used it cut through. The postoperative course was complicated by wound dehiscence. By the 5th day the suture line dehiscd, and the wound gaped. By 12th day, we performed a wound debridement and applied stay sutures. On day 30 we reattached the flap and grafted the residual area. Even then the wound was not

progressing satisfactorily.

Our second case is of a patient suffering from oculocutaneous albinism of 11 years age with squamous cell carcinoma of the left upper eyelid for which WLE with oblique forehead flap cover and buccal mucosal graft was done. It healed uneventfully. The patient was again operated for

SCC of lower eyelid for which WLE with standard forehead flap cover was done. Here again the patient developed complications similar to the first case. The postoperative course was characterized by wound dehiscence, graft loss, and delayed wound healing.

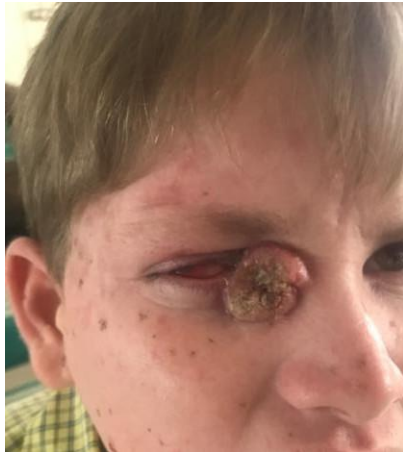

Figure 1: Case 1 Preoperative

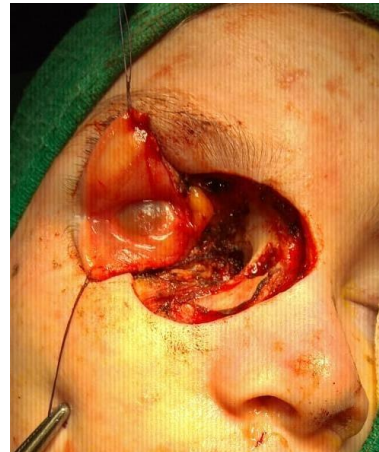

Figure 3 Case 1 Intraoperative

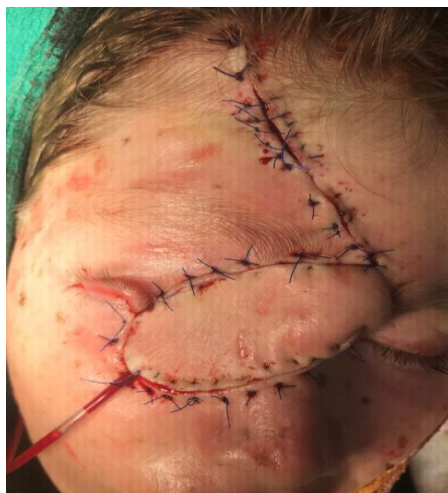

Figure 2 Case 1 Immediate post op

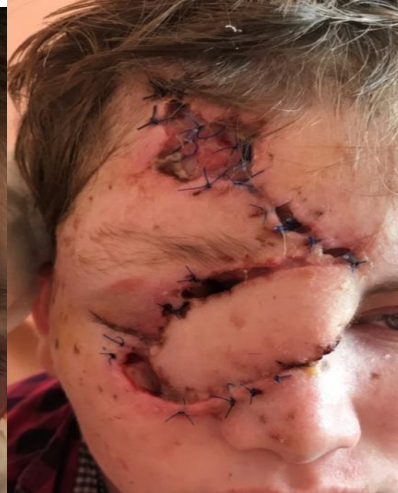

Figure 5 Case 1 POD

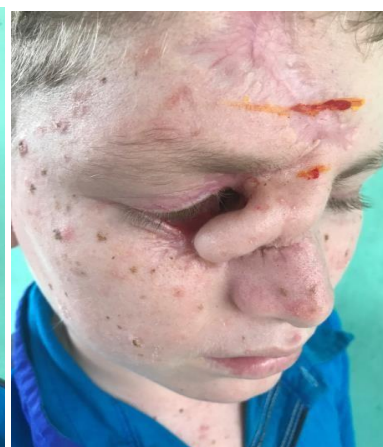
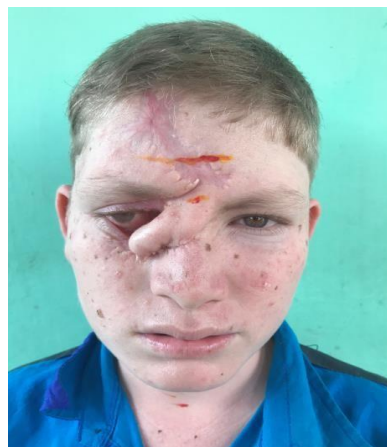
Figure 6 Case 1: 6 month post op

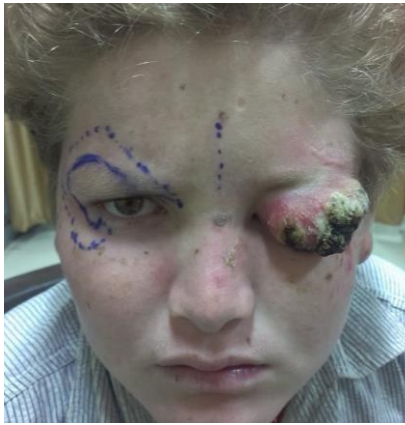

Figure 7 Case 2: Pre OP

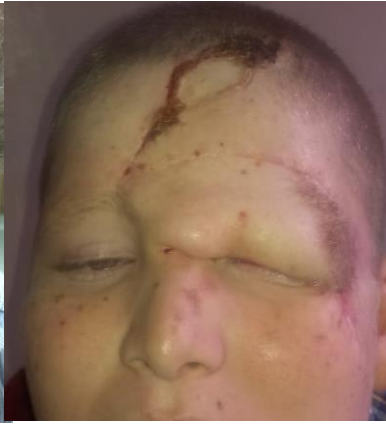

Figure 8 Case 2: Upper eyelid Post OP

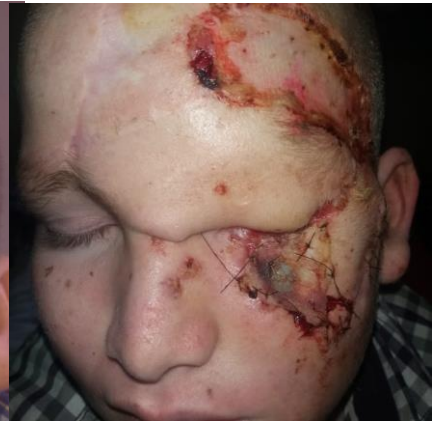

Figure 9 Case 2: Lower eyelid early Post OP

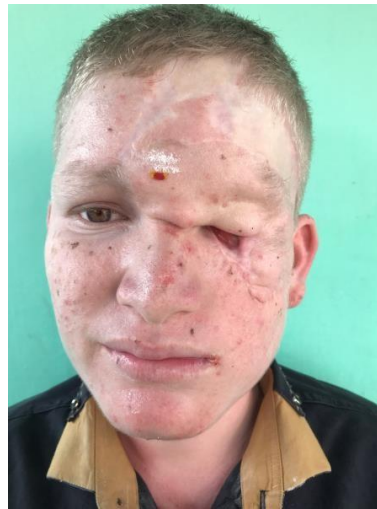

Figure 10 Case 2: 1 year post op

The biopsy of the patients were re examined, with additional bits take from the specimen uninvolved with the tumor and studied. The HPE examination

showed changes of solar elastosis, which represents photodamaged skin.

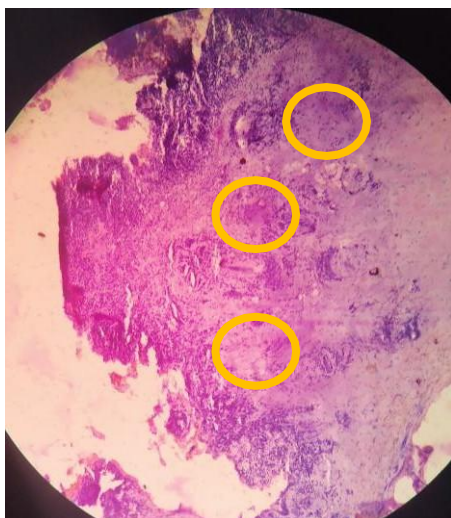


Figure 11 Case 1 HPE, yellow circles show areas of solar elastosis

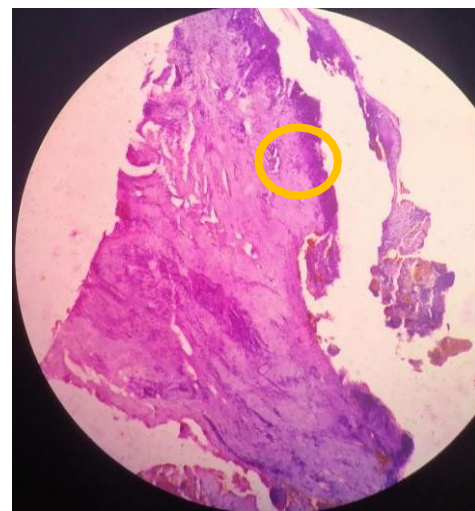


Figure 12 Case 1 HPE, yellow circles show areas of solar elastosis

Results

The final postoperative outcome was not predictable as it was characterized by a complicated course. However, the wounds eventually healed with very little scar formation which blends into the skin tone. The HPE of the skin of the patients showed changes of solar keratosis, thereby showing the extent of photo damage of the skin.

Discussion

The role of melanocytes in normal wound healing is an interesting subject of research. The following

flow chart gives a proposed role of the melanocytes in wound healing. The damaged epithelium induces the proliferation of melanocytes. These melanocytes migrate to the wound and induce fibroblast proliferation, increase collagen secretion, immune modulation, paracrine effects, antimicrobial and anti-inflammatory effects, free radical scavengers, reduce oxidative damage. In fact, conditions like keloid are more common in hyperpigmented peoples like Africans and the least scar formation is seen in Blond individuals.³

Normal healing

Damagedepidermaltissueinducesthe proliferation of melanocytes

Effects

Promote fibroblast proliferation	Increase collagen secretion	immune-modulatory	endocrine	antimicrobial effectors.	anti-inflammatory cell	free radical scavengers	reduce oxidative damage
----------------------------------	-----------------------------	-------------------	-----------	--------------------------	------------------------	-------------------------	-------------------------

In albinism though the melanocytes are normal in number, the melanin pigment is missing and hence the function of melanocytes is reduced. This may lead to poor healing. Also, they allow early photodamage of elastin in the skin leading to changes of solar elastosis at an early age when compared to normal individuals. Elastin is involved in recoil, resistance, matrix synthesis, protease production in wound healing. The degenerating elastin fibers are seen as amphiphilic material in dermis. These are clumped masses of degenerating elastin fibers. The is a normal occurrence. But in albinism it occurs in an earlier age and in a more profound manner.⁴

Conclusion

Having a realistic expectation of wound healing

from both the surgeon and patient side will help in planning the reconstruction and the postoperative complications. Despite the torrential course, wound heals finally with an imperceptible scar, so a simple single stage procedure is the best option even if it may not satisfy all the requirements of the reconstruction. More research is needed into the evaluation of role of melanocytes in wound healing.⁵

References

1. Indian J Plast Surg. 2012 May-Aug; 45(2): 403–411.
2. Gao FL, Jin R, Zhang L, Zhang YG. The contribution of melanocytes to pathological scar formation during wound healing. Int J Clin Exp Med. 2013; 6(7):609–613. Published 2013 Aug 1.

3. Almine JF, Wise SG, Weiss AS. Elastin signaling in wound repair. *Birth Defects Res C Embryo Today*. 2012 Sep; 96(3): 248-57. doi: 10.1002/bdrc.21016.
4. Review. Halim AS, Emami A, Salahshourifar I, Kannan TP. Keloid scarring: understanding the genetic basis, advances, and prospects. *Arch Plast Surg*. 2012; 39(3): 184–189. doi: 10.5999/aps.2012.39.3.184
5. LoDD, Zimmermann AS, Nauta A, Longaker MT, Lorenz HP. Scarless fetal skinwound healing update. *Birth Defects Res C Embryo Today*. 2012 Sep; 96(3): 237-47. doi: 10.1002/bdrc.21018. Review. PubMed PMID: 23109319