



## Dermoid Cyst of Floor of Mouth Mimicking Plunging Ranula

Authors

Raman Wadhera<sup>1</sup>, Sahana. P<sup>2\*</sup>, Sundarakrishnan Dharanipathy<sup>3</sup>, Aarushi Vashist<sup>4</sup>,  
Keshav Gupta<sup>5</sup>

<sup>1,2,4,5</sup> Department of Otorhinolaryngology, Pandit Bhagawat Dayal Sharma Post Graduate Institute of  
Medical Sciences, Rohtak, Haryana, India

<sup>3</sup> Junior Resident (Neurosurgery), AIIMS, New Delhi, India

\*Corresponding Author

Sahana. P

### Abstract

*Dermoid cyst is a developmental anomaly, which is rarely seen in paediatric population. Its occurrence in the floor of mouth is relatively uncommon accounting to about 0.01 % of all oral lesions and oral cavity dermoid cyst constitute 1.6 % of all body dermoids. They usually present as asymptomatic swelling, showing slow and progressive growth, sometimes involving more than one anatomical areas. It occurs as a result of entrapment of ectodermal layer when the first and second branchial arches fuse in the midline. Plunging dermoid cyst and lateral dermoid cyst are relatively rare entity thus posing diagnostic challenge. Whereas, ranula is a pseudocyst, that occurs due to extravasation of salivary secretion into the connective tissues after trauma or infection of the sublingual gland. Treatment approach is different for ranula and dermoid cyst. Ranula can be treated by marsupialization and it has a low level of recurrence, whereas dermoid cyst is treated by surgical excision. Here we present a case of lateral dermoid cyst floor of mouth in a child who had aspiration and marsupialization done before assuming it to be ranula and hence failure of treatment.*

**Keywords:** Dermoid cyst, plunging ranula, developmental anomaly, floor of mouth.

### Introduction

Dermoid cyst is a developmental anomaly, which is rarely seen in paediatric population. Its occurrence in the floor of mouth is relatively uncommon accounting to about 0.01 % of all oral lesions and oral cavity dermoid cyst constitute 1.6 % of all body dermoids.<sup>1,2</sup> They usually present as asymptomatic swelling, showing slow and progressive growth, sometimes involving more than one anatomical areas. It occurs as a result of entrapment of ectodermal layer when the first and second branchial arches fuse in the midline. It is composed

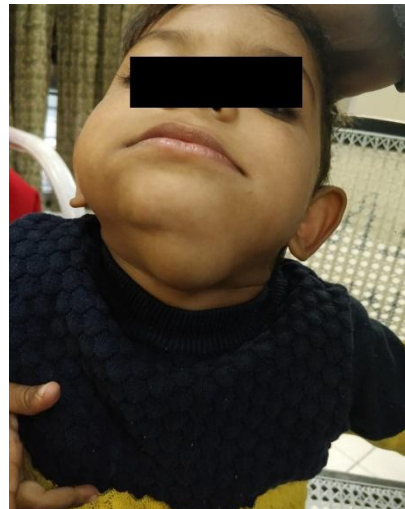of tissues with different origins: ectoblastic, mesoblastic, or endoblastic. A true dermoid cyst cavity is covered with epithelium showing keratinisation and presenting identifiable dermal appendices like hair. Plunging dermoid cyst and lateral dermoid cyst are relatively rare entity thus posing diagnostic challenge. Whereas, ranula is a pseudocyst, that occurs due to extravasation of salivary secretion into the connective tissues after trauma or infection of the sublingual gland. Treatment approach is different for ranula and dermoid cyst. Ranula can be treated by marsupialization and it has a low level of recurrence,

whereas dermoid cyst is treated by surgical excision.<sup>3</sup> There is high chance of iatrogenic infection if dermoid cyst is treated by just marsupialization or drainage.<sup>4,5</sup> Here we present a case of lateral dermoid cyst floor of mouth in a child who had aspiration and marsupialization done before assuming it to be ranula.

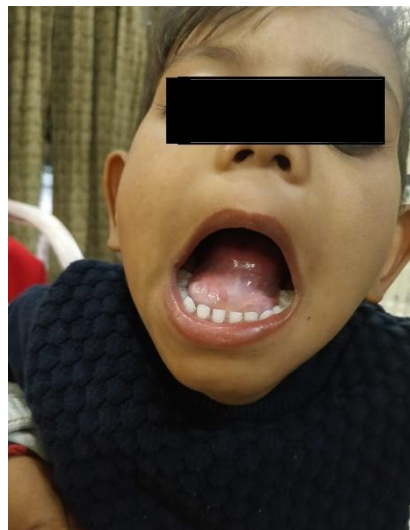### Case Report

A 3 year old male child presented to the ENT Department OPD with complaints of a large, slowly growing, painless swelling in the floor of mouth for about 3 months. There was no history of fever, chills or trauma. There was no history suggestive of dysphagia, difficulty in speech or airway compromise. On examination a large, cystic, non tender, fluctuant, compressible but non-reducible, bimanually palpable swelling of size approximately 3\*2 cm was present in floor of oral cavity extending in left submental space (Fig 1 and 2). The mucosa over the sublingual swelling and skin over the submental swelling was normal. There was history of aspiration and marsupialization done 2 months and 1 month back respectively, assuming it to be ranula, after which the swelling reduced in size but then gradually again increased in size. There was no cervical lymphadenopathy on palpation of neck. USG neck showed a well defined encapsulated bilobed cystic lesion with internal echoes measuring 45\*17\*37mm (15.48 cc) in floor of mouth extending into the submental region. CT imaging showed a hypodense, homogenous lesion with fluid density in the left sublingual space extending submentally (Fig 3 and 4). A provisional diagnosis of plunging ranula was made based on the CT image. Cytological examination of fluid aspirated from the cyst showed anucleated and nucleated squamous epithelium with keratin debris which was suggestive of dermoid cyst. Total surgical excision of the cyst was done by extraoral approach (Fig 5,6,7). On incising the cyst, cheesy material was found filling the cyst. The specimen was then sent for histopathological examination. The patient was kept on injectables for 3 days and then discharged. Histological report established the diagnosis of

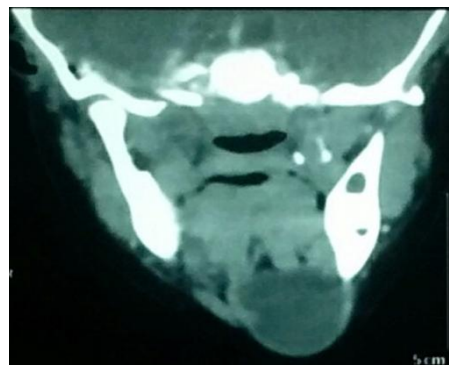
dermoid cyst. The wall of the cyst was found lined by sebaceous glands and hair follicles and keratinous debris was present filling the lumen of the cyst. The patient was kept on follow up for 3 years and there was no signs of recurrence.



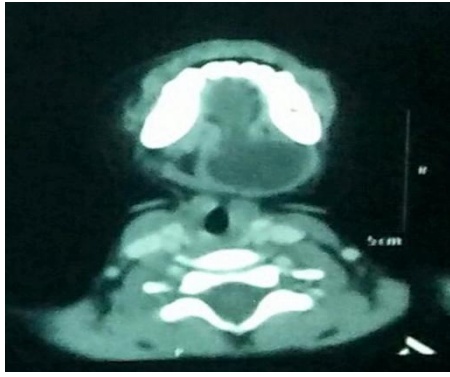**Fig1** showing swelling in left submental space



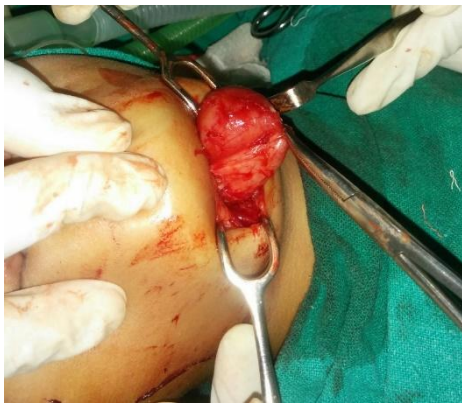
**Fig 2** showing swelling extending into floor of mouth



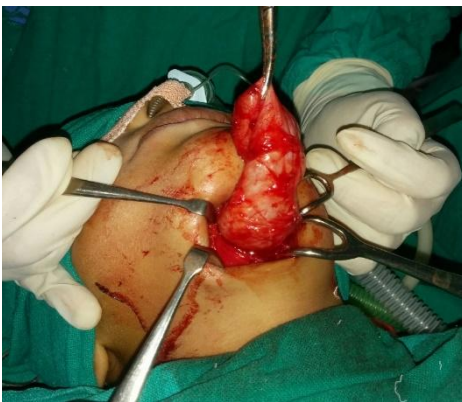**Fig 3** showing CT coronal section with hypodense lesion in left sublingual space extending submentally



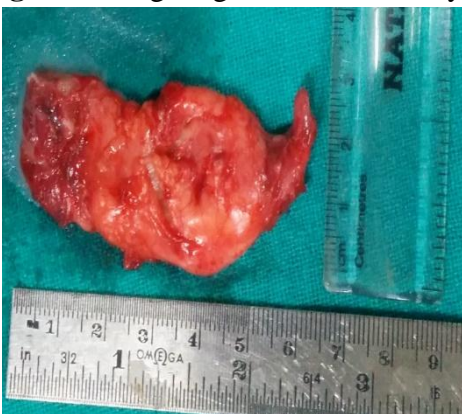**Fig 4** showing CT axial section showing hypodense lesion in left sublingual space



**Fig 5** showing total surgical excision of cyst by extraoral approach



**Fig 6** showing surgical excision of cyst



**Fig 7** showing excised specimen sent for histopathological examination

**Discussion**

Incidence of dermoid cysts is highest in patients between 15 and 35 years of age with equal incidence in males and females. In the head and neck region, they occur most frequently in the periorbital area, while 6.5% of dermoid cysts in this region present in the oral cavity<sup>6</sup> According to literature, majority of the floor of the mouth dermoid cysts are located in the midline (sublingual 52%, submental 26%), while 16% involve more than 1 of the 3 possible spaces in the floor of the mouth region (submental, sublingual, submandibular), and only 6% are positioned exclusively in the submandibular space which appear to be lateral neck cysts. Dermoid cysts are a developmental cyst lined by epidermis-like epithelium and contain dermal adnexal structures such as sebaceous glands, hair follicles, or sweat glands in the cyst wall. Etiologically, dermoid cysts may be congenital or acquired. Congenital type is found to be derived from entrapment of epithelial cells during midline fusion in embryonic development. Acquired forms occur due to implantation of epithelial cells into surrounding tissues that results either from trauma or iatrogenic procedures.<sup>7</sup>

Differential diagnosis for lesions in the floor of the mouth include ranula, dermoid cyst, cystic hygroma, hemangioma, neurofibroma, lipoma and other benign and malignant salivary gland neoplasms.<sup>1</sup> They may present with significant symptoms such as dyspnea, dysphagia, and dysphonia. Sometimes, differentiating between these floor of mouth lesions can be clinically challenging as several pathologies found in this region have similar features.<sup>4,5,8-10</sup> Rare lesions such as dermoid cyst and ranula are not considered as first diagnostic choices, especially in children where they are more difficult to be found. Clinically, the dermoid cysts usually present as a painless slow-growing mass at the sublingual, submental and submandibular region.

In our clinical case, two treatments had failed previously. Previous medical history showed that he was diagnosed previously with a ranula by clinical examination and ultrasound and treated by drainage



once and marsupialization once. After which the patient presented with recurrence now. After proper clinical examination, radiological imaging and cytological examination, surgical excision of the cyst was done and histopathological examination confirmed it to be dermoid cyst.

Initially the cyst was misdiagnosed to be ranula and hence was treated by aspiration and marsupialization which failed. Thus proper imaging and cytological examination is required in choosing the correct treatment option. Another reason for misdiagnosis was the location of the cyst. Usually, dermoid cyst is found in the midline of the body whereas ranula is unilateral.<sup>11</sup> In this case report, the dermoid cyst was present at the left side in the floor of the mouth, and this could have lead to a false clinical diagnosis of a ranula initially and hence failure of initial treatments.

### Conclusion

Thus before treating any swelling of neck proper clinical investigation and its correlation with the examination findings has to be done. This includes complementary examinations such as incisional biopsies, biochemical and imaging tests. After surgery, specimen collected should be sent for histopathological examination for confirmation of diagnosis. It is of utmost importance when there might be different treatment options for lesions of similar clinical features. This helps in avoiding recurrence of disease and unnecessary emotional and social problems in children due to multiple surgical procedures.

**Conflict of Interest:** None

### References

1. Joshua M. Abrahams, Shawn A. McClure. Dermoid Cysts of the Floor of the Mouth in the Pediatric Patient: Report of Two Cases. *International Journal of Oral & Maxillofacial Pathology*; 2014;5(1):42-46.
2. New GB, Erich JB. Dermoid cysts of the head and neck. *Surg Gynecol Obstet* 1937;65:48-55.

3. Puricelli E, Barreiro BOB, Quevedo AS, Ponzoni D. Occurrence of dermoid cyst in the floor of the mouth: the importance of differential diagnosis in pediatric patients. *J Appl Oral Sci* ; 2017;25(3):341-5.
4. Gordon PE, Faquin WC, Lahey E, Kaban, LB. Floor-of-mouth dermoid cysts: report of 3 variants and a suggested change in terminology. *J Oral Maxillofac Surg.* 2013;71:1034-41.
5. Teszler CB, El-Naaj IA, Emodi O, Luntz M, Peled M. Dermoid cysts of the lateral floor of the mouth: a comprehensive anatomosurgical classification of cysts of the oral floor. *J Oral Maxillofac Surg.* 2007;65:327-32.
6. C. Bonet-Coloma, I. M´inguez-Mart´inez, C. Palma-Carri´o, B. Ortega-S´anchez, M. Peñarrocha-Diago, and J. M. M´inguezSanz, "Orofacialdermoid cysts in pediatric patients: a review of 8 cases," *Medicina Oral, Patologia Oral y CirugiaBucal*, vol. 16, no. 2, pp. e200–e203, 2011.
7. Erich JB. Sebaceous, mucous, dermoid and epidermoid cysts. *Am J Surg.* 1940;50:672.
8. Boko E, Amaglo K, Kpemissi E. A bulky dermoid cyst of the floor of the mouth. *Eur Ann Otorhinolaryngol Head Neck Dis.* 2014;131:131-4.
9. Mandel L, Surattanont F. Lateral dermoid cyst. *J Oral Maxillofac Surg.* 2005;63:137-40.
10. Schwanke TW, Oomen KP, April MM, Ward RF, Modi VK. Floor of mouth masses in children: proposal of a new algorithm. *Int J PediatrOtorhinolaryngol.* 2013;77:1489-94.
11. Verma S, Kushwaha JK, Sonkar AA, Kumar R, Gupta R. Giant sublingual epidermoid cyst resembling plunging ranula. *Natl J Maxillofac Surg.* 2012;3:211-3.