www.jmscr.igmpublication.org
Index Copernicus Value: 79.54
ISSN (e)-2347-176x ISSN (p) 2455-0450
crossref DOI: https://dx.doi.org/10.18535/jmscr/v7i5.93

IGM Publication
Journal Of Medical Science And Clinical Research
An Official Publication Of IGM Publication

Segmental Neurofibromatosis: A Diagnostic Dilemma

Authors
Dr Ghanshayam Verma[1], Dr Amit Chauhan[2], Dr Geeta Ram Tegta[3]
[1]Associate Professor, Department of Dermatology, Indira Gandhi Medical College
[2]Ex Resident, Department of Dermatology, Indira Gandhi Medical College
[3]Professor and Head of Department, Department of Dermatology, Indira Gandhi Medical College, Shimla, Himachal Pradesh, India

Introduction

Neurofibromatoses are a set of inherited disorders designated as neurofibromatosis type 1 (NF1), neurofibromatosis type 2 (NF2), and schwannomatosis which result in the development of benign nerve sheath tumors. These three clinical entities differ by specific clinical features and are result from mutations in distinct genes.[1,2]

Segmental neurofibromatosis (SN) also known as a type V neurofibromatosis or mosaic-localized neurofibromatosis is a rare variant of the disease characterized by cutaneous lesions limited to a circumscribed body segment.

Despite the fact that NF is one of the most common inherited diseases (incidence 1/3000 births), SN is very rare with its prevalence is estimated between 0.0014 and 0.002%.[3] It was first described by Crowe *et al*[4] in 1956 who termed it *Sectorial neurofibromatosis*. In 1977, Miller and Sparkes[5] renamed this term as segmental neurofibromatosis (SNF). Riccardi[6] included SNF in his classification of neurofibromatosis as type V.

The clinical features of SNF established by him include café-au-lait spots and/or neurofibromas in a single unilateral segment of the body, with no crossing of the median line, no family history, and no systemic involvement.

We hereby describe a patient who showed segmental expression and posed a diagnostic dilemma until biopsy report was obtained.

Case Report

A 55-year-old female presented with history of multiple small, mildly itchy, nodules over chin for last five years. The patient did not seek any investigations or treatment as the lesions were small and painless. Since then, she noted gradual increase in number of these lesions in the same area. She had no family history of neurofibromatosis.

Physical examination disclosed multiple, soft, dome-shaped, flesh-colored, papules over chin. There was no axillary freckling, café-au-lait spots, lisch nodules by slit lamp examination, or any other neurofibromas. [Figure 1,2] Routine hematological and biochemical investigations done prior to excision of tumors were within normal limits.

Trichoepithelioma, xanthoma, sebaceous hyperplasia and segmental neurofibromatosis were kept as differentials. Histopathological

examination of tumors showed dermal proliferation of spindle cells with wavy nuclei and inconspicuous nucleoli. The interspersed stromacomposed of fibrillary collagen suggestive of neurofibroma. The overlying epidermis showed no significant changes.[Figure 3,4,5]

Figure 1,2: Multiple, dome-shaped, flesh-colored, papules over chin

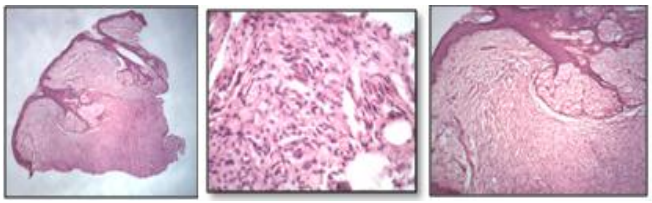

Figure 2,3,4:(4X,10X,40X) Photomicrograph showing Dermal proliferation of spindle cells with wavy nuclei and inconspicuous nucleoli. The interspersed stroma composed of fibrillary collagen. The overlying epidermis shows no significant changes.

Discussion

The patient showed relatively localized manifestations of neurofibromatosis limited to cervical dermatomal distribution. Patient fit into one of the eight subtypes (NF-I to NF-VIII) suggested by Riccardi,[6] that is NF-V or segmental NF, defined as café-au-lait macules or neurofibromas in a single, unilateral segment of the body, with no crossing of midline, no family history, and no systemic involvement. Ingordo *et al*[7]concluded that SNFs are probably not underdiagnosed but are ten times more infrequent than other forms of NF.

Neurofibromatosis is extremely variable in its presentation. The most common manifestation of SN is neurofibromas, and less frequently, café-au-lait spots and axillary freckling. Clinically, patients may be divided into four groups: with only pigmentary lesions, with only neurofibromas, with both pigmentary lesions and neurofibromas, and with isolated plexiform neurofibromas. In most cases, lesions follow the lines of blaschko. Lesions are usually unilateral and occupy single dermatome. Although generalized expression of the disease develops in most cases (90%), some cases present with localized neurofibromas or café-au-lait spots.[2,6] This was first described by Crowe *et al*.[4] as sectorial NF. They proposed that somatic mutation gives rise to neurofibromatosis limited to a distinct sector of the body, with no genetic transmission of the trait.

Recognizing the heterogeneity of the disease, Riccardi[6] suggested a useful system for classifying NF into eight subtypes (NF-I to NF-VIII). One of these types (NF-V) is segmental NF. Riccardi believed that a postzygotic somatic mutation, in primitive neural crest cells, is the most likely cause for development and thus the lesion should be strictly non-inherited.

The management of cutaneous manifestations of SN can provide immeasurable benefit to the patient. Current treatments are limited, and there is presently no consensus on standard therapy.[8] Cutaneous neurofibromas and café-au-lait macules that are bothersome to the patient can be removed. The most common technique to remove neurofibromas is simple surgical excision.[9]This may be time-consuming and can result in pain and scarring. Laser ablation and electrocautery have been used on numerous smaller cutaneous neurofibromas; however, recurrences are possible.[9]

Recent research has shown that CO2 laser treatment for neurofibromas can be effective and provide a high level of patient satisfaction and minimal pain. The drawback to the use of lasers include local infection rate and hypertrophic scarring.[10] Similarly, treatment of neurofibromas with electrocautery is also effective. Electrocautery allows for quick treatment of numerous lesions with instant hemostasis and minimal thermal damage to surrounding tissue.[11]

Segmental neurofibromatosis warrants age appropriate malignancy screening as it may be a representation of paraneoplastic syndrome. Apart from this patients do require a regular follow up as the disease may progress to a generalised form. Genetic counselling can also be taken up as the disease transmission is through gonadal cell lines.

The recent increase in the reported cases of SNF shows the rising interest in this variant of the syndrome and indicates a justifiable doubt about the rarity vsunder diagnosis of SNF. Many times, the clinical picture of SNF can be neglected by the patient and passed unnoticed by the clinicians because of absence of symptoms, thus requiring a clear understanding on the part of dermatologists.

Conclusion

SN is a rare and atypical variant of neurofibromatosis. Our case represents a typical clinical presentation of SN without generalization. The patient denied any familial history of neurofibromatosis or systemic complaints. The patient had two healthy off springs with no signs of neurofibromatosis. Close monitoring is vital for all patients with SN. Counseling and cosmetic treatments should always be offered to patients.

References

1. Theos A. American College of Physicians; American Physiological Society. Pathophysiology of neurofibromatosis type 1. Ann Intern Med. 2006;144:842–9.
2. Roth RR, Martines R, James WD. Segmental neurofibromatosis. Arch Dermatol. 1987;123:917–20.
3. Victor FC. Segmental neurofibromatosis. Dermatol Online J. 2005;11(4):20.
4. Crowe FW, Schull WJ, Neel JV. A clinical, pathological and genetic study of multiple neurofibromatosis. Springfield, III: Charles C Thomas Publishers; 1956. pp. 74pp. 80–2.–139.pp. 153–9.
5. Miller RM, Sparkes RS. Segmental neurofibromatosis. Arch Dermatol. 1977; 113:837–8.
6. Riccardi VM. Neurofibromatosis: Clinical heterogeneity. CurrProbl Cancer. 1982; 7:1–34.
7. Ingordo V, D'Andria G, Mendicini S, et al. Segmental neurofibromatosis: is it uncommon or underdiagnosed? Arch Dermatol. 1995;131:959–60.
8. Kim HJ, Lee KG, Yi SM, et al. Successful treatment of multiple cutaneous neurofibromas using a combination of shave excision and laser photocoagulation with a 1,444 nm neodymium-doped yttrium aluminum garnet laser. Dermatol Surg. 2012 Jun;38(6):960-3.
9. Sabantini C, Milani D, Menni F, et al. Treatment of neurofibromatosis type 1. Curr Treat Options Neurol. 2015 Jun;17 (6):26.
10. Meni C, Sbidian E, Moreno J, et al. Treatment of neurofibromas with carbon dioxide laser: A retrospective cross-sectional study of 106 patients. Dermatology 230:263-8.
11. Levine SM, Levine E, Taub PJ, et al. Electrosurgical excision technique for the treatment of multiple cutaneous lesions in neurofibromatosis type I. J Plast Reconstr Aesthet Surg. 2008 Aug;61(8):958-62.