

**Original Article****Mirizzi's Syndrome management: open and laparoscopic technique**

Authors

Rajendra Singh¹, Ranvijay Bharti^{2*}, Rajshekhar³¹M. S (Surgery), Associate Professor, Department of Surgery, Vardhman Institute of Medical Science, Pawapuri, Nalanda BiharEmail: Rajendra.singh389@gmail.com²M. S (Surgery), 2nd yr. PG student, Department of Surgery, Nalanda Medical College, Patna, Bihar, India³M. S (Surgery), Senior Resident, Department of Surgery, Nalanda Medical College, Patna, Bihar, India

*Corresponding Author

Dr Ranvijay BhartiM.S (Surgery), 2nd year pg. Student, Department of Surgery, Flat no 5, block 1, New PG. doctors hostel, IDH Colony, Agamkuan, Nalanda Medical College, Patna, Bihar, India.Email: drranvijay@gmail.com**Abstract**

Mirizzi syndrome is a complication of longstanding cholelithiasis. In this there is obstruction of the extra hepatic bile duct by stone/s in the Hartman's pouch or cystic duct (Mirrizi type I) which may erode into the bile duct forming cholecystobiliary fistula (Mirrizi type II). Altered biliary tract anatomy and the associated pathology make cholecystectomy, open or laparoscopic, awareness of this entity and its preoperative diagnosis is of paramount importance to avoid injury to the bile duct during surgery. Improper surgical procedures may lead to long-term stricture formation. The present article reviews the available literature on various aspect of this syndrome including its pathogenesis, diagnosis and recommended management and guidelines.

Keywords: *Mirizzi syndrome, Obstructive jaundice, cholecystobiliary fistula.*

Introduction

Mirizzi syndrome (MS) is defined as bile duct obstruction due to stone/s impacted in the Hartman's pouch or cystic duct. This entity was originally described by Kehr and Ruge and subsequently by PL Mirizzi. At one time considered to be rare to merit reporting of isolated cases only larger series on MS are now available in literature. The reported incidence has ranged from 0.05 to 4% of all patients undergoing surgery for cholelithiasis. These figures assume significance in view of the high prevalence of

cholelithiasis and the high frequency of cholecystectomies performed world over. Considered as trap in the surgery of cholelithiasis, presence of MS poses considerable challenge to the ingenuity of any surgeon operating on the biliary tract. At surgery the frozen Calot's triangle with or without bile duct erosion, presence of bilioenteric fistula in a sizable proportion of patients and its misinterpretation or coexistence of carcinoma gall bladder (GB), calls for extra caution on the part of operating surgeon. Inadequate or inappropriate surgery is fraught

with the danger of injury to the bile duct or long-term stricture formation. In the era of minimal invasive surgery, this entity assumes further significance as the altered biliary tract anatomy may demand early conversion to open cholecystectomy in the majority. The present article is an attempt to review this entity in its various forms, their pathogenesis, diagnosis and management, particularly in light of modern technical advances.

Pathogenesis and Classification

Biliary obstruction as described in the original MS was reported to have resulted from stones in the cystic duct leading to inflammation and spasm of the sphincter in the distal common hepatic duct (CHD); the entity was there for called 'functional hepatic syndrome. However subsequently the obstruction was proved to be purely mechanical, a result of external compression and inflammation by the stone in the Hartman's pouch or cystic duct. The pathogenesis was further clarified and the various components of this syndrome were identified as Cystic duct parallel to CHD Impaction of a gallstone in the cystic duct or neck of the GB Partial mechanical obstruction of the CHD by the stone itself or the resulting inflammation, recurrent cholangitis or ultimately cholangitic cirrhosis due to partial obstruction. Obstruction of common hepatic duct or common bile duct (CBD), both hence forth referred as common duct(CD), due to distended GB as in acute cholecystitis or tumours of the GB or cystic duct has also been described as variants of MS. However, in our opinion, it is preferable to avoid any such confusion in nomenclature and the syndrome should strictly refer to bile duct obstruction resulting from stone disease only.

Cholecystobiliary fistula (CBF), an internal biliary fistula between GB and the CD, Various hypotheses have been proposed to explain its pathogenesis. The fistula was thought to represent a congenital anomaly with absent cystic duct. The more plausible hypothesis, however, has been cystic duct occlusion due to stone and

inflammation leading to distension of GB and approximation of its wall with that of CD facilitated by the continued presence of a stone, pressure necrosis of the common duct walls and fistula formation. McSherry views CBF as an advanced stage of MS, where the impacted stone has subsequently eroded into the CD forming a fistula. On this pretext he classified MS into two types,

Type I- bile duct obstruction by external compression and

Type II-cholecystobiliary fistula

Though CBF was further classified into two types depending on the presence or absence of cystic duct, we concur with Csendes et al that such a classification is not relevant from management point of view. The latter author further sub classified the CBF according to the extent of circumferential erosion of CD and proposed a new classification. The various types according to this classification and their relative incidence are,

Type I-obstruction of CD by stone/s impacted in the Hartman's pouch or the cystic duct- 11%.

Type II - cholecystobiliary fistula with erosion of less than 1/3 of circumference of CD -41%.

Type III-erosion of up to 2/3 circumference of CD-44%.

Type IV-complete destruction of CD wall by the off ending stone-4%.

Each type was thought to represent the more advanced form of the previous one. A standardised management protocol was applied to each type and satisfactory results obtained by these authors in the largest reported series so far on MS. This classification appears quite rational and should be acceptable to any surgeon operating on a patient of MS. However, because of the limitation that the extents of bile duct erosion which forms the basis of this classification is not amenable to detection on preoperative imaging, the original classification as proposed by Mc Sherry is still popular with surgeons and radiologists who may play an important role in the preoperative management of these patients.

Presenting Features

MS is encountered more commonly in females, probably a reflection of gallstone preponderance in this group of patients. The mean age of presentation has ranged from 21 -90 years in different series, underscoring the fact that the syndrome is a complication of long standing cholelithiasis. Pain is the most common presenting feature reported in 56-100% of patients followed by jaundice in 27-100% and cholangitis in 4-35% of patients. Charcot's biliary triad is present in 41-71% of patients. Presence of painless jaundice may often mimic malignant biliary obstruction. Acute cholecystitis has also been reported in as high as one third of patients. Less common presentation includes acute pancreatitis, GB perforation and weight loss. Hepatomegaly is common and a hard GB lump mimicking carcinoma may be palpable in 22% of patients. Rarely the patient may be completely asymptomatic despite complete erosion of the CD. A high incidence of associated GB malignancy has also been reported.

Diagnosis

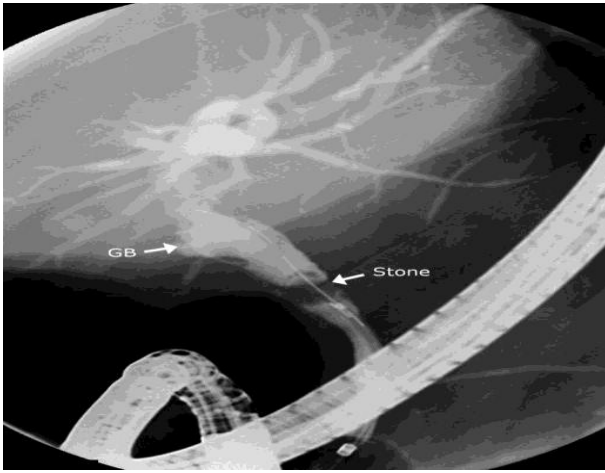
Biochemical parameters of liver function show a cholestatic pattern, simulating those of choledocholithiasis. Serum bilirubin ranges from normal to as high as 30 mg/dl with an average of 7-10 mg/dl. Serum alkaline phosphatase level range from normal to about three to tenfold rise. Imaging studies are, however, the mainstay of preoperative diagnosis.

Ultrasound (US) is a good screening method, the sensitivity of USG in detecting Mirizzi's syndrome is 23-46%. Specific findings of this syndrome are, small contracted GB containing stone/s, an echogenic nodule or calculus in the CD, mild to moderate dilatations of the proximal biliary radicals and a normal size or untraced bile duct distal to the calculus or nodule. Demonstration of a longitudinal septum like structure in the CD, an appearance resulting from the dilated cystic duct running parallel to the bile duct may also point to a diagnosis of MS in

suspected cases. Intraductal ultrasound (IDUS) has been reported to be highly sensitive (97%) and specific (100%) in one study.

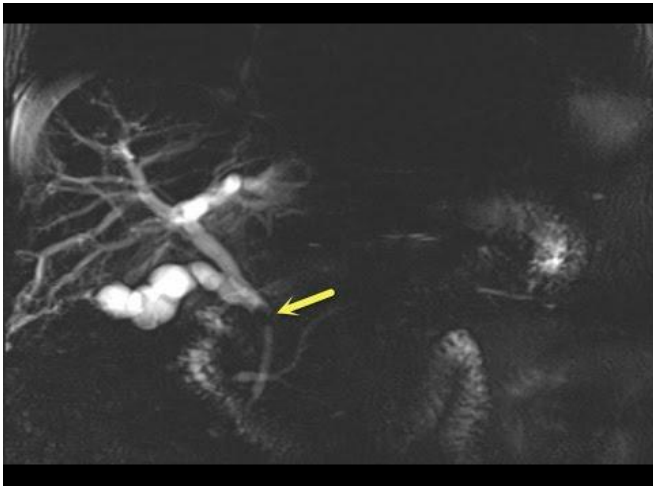Computed tomography (CT) when performed may corroborate the US findings. In addition, an irregular cavity adjacent to the neck of GB containing the protruding stone is quite characteristic of MS. The duodenum and colon may be seen in close proximity of GB representing bilioenteric fistula, a common occurrence in these patients. CT scanning has a similar sensitivity to US, but can be helpful in diagnosing other causes of obstructive jaundice such as GB cancer, cholangiocarcinoma, or metastatic tumour. Despite the characteristic features, the role of US and CT are mainly to rule out malignancy rather than diagnose MS.

Cholangiography by far remains the most reliable method of diagnosis of this syndrome in the preoperative period. The typical findings on cholangiogram are an eccentric or excavating defect on lateral wall of the CD at the level of the cystic duct or GB neck. Similar cholangiography pictures may also be produced by carcinoma of the cystic duct or carcinoma GB. The contour of the filling defect may be irregular in malignancy in contrast to smooth outline of the stone in MS. Endoscopic retrograde cholangiography (ERC) is preferred over percutaneous trans hepatic or intravenous cholangiography since in addition to diagnosis it is possible to extract concomitantly bile duct stone/s which may be present in a significant proportion of these patients. It is also possible to provide preoperative bile drainage in high-risk patients by insertion of endoscopic nasobiliary drainage (ENBD) catheter. The ENBD catheter further helps in identification of CD at surgery.



Endoscopic cholangiopancreatography remains the gold standard for the confirmation of the diagnosis;

however, magnetic resonance cholangiography (MRC) has been proposed recently as a less invasive,



equally effective method of preoperative study. MRC and ERC are equivalent in their ability to diagnose and delineate details of biliary strictures, and to detect a cholecystocholedochal fistula. In addition, T2 weighted images can differentiate a neoplastic mass from an inflammatory one which may not be possible on US or CT scan.

Operative strategy

In the absence of definite preoperative diagnosis, awareness and careful dissection on the part of the operating surgeon may unmask a few unsuspected cases. The finding of dense

Fig.1 Endoscopic retrograde cholangiogram showing a large stone (arrow) in the contracted GB protruding into the bile duct causing a concentric filling defect suggestive of Mirizzi syndrome

pericholecystic adhesions, shrunken and sessile GB with/without cholecystoenteric fistula, obliterated calots triangle should arouse suspicion of this entity. The impacted or the eroding stone may simulate carcinoma of the GB neck, thus further complicating the already complicated situation. An intraoperative cholangiogram performed in the early part of surgery confirms the diagnosis and helps in delineating the biliary anatomy. The fundus of the GB is opened and the stone/s extracted. The cystic duct stone should be milked back in to the GB. In rare instances when the Hartman's pouch or cystic duct lies behind the CBD, retrieval of the offending stone may be difficult. A transcholedochal approach has been recommended in such situation. It is often surprising to find the so called growth at the neck of GB disappear with evacuation of stone/s. A frozen section biopsy may be done if concomitant malignancy is strongly suspected. A gush of bile at this stage point to presence of cholecystobiliary fistula, assessment of the extent of bile duct erosion which dictates the subsequent management is made at this stage.

In the absence of any bile duct erosion i.e. type I MS, partial cholecystectomy alone is adequate. After removal of the offending stone the Hartman's pouch or the parallel cystic duct is left behind. The inflammatory adhesion between these structures and CD precludes any dissection in this area and is bound to result in bile duct injuries if insisted upon. The cystic duct opening in the retained Hartman's pouch is usually in an obliterated state because of repeated inflammation, when present can be closed by a purse string suture around its opening on the mucosal aspect of Hartman's pouch. Presence of CBF calls for a cautious approach. When bile duct erosion is significant late strictures has been reported with simple closure of fistula or end to end repair. In most of the cases the defect in the CD can be managed by retaining a cuff of GB around the fistula which is approximated, the procedure thus known as choledochoplasty. The CD in such cases should be drained by a T-tube

placed through a fresh choledochotomy or the fistula itself. The tube should be kept for at least two to three months, Csendes reported an increased incidence of bile leak when the tube was brought out through the fistula rather than a fresh choledochotomy. Though choledochoplasty alone may suffice in nearly all cases of CBF, there are patients who present with complete or near complete obstruction of the bile duct at the initial exploration itself in these cases for better long-term results it is safer to perform bilioenteric anastomosis. The various forms of which could be hepaticojejunostomy end to side or side to side, cholecystocholedochoduodenostomy. The other indication for bilioenteric anastomosis could be presence of concomitant multiple CBD stones or distal obstruction of bile duct due to other cause. A well-defined management guideline was provided by Csendes et al who classified MS on the basis of extent or erosion of CD circumference. The recommended procedures for different types are: type I- partial cholecystectomy, type II-suture closure of fistula or choledochoplasty. Type III - choledochoplasty, type IV - bilioenteric anastomosis. A satisfactory outcome in a mean follow up of 5.7year is a testimony to the adequacy of these procedures. This management protocol has been followed by other authors too. Bilioenteric anastomosis has been performed in these series for some of type III case too, where bile duct erosion was considered significant. Concomitant choledocholithiasis has been reported in 35-62% of patients with MS. Routine exploration of the CD should be carried out in all cases with CBF. For type I, cases one can be more selective. The CD exploration is performed through the fistula itself or a fresh choledochotomy.

Mirizzi syndrome in the laparoscopic era

This entity was initially considered an absolute contradiction for laparoscopic cholecystectomy. The reason for this could be the sessile GB, frozen calots triangle, the recommended fundus first method, presence of bilioenteric fistula in a sizable amount of patients, and the need to rule

out malignancy. Knowingly or unknowingly when it was attempted conversion to open cholecystectomy was required in face of real or threatening bile duct injury. However, with further evolution and increasing familiarity, successful management of MS by laparoscopic technique are now being increasingly reported in literature. Difficult anatomy in these patients may necessitate insertion of extra ports in addition to the conventional ones. A careful and patient dissection is of paramount importance to delineate the altered anatomy. Lateral traction of the infundibulum of GB unlike routine cases does not open up the calots triangle because of dense fibrosis in this area. Special emphasis must be placed on identification of cystic duct GB and cystic duct-CD junction. Intraoperative cholangiogram or laparoscopic ultrasound are of great assistance in these difficult situations. The basic principle of management of various types of MS is akin to that in open surgery. For type I, GB is opened at the fundus, stone evacuated, anterior wall of the GB is excised with diathermy and the Hartmann's pouch is left adherent to the CD. In the single case reports. the authors did not find bile emptying from the GB remnant, thus presuming the cystic duct to be obliterated and no attempt was made to ligate it, the patients made an uneventful recovery. In presence of CBF, partial cholecystectomy by fundus first method and choledochoplasty around a T-tube has been performed with a successful outcome. While it appears to be feasible, especially for type I anatomy, the routine use of laparoscopic surgery as the primary treatment of MS is controversial. It has been suggested, that a prudent approach for type I MS is to perform a trial laparoscopic dissection, but to have a low threshold to convert to an open procedure. This approach should be undertaken only by experienced laparoscopic surgeons. Moreover, it is now amply clear that partial cholecystectomy and choledochoplasty alone may be inadequate in presence of significant erosion of CD. Bilioenteric anastomosis which is required in these patients is certainly a difficult

proportion by laparoscopic technique. Therefore, till such time that more experience is available, we would concur with other authors that only type I MS may be tried by laparoscopic method by an experienced surgeon, in a centre with adequate facilities and a low threshold for conversion to open method.

Endoscopic management of Mirizzi syndrome

In MS conventional methods of endoscopic extraction fails because of the inability to capture the offending stone. However, with the availability of modern adjuncts it is now possible to treat some of these patients successfully. In a report by Binmoeller et al 14 patients with cystic duct stones were selected for endoscopic treatment after being considered unfit for surgery due to various reasons. Using "mother baby scope system" the offending stone/s were visualised and fragmented with the help of electrohydraulic lithotripsy (EHL) introduced through its operating channel. Stone fragments larger than 0.5 cm in diameter were refragmented and subsequently extracted by dormia basket. The median time required for the entire procedure was 60 minutes. The treatment was successful in all but one patient. In the latter patient asymptomatic leakage of contrast media into peritoneum was observed from the cystic duct. The patient responded to naso vesicular catheter, intravenous fluid and antibiotics.

Under cholangioscopic control EHL of the offending stone by percutaneous trans hepatic approach has also been reported by Cairns et al. Long term success appears to be most likely in patients with type II disease who do not have residual gallbladder stones. England et al have also shown that endoscopic treatment is an effective temporary measure before surgery and can be a definitive treatment for candidates unsuitable for surgery. The above reports prove the feasibility of endoscopic treatment albeit in a selective group of patients. The need for sophisticated set up and an experienced endoscopist/interventionist are the obvious limitations of this approach.

Conclusion

Presence of MS makes cholecystectomy an extremely hazardous procedure. This syndrome, characterized by bile duct obstruction due to stone in Hartman's pouch or cystic duct is classified into two types. Obstruction by external compression is classified as type I and that by an eroding stone forming a cholecystobiliary fistula as type II. Both are considered evolving stages of one pathological process. Further classification has been suggested according to the extent of circumferential erosion of common duct. The clinical and biochemical features of this entity simulate that of choledocholithiasis. Cholangiography remains the mainstay of diagnosis. An eccentric filling defect in common duct at the level of GB with proximally dilated and distally collapsed bile duct suggests MS. Fibrotic contracted GB with dense pericholecystic adhesions, obliterated cystic duct and frozen Calot's triangle should arouse suspicion of this entity at laparotomy. An antegrade or fundus first method must be undertaken in all suspected or proven cases to avoid bile duct injury. After giving an incision at the fundus gallstone/s is/are evacuated and assessment of the type of MS is made. For type I MS, partial cholecystectomy leaving behind the Hartman's pouch adherent to the bile duct is an adequate procedure. In presence of cholecystobiliary fistula, simple repair of fistula is fraught with danger of long-term stricture formation. Partial cholecystectomy, choledochoplasty utilizing the cuff of the GB and T-tube drainage of the common duct suffices in the majority. Bilioenteric anastomosis is indicated when the bile duct circumference erosion has been considerable. Concomitant choledocholithiasis may be present in up to two thirds of these patients making common bile duct exploration mandatory. In Mirizzi type I laparoscopic method can be tried but only at well-equipped centres for advanced laparoscopy and by an experienced surgeon, for a beginner or a primary set up it should be considered a relative contraindication till more experience is available endoscopic extraction of

the offending stone/s has also been tried in a select group of patients in experienced hands with good results.

References

1. Kher H (1905) Die in meiner Klinik geübte Technik der Gal-lenstein operation, Munchen J F Lehmann
2. Ruge E (1908) Deitragte zur chirurgischen Anatomie der grossen Gallenwege (Ductus Hepaticus, choledochous and pancreaticus) Arch Clin Chir LXXVII:47
3. Mirizzi PL (1948) Syndrome del conducto hepatico. J IntChir8:731-777
4. Clement AR, Lowman RM (1965) The Roentgen features of the Mirizzi syndrome. Am J Roentgenol 94:480
5. Corlette MB, Bismuth H (1975) Biliobiliary fistula: A trap in surgery of cholelithiasis, Arch Surgery 110:377-385
6. Dewbury KL (1979) The features of Mirizzi syndrome on ultrasound examination. Br J Radiol 52:990-992
7. Koehler RE, Melson GL, Lee IKT, Long J (1979) Common hepatic duet obstruction by cystic duet stones: Mirizzi syndrome, AmJ Roentgenol 132:1007-1009
8. Ravo B, Epstein H, La Mendolo S, GerR (1986) The Mirizzi syndrome: preoperative diagnosis by sonography and transhepatic cholangiography. Am. J Gastroenterol 81:688-690
9. Csendes A, Diaz IC, Burdiles P, Malueda F, Navo O (1989) Mirizzi syndrome and cholecystobiliary fistula: a unifying classification. BrJ Surgery 76:1139-1143
10. Ibrarullah MD, Saxena R, Sikora SS, Kapoor VK, Saraswat VA, Kaushik SP (1993) Mirizzi syndrome identification and management strategy, Aus NZ J Surgery 63:802-806
11. Curet MJ, Rosendale DE, Congilosi (1994) Mirizzi syndrome in a native American population. Am J Surgery 168:616-621
12. Baron RL, Stanley RJ, Lee JKT (1995) Body computed tomography: a prospective comparison of the evaluation of biliary obstruction using computed tomography and ultrasonography. Radiology 145:91-98
13. Redaelli CA, Buchler MW, Schilling MK, Krahenbuhl L, Ruchti C, Blumgart LH, Baer HU (1997) High coincidence of Mirizzi syndrome and gallbladder carcinoma, Surgery121:58-63
14. Sare M, Gurer S, Taskin V et al (1998) Mirizzi's syndrome: Choice of surgical procedure in the laparoscopic era. Surgery Laparoscopic Endoscopic 8:63
15. Matthews BD, Sing RF, Heniford BT (2000) Magnetic resonance cholangiopancreatographic diagnosis of Mirizzi's syndrome. J Am Coll Surgery 190:630
16. Chowbey PK, Sharma A, Mann V, Khullar R, Baijal M, Vashistha A (2000) The management of Mirizzi syndrome in the laparoscopic era. Surgery Laparoscopic endoscopic Percutaneous Tech 10:11-14
17. Chan CY, Liao KH, Ho CK, Chew SP (2003) Mirizzi syndrome: a diagnostic and operative challenge. Surgeon 1:273-278
18. Prasad TL, Kumar A, Sikora SS, Saxena R, Kapoor VK (2006) Mirizzi syndrome and gallbladder cancer. JHBPSurg 13:323-326:936-938
19. Gomez D, Rahm an SH, Toogood GJ, Prasad KR, Lodge JP, Guillou PJ, Menon KV (2006) Mirizzi's syndrome-results from a large western experience. HPB 8():474-479
20. Wehermann T, Riphaut A, Martchenko K, Kokabpick S, Pauka N, Stergiou N, Frenz MB (2006) Intraductal ultrasonography in the diagnosis of Mirizzi syndrome. Endoscopy 38:717-722
21. Kwon AH, Inui H (2007) Preoperative diagnosis and efficacy of laparoscopic procedures in the treatment of Mirizzi's syndrome. J Am Coll Surgery 204(3):409-415.