



Histopathological Study of Non Neoplastic and Neoplastic Lesions of Larynx

Authors

Ritu Bhagat¹, Mandeep Randhawa², Subhash Bhardwaj³

¹Senior Resident, Deptt. of Pathology, GMC Jammu

²Assistant Professor, Deptt. of Pathology, GMC Amritsar

³Professor, Deptt. of Pathology, GMC Jammu

*Corresponding Author

Dr Mandeep Randhawa

Email: Mandyrandhawa26@gmail.com, +91-9915785049

Abstract

Background: *The larynx serves to protect the lower airways, facilitates respiration and plays a key role in phonation. Lesions of larynx can be classified into commonly occurring non neoplastic and neoplastic lesions.*

Materials and Methods: *This is a prospective study carried out in department of pathology, GMC Jammu over a period of two years. A total of 90 cases were included in the study.*

Results: *The peak incidence of benign laryngeal lesions occurred in 30-40 years and malignant lesions in 60-70 years. Both benign and malignant lesions were more common in males as compared to females with M:F ratio of 2:1. Vocal polyp (16.7%) being the most common tumor like lesion followed by chronic non specific laryngitis (12.2%). Among the benign tumors squamous papilloma constituted 6.7% cases and in malignant tumors squamous cell carcinoma constituted 52.2% cases.*

Conclusion: *Every tissue removed during laryngeal surgery should be sent for histopathology, as early diagnosis of lesion can lead to effective management.*

Keywords: *Larynx, tumors of larynx, histopathological.*

Introduction

The human larynx protects the lower respiratory tract, provides a controlled airway, allows phonation and the generation of a high intra thoracic pressure for coughing.¹ The larynx is divided into the supraglottis, glottis and subglottis based on anatomical location. Tumors of the larynx can be divided into benign or malignant. Laryngeal tuberculosis, vocal cord nodules, and vocal cord polyps are tumor like (non neoplastic) lesions of the larynx. Benign laryngeal tumors include a large number of lesions such as

papillomas, hemangiomas, fibromas, chondromas, myxomas and neurofibromas. About 95% of laryngeal carcinomas are typical squamous cell tumors rarely adenocarcinomas are seen to arise from larynx, presumably arising from submucous glands.² The exact cause of laryngeal cancer is still unknown. However, several interrelated cofactors (mainly tobacco smoking and alcohol consumption), are clearly associated with an increased incidence in laryngeal cancer.³

Materials and Methods

The present study, which is a prospective, based on study of laryngeal biopsies received in department of pathology, GMC Jammu for a period of two years. A total of 90 cases were included in the study.

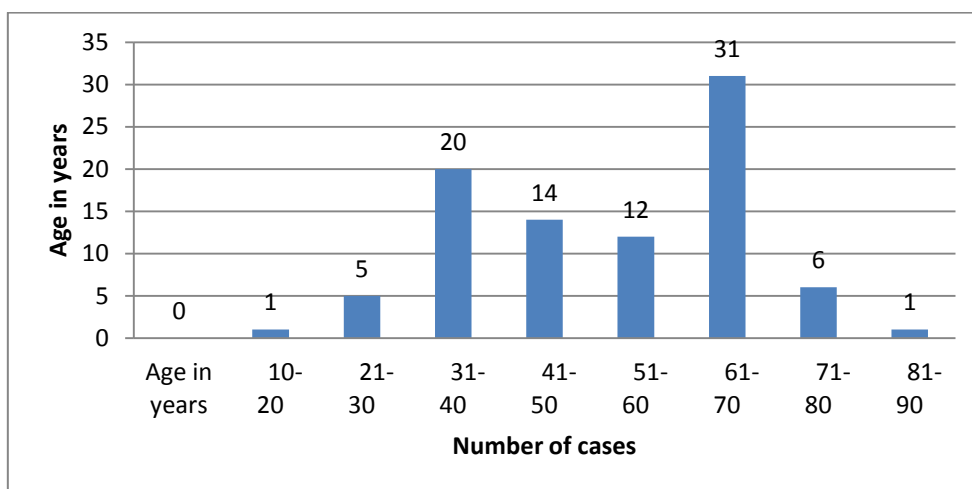
Results

In this study patient’s age ranged from 17 years to 81 years .The peak incidence of benign laryngeal lesions was in 30-40 years and malignant lesions in 60-70 years .Both benign and malignant lesions

were more common in males as compared to females with M:F ratio of 2:1.

Age wise distribution of cases shown in table 1

Age in years	Number of cases
10-20	01
21-30	05
31-40	20
41-50	14
51-60	12
61-70	31
71-80	06
81-90	01



Distribution of various lesions according to histological diagnosis is shown in table 2:

S. No	Tumor like lesions	No.	%age	Benign tumors	No.	%age	Malignant tumors	No.	%age
1.	Vocal polyp	15	16.7%	Squamous papilloma	06	6.7%	Squamous cell carcinoma	47	52.2%
2.	Vocal nodule	08	8.9%	Hemangioma	01	1.1%	adenocarcinomas	01	1.1%
3.	Tubercular laryngitis	01	1.1%						
4.	Chronic non specific laryngitis	11	12.25%						
	Total	35	38.9%		07	7.8%		48	53.3%

Distribution of benign and malignant lesions is shown in table 3:

S. No.	Lesion	Number of cases	Percentage
1.	Benign tumors	07	7.8%
2.	Malignant tumors	48	53.3%

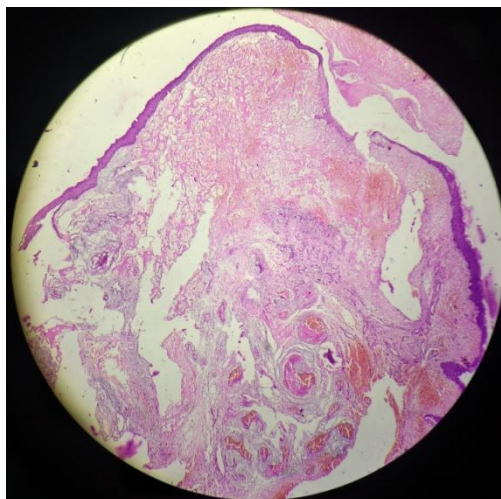


Figure 1: Vocal Nodule

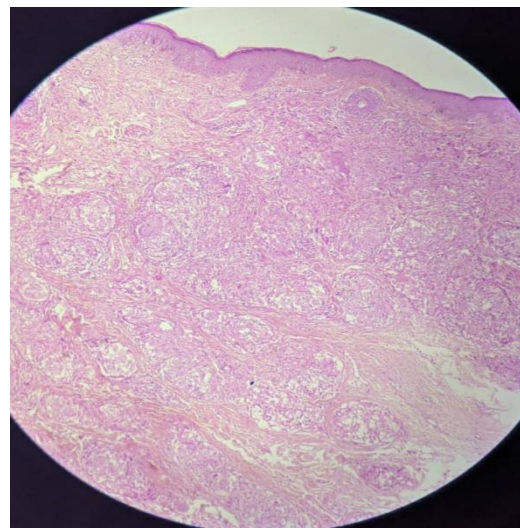


Figure 4: Laryngeal Tuberculosis

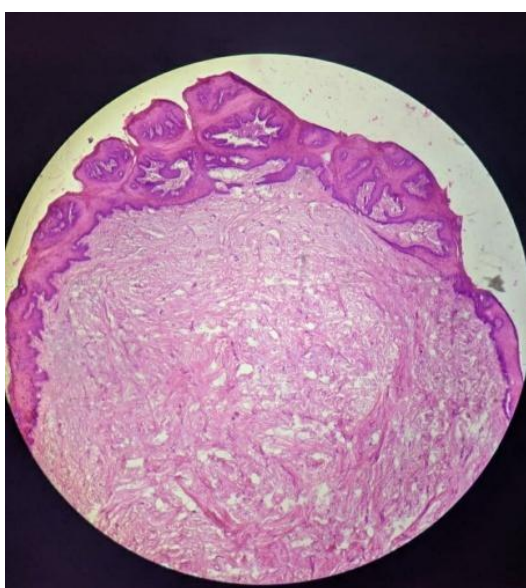


Figure 2: Squamous Papilloma

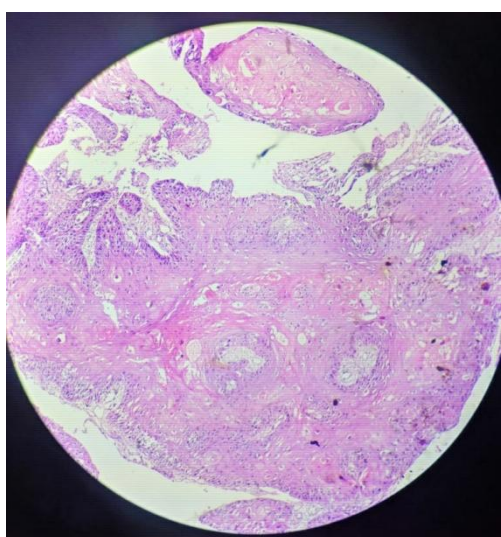


Figure 3: Squamous Cell Carcinoma

Discussion

Tumors of the larynx are usually detected early due to dysphonia i.e change in voice. Benign tumors were most common in the third decade, similar results reported by Hegde MC *et al.*⁴ and Singhal P *et al.*⁵ Malignant tumors were seen in between the age group of 41 -70 years with maximum occurrence between the age of 61 -70 years. Shirley D *et al.*⁶ stated that malignant tumors tend to increase with age, average age of diagnosis been 66 years.

In our study both malignant and benign malignant lesions were common in males as compared to female with M:F ratio of 2:1, these results were comparable with study by Wani *et al.*⁷. The male preponderance could be attributed to vocal abuse, occupation, smoking and drinking alcohol habits in males.

Non neoplastic lesions constituted about 39% of cases with vocal polyp being the commonest type. A vocal polyp is covered with stratified squamous epithelium and may exhibit a variety of changes in the stroma which include oedema, fibrosis, increased vascularity, haemorrhages and hyaline changes. In our study there were 16.7% cases of vocal polyp as compared to 16% in Chopra *et al.*⁸ and 31.4% in Kavitha Y *et al.*⁹.

Second most common non neoplastic lesion noticed was chronic non specific laryngitis with 11 cases (12.2%). Varalakshmi KP *et al.*¹⁰ reported 24.2% and 26% by Chavan SS *et al.*¹¹

Our study reported 8 cases(8.9%) of vocal nodule, similar finding was observed by Varalakshmi KP *et al*¹⁰ with 8.4% cases.

01 case (1.1%) of tuberculosis of larynx was observed in our study, this finding is in accordance with Varalakshmi KP *et al*¹⁰.(1.1%), Chaitanya V *et al*¹² (2.5%) and 3% by Kavitha Y *et al*⁹.

Neoplastic lesion constituted 61.1% of cases with 7.8% benign tumors and 53.3% malignant tumors. Among the benign neoplastic lesions, squamous papilloma was the predominant type. It is benign epithelial neoplasm formed by stratified squamous epithelium. These tumors are usually exophytic. 6.7% cases were seen in our study, this is correlated with Chavan SS *et al*¹¹ 6 %, Kavitha Y *et al*⁹ 8% and 10% by Chaitanya V *et al*¹².

01 case (1.1%) of hemangioma was observed in our study, similar result observed by Varalakshmi KP *et al*¹⁰ with 1.1% case.

Squamous cell carcinoma (47 cases) was the commonest malignant neoplasm comprising of 52.2% with majority of them being well differentiated followed by moderately differentiated squamous cell carcinoma. Varalakshmi KP *et al*¹⁰ reported 41.1% cases and 36.4% cases by Kavitha Y *et al*⁹. Squamous cell carcinoma often arises in a background of mucosal squamous dysplasia or carcinoma in situ and typically presents islands, tongues, and clusters of atypical cells invading the laryngeal stroma.

01 case (1.1%) of adenocarcinoma of larynx was reported in our study this is in accordance with Varalakshmi KP *et al*¹⁰ (1.1%).

Conclusion

The symptoms of laryngeal tumors can vary from mild hoarseness of voice to life threatening respiratory distress. All available methods should be utilised to make the diagnosis as early as possible. Laryngeal lesions can create lot of mental and emotional stress in the patient and family. Early diagnosis of the lesion can lead to effective management.

References

1. Beasley N. Anatomy of the larynx and tracheobronchial tree. In: Scott-Brown's otolaryngology, head and neck surgery, 7th edn edited by Micheal Gleeson. Great Britain: Hodder Arnold; 2008:2130-2144.
2. Sharma DK, Sohal BS, Bal MS, Aggarwal S. Clinicopathological study of 50 cases of tumors of larynx. Indian J Otolaryngol Head Neck Surg. 2013;65 (suppl 1):29-35.
3. Robin PE, Olofsson J (1997) Tumors of the larynx. In: Hibbert J (ed) Laryngology and head and neck surgery, 6th edn. Heinemann International, Great Britain, pp 1-9.
4. Hegde MC, Kamath MP, Bhojwani K, Peter R, Babu PR et al. Benign lesions of larynx-a clinical study. Ind J Otolaryngol and Head Neck Surg 2005;57(1):35-38.
5. Singhal P, Bhandari A, Chouhan M, Sharma MP, Sharma S et al. Benign tumors of larynx: A clinical study of 50 cases. Ind J Otolaryngol Head Neck Surg 2009,(suppl1);26-30.
6. Shirley D (1997) Cartilaginous lesions of the larynx. Grand rounds archives BCM. Bobby R Alford Department of otolaryngology: Head and neck surgery.
7. Wani AA, Rehman A, Hamid S, Akhter M, Baseena S. Benign mucosal fold lesion as a cause of hoarseness of voice. A Clinical study. Otolaryngology. 2012;2(3):120.
8. Chopra H, Kapoor M. Study of benign glottis lesions undergoing microlaryngeal surgery. Indian J Otolaryngol Head Neck Surg. 1997;49:276-9.
9. Kavitha Y, Chaitanya V, Basavaraju KP. Tumors and tumor like lesions of larynx : a clinicopathological study. Int J Otolaryngol Head Neck Surg 2018; 4:794-9.
10. Varalakshmi KP, Naik VS, Swapna RS, Sravani P, Padmaja MN. Laryngeal Biopsies with special references to

malignant tumors: A Histological study
.Int J sci stud 2016;4(3):197-202.

11. Chavan SS, Yewale AG.
Clinicopathological profile of patients with
benign laryngeal lesions. MedPulse
International Journal of ENT. September
2017;3(3):26-28.
12. Chaitnaya V, Nikethan B.
Clinicopathological study of non
neoplastic and neoplastic lesions of larynx.
Int J Intg Med Sci 2015;2(12):200-205.