



## Dyke Davidoff Masson Syndrome- A Case Report

Authors

**Sherry Garg, Sophia Garg**

Dr V M GMC Solapur

Email: [sophiagarg71@gmail.com](mailto:sophiagarg71@gmail.com), Mobile: 9464947605

### Abstract

*Dyke Davidoff Mason syndrome is an uncommon childhood cerebral clinical entity. It is generally grouped into congenital and acquired. The congenital type is intrauterine type and acquired occurs in early life. We are here, presenting a case of 15 years old boy that came with chief complaint of 4 episodes of seizures and was accidentally diagnosed with this syndrome. He was subsequently treated with anticonvulsants and discharged.*

### Introduction

Dyke Davidoff mason syndrome is an uncommon childhood cerebral hemiatrophy which evokes a spectrum of compensatory calvarial squeal. These include ipsilateral calvarial thickening, diploe widening, hyperpneumatization of paranasal sinuses/mastoids, elevation of petrous bone and small middle cranial fossa<sup>1</sup>. MRI is very effective in high lightening brain atrophy associated with parenchymal changes and even skull changes. It manifests as a clinical triad of hemiplegia, mental retardation and seizures.

It is of 2 types, primary (congenital) and secondary (acquired).

Primary cerebral atrophy (congenital) is due to lack of cerebral development. Development of brain is such that in a normal individual half of adult size of brain is attained in first year of life and by the end of third year it attains three fourth the adult size. The developing brain presses bony table outwards and gives general shape of head. Lack of this normal structure leads inward

growth of the structures and thus elevation of petrous ridge, greater wing of sphenoid, increased width of diploic space and frontal sinus enlargement<sup>2</sup>.

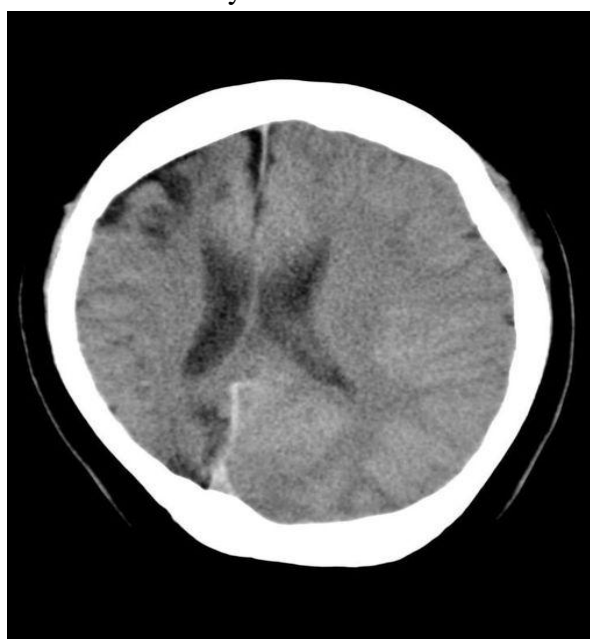
Secondary (acquired) is cerebral atrophy and could result from cranial trauma, cerebrovascular accident and inflammatory process. A clinical triad of mental retardation, hemiplegia and seizures is present<sup>3</sup>. A vascular anomaly during very early gestation results in a defect in brain development. Coarctation of aorta can lead to decreased carotid artery blood flow leading to cerebral hemihypoplasia<sup>4</sup>.

### Case Report

A 15 year old male was admitted with chief complaint of 4 episodes of seizures since last 3 days. He was apparently asymptomatic 3 days ago when he had an episode of seizure. It was a typical tonic clonic seizure. It was associated with frothing from mouth, uprolling of eyeballs and tonic clonic movement of all the four limbs. The

child regained consciousness after the post ictal phase. No previous history of seizures was documented. There was no history of trauma or drug intake. However he had a history of high grade fever at the age of 3 for which he had to be hospitalized. Although no records of the same were available. He also had mild weakness of left upper limb.

All his lab investigations were within normal limits. However, CT scan revealed the finding of small middle cranial fossa and right brain hemiatrophy with contralateral thickening of the calvarium which was suggestive of Dyke Davidoff Masson syndrome.



He was managed with anticonvulsants and supportive care. The patient improved gradually and was discharged on phenytoin sodium. It has been six months since then. He is on regular follow up and no other episode of seizure has been reported.

### Conclusion

Dyke Davidoff Masson syndrome has potential effects on the brain and development. Its differential diagnosis includes Sturge-Weber syndrome, Rasmussen encephalitis and Fishman syndrome. The treatment is mostly symptomatic. Awareness about this syndrome, the need for early diagnosis and proper management by medical,

surgical, supportive and rehabilitative therapy is warranted.

### References

1. DYKE CG, Davidoff L M and Masson C B, Cerebral Hemiatrophy and homolateral hypertrophy of skull and sinuses. Surg Gynecol Obstet 1933; 57: 588-600.
2. Alpers B J and Dear R B, Hemiatrophy of the brain. J Nervment Dis 1939; 89: 651-653.
3. Hageman G, Gooskens RHJM, Willememse J, A cerebral cause of arthrogryposis: Unilateral cerebral hypoplasia. Clin Neurosurg 1985; 87: s119-122
4. Parker C E, Harris N and Mavalwala J, Dyke-Davidoff-Masson syndrome: Five case studies and deduction from dermatoglyphics. Clinical Pediatrics 1972; 11(5): 288-292.