



Easy bone grafting technique for Anterior Cervical Discectomy and Fusion Surgery

Authors

P. Pallavan. M.ch.¹, Prof. Y.P. Jacob Grand.M.ch², Prof. M.M. Sankar Mch³,
S.Rajkumar Mch⁴ P.Mannar Mannan M.ch.⁵

^{1,5}Neuro surgery Post graduate

Government Stanley Medical College, Chennai, Tamilnadu, India

Abstract

Aim: Anterior Cervical Discectomy and Fusion (ACDF) surgery is a day care surgery in western countries. To achieve solid fusion in acdf surgery several methods like autogenous bone grft from Iliac crest, artificial G-bone graft, bone graft harvested from adjacent peripheral osteophytes are used. Even though autogenous iliac bone grafting method is the gold standard one, it is associated with donor site morbidity, G-bone grafts are associated with variable fusion rate and osteophyte bone grafting alone is inadequate to fill the spacer or cage to bridge the adjacent vertebral end plates. We are presenting our novel method of bone grafting technique in the form of Gel foam ball made with Gel foam, blood, and bone dust harvested from osteophytes used to fill the inter body fusion cage during surgery with satisfactory fusion rate. We consider this easy and new method is a viable alternative to traditional bone grafting techniques in view of no donar site morbidity, post operative complications and good fusion rate.

Keywords: ACDF, Iliac bone graft, Bone graft substitutes, Gel foam.

Introduction

Anterior cervical discectomy and inter body fusion (ACDF) has become standard surgical procedure for treating degenerative disc disease⁽⁵⁾ associated with radiculopathy or myelopathy. Bagby et al first did this procedure for horses.⁽¹⁾ Many modifications of the technique have been reported since its original description by Smith And Robinson^(4,6) and report by Cloward⁽²⁾. Although ACDF for treatment of degenerative cervical disease and cervical disc prolapse is a highly successful procedure, it remains debatable in using bone graft substitutes⁽³⁾ to avoid high donor site morbidity with Iliac bone grafting technique.

Some surgeons advocate osteophyte bone grafting technique but it is inadequate to fill the cages. To avoid this we are using Gel foam material mixed with blood and osteophytic bone dust to fill the inter body fusion cages in anterior cervical inter body fusion surgery. The purpose of the present study is to compare the clinical and radiological outcomes including bone fusion and subsidence occurred after anterior cervical discectomy and fusion with gelfoambone dust filled cages and Iliac bone graft filled cages.

Materials and Methods

Sixty seven patients who underwent anterior cervical discectomy and fusion using Titanium

cages for cervical degenerative disease^(7,8) and cervical disc prolapse from September 2014 to may 2018 were enrolled in this study. The Iliac crest bone grafting done in 19 cases as Group A and Gel foam+ bone dust+blood ball used in 48 cases as Group B. The Titaneumocta cage is used in all cases. All patients had cervical myelopathy or radiculopathy.

The indication for surgery included the medical history, clinical examination, imaging studies, and inadequate or no response to conservative treatment^(8,9,10.) All Patients evaluated at post op period,3 months,6 months and 12 months and annual follow up thereafter and compared in two groups. All patients diagnosed as cervical disc prolapse and degenerative^(11,12)condition.

To compare other variables such as age, sex, duration of symptoms, duration of surgery, outcome score using VAS, Neck disability index and neck active range of motion were documented and compared between two study group

Methodology

All patients with neck pain, radicular pain who are admitted in neurosurgical department are evaluated by detailed history, clinical examination and radiological evaluation with X-ray and MRI, pre-op VAS, Nurick scores confirmed cases were operated and clinical diagnosis confirmed pre-operatively. For all patients Clinical and radiological follow up was performed immediately after surgery and then one, three, six months after surgery. Spinal alignment and fusion status were assessed with antero-posterior and lateral (neutral, flexion, and extension radiographs.

Fusion was defined as less than 2° movement on lateral flexion/extension dynamic views, the presence of bridging trabecular bone between the endplates on AP/lateral views and less than 50% radiolucency in the perimeter surrounding the cage. Analysis of the radiographs included the grading of fusion, measurement of the inter body height ratio and the inter body angle. The fusion was graded as poor, average, good or excellent. In a poor fusion there were no trabeculae crossing

the disc space, there was interbody movement in the flexion-extension arc and there was no endplate reaction. In an average fusion there was no interbody movement, a few trabeculae crossing the disc space, but no end- plate reaction.

In a good fusion there was no interbody movement, numerous trabeculae crossing the disc space and some endplate reaction. In an excellent fusion there was no movement and the trabeculae crossing the disc space were of the same density as the adjacent bone. The endplate reaction was also complete so that the two vertebral bodies took on the appearance of one elongated vertebral body. Cervical lordosis was measured using Cobb's angle. Global alignment was measured by Cobb's angle between the inferior endplate of the C2 vertebral body and the inferior endplate of the C7 vertebral body. Regional alignment was measured using Cobb's angle between the upper endplate of the most cranial vertebral body and the lower endplate of the most caudal vertebral body. The interbody angle is that between the anterior borders of the two vertebral bodies as measured on a lateral radiograph. A negative value was given to those which were kyphotic and a positive value to those which were lordotic. Measurements were made on the preoperative films and those taken at six weeks, three and six months and one year. Cage subsidence was defined as greater than 6mm of distance between the midpoint of the upper margin of the upper vertebral body and the lower margin of the lower vertebral body. All data are analysed collected and analysed.

Results

In group A there are 35 males and 13 females. In Group B there are 17 male patients and two female patients, In group A there are 45 excellent type of fusion, five average type of fusion and one case of poor fusion. In group B there are 17 excellent type of fusion, two average type of fusion and no non fusion cases in this study. In both groups post operative cervical lordosis

achieved and cage subsidence present in no cases in this study.

Post operative VAS score, Neck Disability Index and total neck range of movement is full in excellent type of fusion achieved cases and restricted range of moment in other cases. Post

operative infection noted in no cases with both study groups. The operative time is drastically reduced in Group A patients, when compare with Group B. The fusion rate also comparatively same.

Table 1 Patient demographics and fusion particulars

S.no	Parameter		Group A		GroupB	
			Males	Females	Males	Females
1	Patients		35	13	17	2
2	Fusion	Excellent	30	11	16	0
		Average	5	1	1	0
		Poor	0	1		
3	Operating time		Short (35- 45 minutes)		More than one hour	
4	Average VAS score at six months		2		1	
5	NDI		Mild to moderate		Mild to moderate6	
6	Neck ROM at six months		92%		95%	



Figure 1 Gel Foam

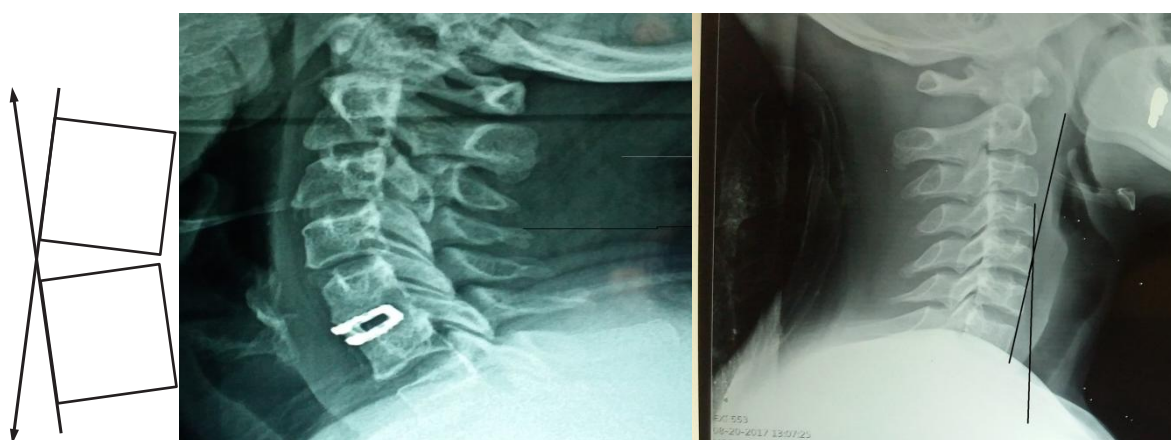

Figure 2 Anterior Cervical Diskectomy and Fusion Cage X-Ray Image with cervical normal cervical lordosis

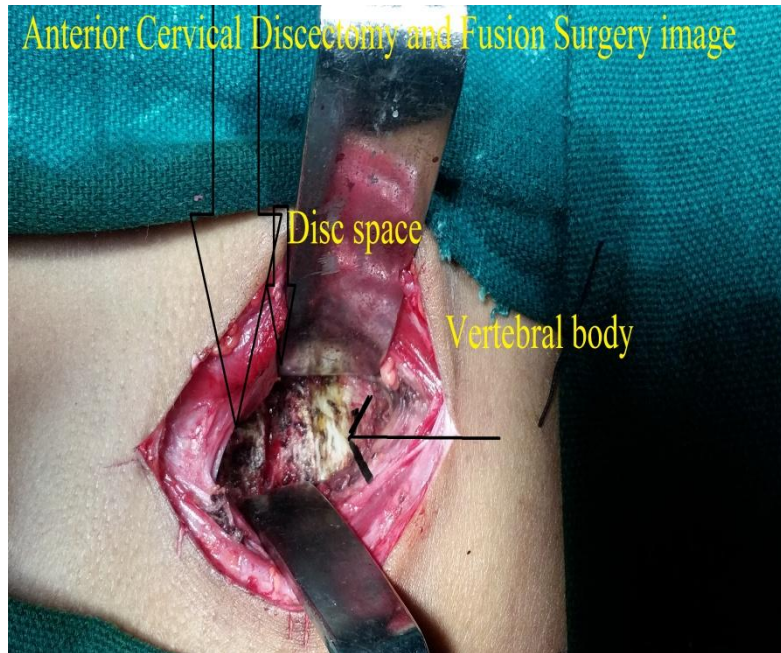


Figure 3 ACDF intra op image

Discussion

There is no difference in fusion rate in both the groups. The graft group took slightly longer to achieve fusion. Cage subsidence present in Five cases in Group A. The interbody angle at six months is not significantly vary in the two groups. In the same way, the NDI score is similar in both groups at six months. since pain from the graft donor site is a major reason for using a cage. The overall pain score is silar in both groups

Conclusion

This study shows good results with Gel foam, blood and osteophytic material filled cervical cages with compare to traditional iliac crest bone grafting. In view of shrrter operative time, lesser post op complications and slid union. This should be consider as an viable alternative for traditional bone healing.

Conflict of Interest: None to declare

References

1. Bagby GW. Arthrodesis by the distraction-compression method using a stainless steel implant. *Orthopaedics* 1988;11:931-4.

2. Cloward RB. The anterior approach for removal of ruptured cervical disks. *J Neurosurg* 1958;15:602-17.
3. Gore DR, Sepic SB. Anterior cervical fusion for degenerated or protruded discs. A review of one hundred forty-six patients. *Spine (Phila Pa 1976)* 1984;9:667-71.
4. Smith GW, Robinson RA. The treatment of certain cervical-spine disorders by anterior removal of the intervertebral disc and interbodyfusion. *J Bone Joint Surg Am* 1958;40-A:607-24.
5. Demircan MN, Kutlay AM, Colak A, et al. Multilevel cervical fusion without plates, screws or autogenous iliac crest bone graft. *J ClinNeurosci* 2007;14:723-8.
6. Barsa P, Suchomel P. Factors affecting sagittal malalignment due to cage subsidence in standalone cage assisted anterior cervical fusion. *Eur Spine J* 2007;16:1395-400.
7. Riley LH, Jr., Robinson RA, Johnson KA, et al. The results of anterior interbody fusion of the cervical spine. Review of ninety-three consecutive cases. *J Neurosurg* 1969;30:127-33.

8. Walker AE, Robinson RA. [Anterior cervical fusion]. *Dia Med* 1962;34 (Special):894-900.
9. Savolainen S, Rinne J, Hernesniemi J. A prospective randomized study of anterior single-level cervical disc operations with long-term follow-up: surgical fusion is unnecessary. *Neurosurgery* 1998;43:51-5.
10. Bagby GW. Arthrodesis by the distraction-compression method using a stainless steel implant. *Orthopaedics* 1988;11:931-4..
11. Katsuura A, Hukuda S, Saruhashi Y, et al. Kyphoticmalalignment after anterior cervical fusion is one of the factors promoting the degenerative process in adjacent intervertebral levels. *Eur Spine J* 2001;10:320-4.
12. Cho DY, Lee WY, Sheu PC. Treatment of multilevel cervical fusion with cages. *Surg Neurol* 2004;62:378-85, discussion 85-6.
13. Kumar MN, Baklanov A, Chopin D. Correlation between sagittal plane changes and adjacent segment degeneration following cervical spine fusion. *Eur Spine J* 2001;10:314-9.
14. Bagby GW. Arthrodesis by the distraction-compression method using a stainless steel implant. *Orthopaedics* 1988;11:931-4.