



Morphological Spectrum of Pediatric Central Nervous System Tumors- A seven year study from Central India

Authors

Avinash Gupta^{1*}, Sukhpreet Kaur², Hanni G Vasudev³

*Corresponding Author

Avinash Gupta

Formerly Senior Resident BMHRC Bhopal, India

Abstract

Introduction: Tumors of the nervous system are important cause of cancer-related deaths in children. There are several reports regarding the epidemiology of CNS tumors in children in the Western literature but too few reports from India.

Material and Methods: A retrospective study was done on all the pediatric CNS tumors (less than 18 years) that were received in Pathology department over duration of seven years at Bhopal Memorial Hospital and Research Centre, Bhopal, India. All the adult CNS cancers were excluded in the study. All the selected cases were analyzed for age, sex, location of tumour and histomorphological findings, special stain and Immunohistochemical markers.

Results: Pediatric CNS tumor constitutes 10.25 % (48/468) of total CNS tumors. Age range from 3 to 18 years with mean age of 11.2 years, Male: female ratio is 1.1:1. Children (0-14years) accounted for 34 cases with 16 males (47%) and 18 (53%) females. Adolescents (>14-18years) accounted for 14 cases with 9 males (64%) and 5 females (36%). 66.6% tumors are infratentorial or spinal while 33% are supratentorial. Frequency of infratentorial/spinal tumor is high in both children as well as pediatric group. Histopathologically astrocytic tumors were most common (33.6%) and pilocytic astrocytoma (15%) is most frequent astrocytic tumor. Embryonal tumours constitute 25.3% cases.

Conclusion: Due to limited resources, in this context, the adequate epidemiologic data is lacking from India. The present study was done to profile the prevalence of pediatric CNS tumors (according to the WHO classification 2016) in a tertiary care setup in Central India having good neurosurgical and neuropathology facilities, and the data was compared with international studies.

Keywords: CNS tumors, Pediatric tumors.

Introduction

Tumors of the nervous system are the second most common childhood tumor after leukemia, constituting approximately 35% of all childhood malignancies and remain the leading cause of cancer-related deaths in children.⁽¹⁾

Childhood central nervous system (CNS) tumors differ significantly from adult brain tumors in

reference to their sites of origin, clinical presentation, tendency to disseminate early, histological features and their biological behavior.⁽²⁾ Whereas in adults the predominant CNS tumor types are metastases, glial neoplasms and meningiomas, in children, besides gliomas, other major tumor types including primitive embryonal neoplasms are also common.⁽³⁾

In recent times, distinct molecular and genetic pathways and therapeutic approaches for each tumor type lead to an enhanced understanding of these biological differences between adult and childhood CNS neoplasms. There are several reports regarding the epidemiology of CNS tumors in children in the Western literature. Due to lack of resources, in this context, the adequate epidemiologic data lacks from India. Thus it is imperative to find out the prevalence and spectrum of different CNS tumors in pediatric age group and analyse the presenting signs and symptoms, location of tumour and histomorphological findings, special stain and Immunohistochemical markers.

Material and Methods

This is a retrospective study. We will include all the pediatric CNS tumors (less than 18 years) that were received in Pathology department between January 2010 to December 2016 at BMHRC, Bhopal, India. All the selected cases will be analyzed for age, sex, location of tumour and histomorphological findings, special stain and Immunohistochemical markers. Adult population suspected metastatic tumors, tumour-like cystic lesions and space occupying lesions of infectious etiology were excluded. Cases were diagnosed according to WHO (2016).⁽⁴⁾

Note

- Diagnosis of many tumors is based on the combined phenotypic and genotypic characteristics. At this point of time our institute lacks access to new IHC markers like IDH1, ATRX, TERT and molecular diagnostic testing of these tumors. As recommended in the new classification a diagnostic designation NOS (i.e., not otherwise specified) is permissible for some tumour types. "NOS" designation defines a group of lesions that cannot be classified into any of the more narrowly defined groups. The tumors were diagnosed according to 2016

World health organization (WHO) classification system⁽⁴⁾.

- Astrocytoma – Astrocytoma, NOS
- Glioblastoma – Glioblastoma, NOS
- Embryonal tumors – Medulloblastoma, NOS +PNET+AT/RT.

Hemangiopericytoma (HPC) and solitary fibrous tumors (SFT) are combined in a single category of SFT/HPC and assigned three grades

Study Duration: Retrospective data of last of six years at Bhopal Memorial Hospital and Research Centre, Bhopal, India from January. 2010 to December 2016 was taken and entered in MS Excel.

Results

In the present study pediatric CNS tumor constitutes 10.25% (48/468) of total CNS tumors. Age range from 3 to 18 years with mean age of 11.2 years, Male: female ratio is 1.1:1. Cases are further grouped as Children (0-14years) and Adolescents (>14-18years) Children (0-14years) accounted for 34 cases with 16 males (47%) and 18 (53%) females. Adolescents (>14-18years) accounted for 14 cases with 9 males (64%) and 5 females (36%). 66.6% tumors are infratentorial or spinal while 33% are supratentorial. Frequency of infratentorial/spinal tumor is high in both children as well as pediatric group. The histopathological spectrum and mean age these 48 cases of pediatric brain tumors are shown in table 1. Histopathologically Astrocytic tumors were most common (33.6%) and pilocytic astrocytoma (15%) is most frequent astocytic tumor. Embryonal tumors are the second most common tumour found in this study, constituting 25.3% cases. Embryonal tumor includes medulloblastoma, Primitive neuroectodermal tumor (PNET) and Atypical teratoid/rhabdoid tumor (AT/RT). Other less frequent cases includes schwannoma 10.3%, ependymoma 8-3%, craniopharyngioma 6-3% hemangiopericytoma/solitary fibrous tumor 4-2%.

Table 1 The histopathological spectrum and mean age of pediatric brain tumors

Histologic type	No of cases	%	Mean age	M:F
Pilocytic astrocytoma	07	15.0	10.28	0.4:1
Diffuse astrocytoma, NOS	04	8.3	12.75	1:1
Pilomyxoid astrocytoma	01	2.0	13	1
Glioblastoma, NOS	04	8.3	12.25	0.3:1
Total astrocytic tumors	16	33.6	12.07	0.6:1
Ependymoma	04	8.3	14.75	3:1
Schwannoma	05	10.3	16.6	3:2
Medulloblastoma, NOS	09	19.0	7.22	2:1
SFT/ Hemangiopericytoma	02	4.2	15	1
CNS embryonal tumour ,NOS/PNET	03	6.3	8.5	1:2
Craniopharyngioma	03	6.3	11.33	2:1
Germinoma	01	2.0	12	M
Pineoblastoma	01	2.0	14	F
Meningioma	01	2.0	15	M
Non Hodgkins Lymphoma –B cell type	01	2.0	5	M
Chordoma	01	2.0	6	F
Lipoma with tethered cord	01	2.0	9	F

Discussion

CNS tumors are the second most common childhood tumors after leukemia. (Approx. 35% of all childhood malignancies) and Leading cause of cancer-related deaths in children. Mean age in

present study is 11.2 and M: F ratio is 1.1:1 which is similar to previously published studies. Table 2 and 3 compares mean age and M: F ratio between our study and other Indian and international studies.

Table 2 Comparison of age and sex from Indian studies

Study name	Present study	Subhlaxmi et al ⁽⁵⁾	Harshil et al ⁽⁶⁾	Ayushi jain et al ⁽³⁾	Sangeeta et al ⁽⁷⁾
Study period	6yrs	2.5 yrs	2yrs	variable	15
Total number of cases	48	61	76	3936	239
Age group	0-18yrs	0-15 yrs	0-19	0-18	0-18
Mean age	11.2yrs	9.3 yrs	10.69	-	-
M:F	1.1:1	-	1.2:1	-	1.2:1

Table 3 Comparison of age and sex from international studies

Study name	Present study	Germany (Kaatsch et al ⁽⁸⁾)	Pakistan (Ahmed et al ⁽⁹⁾)	Nigeria (Gabriel et al ⁽¹⁰⁾)	Japan (Makino et al ⁽¹¹⁾)
Total number of cases	48	3,268	81	77	210
Age group	0-18 yrs	<15	<15	<15	<15
Mean age	11.2 yrs	10.7	8.8	7.2	NS
M:F	1.1:1	1.2:1	2.5:1	1.3:1	1.3:1

Comparison of location: Infratentorial and spinal tumors were more common than supratentorial tumor in present study. Similar findings were published by Ahmed et al⁽⁹⁾ (Pakistan). However Kaatsch et al⁽⁸⁾ (Germany) and Gabriel Olabiyi Ogun et al⁽¹⁰⁾ (Nigeria) found Equal ratio between

supra- and infra-tentorial tumors. Other studies of Rosemberg et al⁽¹⁾, Zhou et al⁽¹²⁾, Asirvatham et al⁽¹³⁾, Pinho et al⁽¹⁴⁾ respectively from China, South Korea, India and Brazil show a preponderance of supratentorial tumors.

Morphologic spectrum: In our study, the two commonest pediatric tumors were pilocytic astrocytomas and medulloblastomas. Similar results were shown in the study published by Sengupta et al⁽⁶⁾. Astrocytic tumors are the most common Pediatric Brain tumors usually located in Cerebellum (posterior fossa). Pilocytic astrocytoma (grade-I) was the most common astrocytic tumor in our study. (~17% of all CNS tumors in 0–14 year olds). Comparison of astrocytic tumors from other studies of India is shown in Table 4. Embryonal tumors were the second most common constituent of this study and most common non astrocytic tumour. Embryonal tumors - develops from embryonic cells remaining

in the CNS after birth. Overall embryonal tumor incidence ranged from 0.28–0.80 cases/1 lakh children (0–14 years). There are three major embryonal tumor types (1) Medulloblastoma (MB)- Avg. annual age-adjusted incidence rate 0.20–0.58 cases/1 lakh persons.(2) Primitive neuroectodermal tumor (PNET)- Average annual age-adjusted incidence rates from 0.08–0.21 cases/100,000 children.(3) Atypical teratoid/rhabdoid tumor (AT/RT)-0.07-0.14/100,000. Medulloblastoma (mb): Most common embryonal tumors(19%) in the present study and all cases have posterior fossa involvement. Mostly occurs in 0-14 yr age group.

Table 4 Comparison of astrocytic tumors with other studies from India

Study name	Present study No / %	Subhlaxmi et al ⁽⁵⁾ %	Harshil et al ⁽⁶⁾ %	Ayushi jain et al, ⁽³⁾ %	Sangita et al ⁽⁷⁾ %
Pilocytic astrocytoma	07/15.0	22.9	17.1	Grade I-23.1	13
Pilomyxoid astrocytoma	01/2.0	-	1.3		
SEGA			1.3		2.5
Pleomorphic xanthoastrocytoma			2.6		1.7
Diffuse astrocytoma, NOS	04/8.3	11.4	10.5	5.1	9.2
Anaplastic astrocytoma, NOS		Grade ¾-14.7%	2.6	Grade ¾- 6.5	2.0
Glioblastoma, NOS	04/8.3		2.7		2.9
Oligoastrocytoma, NOS					4.1
Total astrocytic tumors	33.6	49	38.1	34.7	46.8

Table 5 Comparison of non-astrocytic tumours with other studies from India

Study name	Present study, No %	Subhlaxmi et al, ⁽⁵⁾ %	Harshil et al, ⁽⁶⁾ %	Ayushi jain et al, ⁽³⁾ %	Sangita et al, ⁽⁷⁾ %
Ependymoma	04/8.3	8.1%	6.6	9.8	12.5
Oligodendroglioma, NOS	-	4.9%		1.1	10
Medulloblastoma, NOS	09/19.0	22.9%	22.4	Medullo +PNET- 22.4	Medullo +PNET- 18.4
CNS Embryonal tumors, NOS/ PNET	03/6.3		5.3		1.3
Schwannoma	05/10.3		2.6	3.6	2.9
Craniopharyngioma	03/6.3	9.8%	11.8	10.2	9.2
SFT/ Hemangiopericytoma	02/4.2				

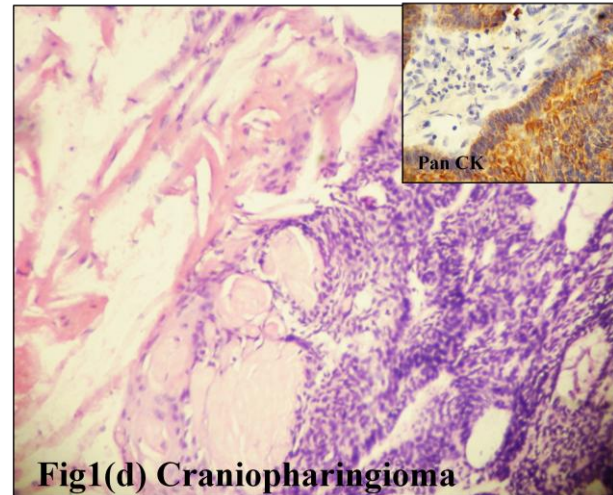
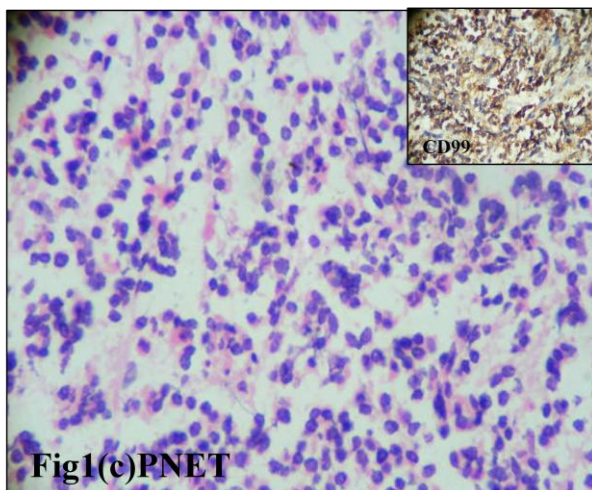
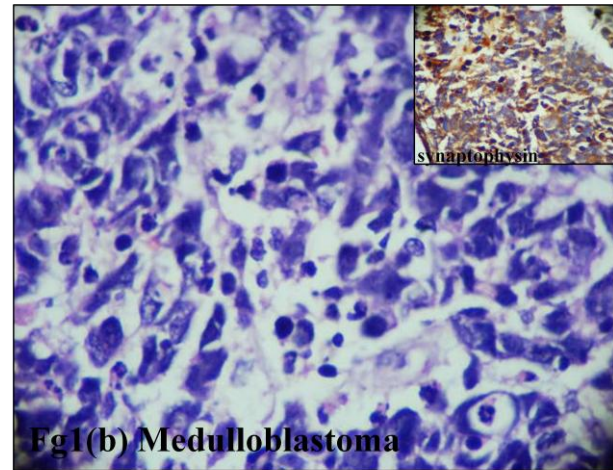
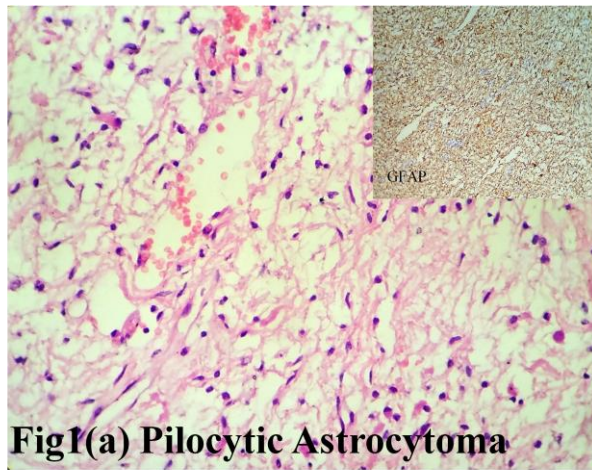


Fig 1. Shows common pediatric tumors with corresponding immunohistochemistry in inset

Conclusion

The frequencies of various tumors except few at our institute were well within range of national and international data. Astrocytomas and medulloblastomas form major histologic type in pediatric patients followed by embryonal tumors. Infratentorial site is the most common location. This study provides a baseline for understanding the epidemiological aspects of pediatric tumors of the nervous system and opens gate for future studies as per new WHO classification.

References

- Rosemberg S, Fujiwara D. Epidemiology of pediatric tumors of the nervous system according to the WHO 2000 classification: a report of 1,195 cases from a single institution. *Childs Nerv Syst ChNS Off J Int Soc Pediatr Neurosurg.* 2005 Nov;21(11):940-4.
- Jemal A, Siegel R, Ward E, Murray T, Xu J, Smigal C, *et al.* Cancer statistics, 2006. *CA Cancer J Clin* 2006;56:106-30.
- Jain A, Sharma MC, Suri V, Kale SS, Mahapatra AK, Tatke M, *et al.* Spectrum of pediatric brain tumors in India: A multiinstitutional study. *Neurol India* 2011;59:20811.
- Louis DN, Perry A, Reifenberger G, Deimling A v, Figarella-Branger D, Cavenee WK *et al.* The 2016 World Health Organization Classification of Tumors of the Central Nervous System: a summary. *Acta Neuropathol.* 2016;131:803–20.
- Sengupta S, Chatterjee U, Banerjee U, Ghosh S, Chatterjee S, Ghosh A. A study of histopathological spectrum and expression of Ki-67, TP53 in primary brain tumors of pediatric age group Indian

- Journal of Medical and Paediatric Oncology 2012;33(1);25-31.
6. Shah HC, Ubhale BP, Shah JK. Demographic and histopathologic profile of pediatric brain tumors: A hospital based study. South Asian J Cancer 2015 ;4:146148
 7. Margam S R , Gadgil N M , Kshirsagar GR, Gaikwad VP, Kumavat PV, Chaudhari CS. The Histopathological and Epidemiological Study of Pediatric Brain Tumors in A Tertiary Care Hospital, Mumbai. Annals of Pathology and Laboratory Medicine 2016;03(05);375-81.
 8. Kaatsch P, Rickert CH, Kühl J, Schüz J, Michaelis J. Population-based epidemiologic data on brain tumors in German children. Cancer 2001;92:3155-64.
 9. Ahmed N, Bhurgri Y, Sadiq S, Shakoor KA. Pediatric brain tumours at a tertiary care hospital In Karachi. Asian Pac J Cancer Prev 2007;8:399404.
 10. Ogun, G. O., Adeleye, A. O., Babatunde, T. O., Ogun, O. A., Salami, A., Brown, B. J., & Akang, E. (2016). Central nervous system tumours in children in Ibadan, Nigeria: a histopathologic study. The Pan African Medical Journal, 24, 34. 2016.24.34.9344.
 11. Makino K, Nakamura H, Yano S, Kuratsu J, Kumamoto Brain Tumor Group. Population-based epidemiological study of primary intracranial tumors in childhood. Childs Nerv Syst 2010;26:1029-34.
 12. Zhou D, Zhang Y, Liu H, Luo S, Luo L, Dai K. Epidemiology of nervous system tumors in children: A survey of 1,485 cases in Beijing Tiantan Hospital from 2001 to 2005. Pediatr Neurosurg 2008;44:97103.
 13. Asirvatham JR, Deepti AN, Chyne R, Prasad MSN, Chacko AG, Rajshekhar V et al. Pediatric tumors of the central nervous system: a retrospective study of 1,043 cases from a tertiary care center in South India. Childs Nerv Syst. 2011 Aug;27(8):1257-63.
 14. Pinho RS, Andreoni S, Silva NS, Cappellano AM, Masruha MR, Cavalheiro S et al. Pediatric central nervous system tumors: a single-center experience from 1989 to 2009. J Pediatr Hematol Oncol. 2011 Dec;33(8):605-9.