



## A Rare Case of Autoimmune Encephalitis

Authors

**Dr Amit Kumar, Dr Vivek Shejole**

NKPSIMS Nagpur, India

### Abstract

*Autoimmune encephalitis is a diverse group of neuro psychiatric disorders recognized recently, presenting acutely or subacutely with alteration of consciousness, cognitive decline, seizure, and abnormal movements. We report a femal presented with Fever, Headache and Involuntary Movements of all 4 limbs with perioral twitching, 3 episodes of GTCS in the last 7 days.*

### Introduction

Autoimmune encephalitis is a diverse group of neuro psychiatric disorders recognized recently, presenting acutely or subacutely with alteration of consciousness, cognitive decline, seizure, and abnormal movements. Hashimotos Encephalitis was first described by Brain et al in 1966.

Other names for the disorder include steroid-responsive encephalopathy associated with autoimmune thyroiditis (SREAT).

Average age is 47 years (range 14 to 78 years) and majority of patients are women. Two types of clinical presentation are commonly observed. first form is focal neurologic deficits. It may be associated with speech problems (transient aphasia), focal or generalized seizures and status epilepticus.

Second form is of insidious onset, progressing to dementia, psychosis and coma over several weeks without any focal neurologic deficits. Associated features include lack of concentration, sleep

abnormalities, headaches, tremors, myoclonus and ataxia.

Diagnosis of autoimmune encephalopathy is based on the clinical course, serologic evidence of autoimmunity, severe but nonspecific slowing on electroencephalography, and evidence of intrathecal inflammation in the cerebrospinal fluid and neuroimaging by MRI.

### Case Report

Previously healthy a 28 year married woman presented with Fever, Headache and Involuntary Movements of all 4 limbs with perioral twitching, 3 episodes of Generalized Tonic Clonic Seizures in the last 7 days. She had no h/o jaundice. No h/o rash, bleeding from any site. No h/o travel. No h/o weakness of any limb.

Patient had already received Inj. Artesunate and T. Doxycycline for the same at a private hospital.

### On examination

Patient was Stuporous, Afebrile,

Pulse: 120/min/regular

BP-120/70, Pallor was present

### CNS examination

Patient was agitated, anxious, showed bizarre behaviour, paucity of speech. Twitching of left sided facial muscle associated with rigidity and involuntary movement of all 4 limbs, Sensory system- normal, Deep tendon reflexes: normal, Plantars were flexors, Pupils: Normal size reacting to light, Rest all other systems were within normal limit.

### Investigations

CBC: Haemoglobin: 12 gm/dl, Total Leukocyte Count-11800, Neutrophils-88, Lymphocyte-10, Eosinophil-1, Myelocyte-1, Platelets-4.41 lacks, MALARIAL ANTIGEN- Negative, DENGUE- Negative, HIV- Negative

Kidney Function Test: Blood urea Nitrogen-33mg/dL, CREATININE-1.04 Na-150, K-3.9, Liver Function Test: within normal limit, MRI BRAIN: within normal limit, EEG-Mild degree of non specific Generalised Electrophysiologic Dysfunction. T3-0.8 ngm/ml (0.8-2.0 ngm/ml), T4-6.15µgm/100 ml (5.1-14.1 µgm/100ml) and TSH 3.5 µU/ml (0.5-5 µU/ml), IONISED CALCIUM-1.19 mMol/Lt (1.0-1.32 mMol/Lt), URINE-No abnormality detected, CSF: TOTAL PROTEINS-52.4, glucose-98, ADA-3.69, TOTAL CELLS-NIL, USG ABDOMEN/PELVIS- Within normal limit.

### MRI Brain

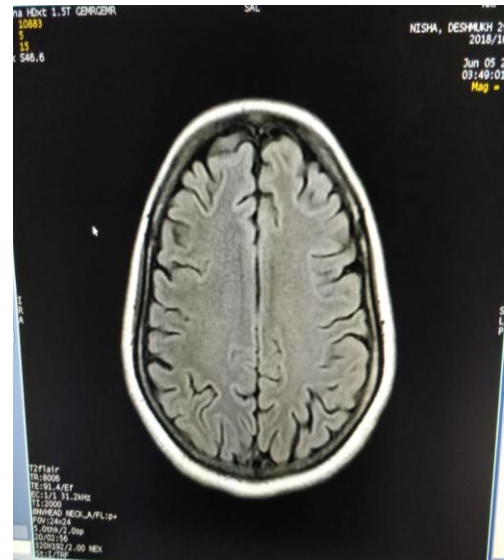
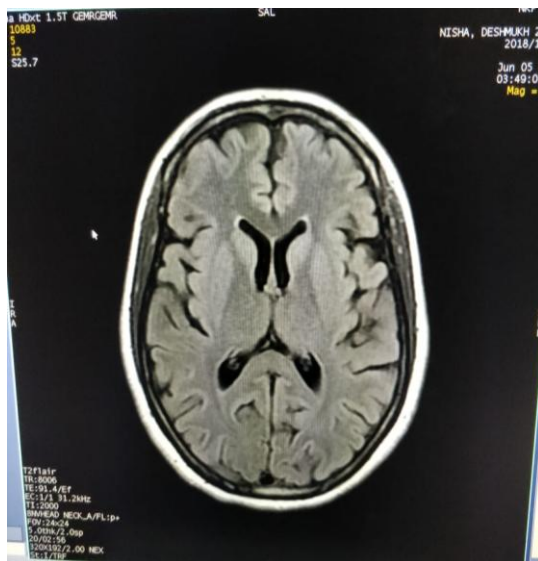
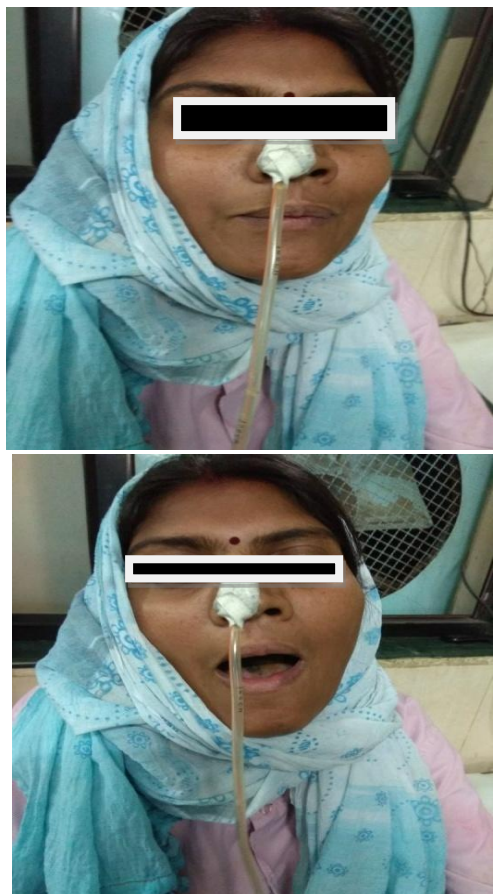

Figure1: MRI picture in our patient.

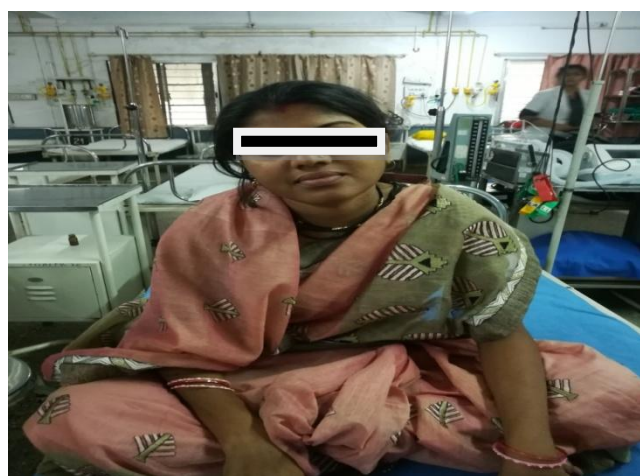### Course and Management

Anti-Malarials and Anti-epileptic drugs (Sodium Valproate and Levetiracetam) were continued as it was already started. Neurologist opinion was taken and he suspected Autoimmune encephalitis for which anti NMDA receptor antibody (serum) & Anti-TPO Ab was sent, patient was not affording for Anti LGI 1 and Anti GABA B receptor antibody. Meanwhile patient was started on pulse Methylprednisone therapy and continued on oral steroids. Throughout her course of illness, the patient was conscious oriented and had no episodes of seizures. Patient was then started on Syndopa 110mg ½ tab TDS and Pacitane 2mg (trihexyphenidyn) TDS, Gradually patient responded to above therapy and involuntary movements decreased over a period of time and later disappeared completely.

Anti TPO-Ab: positive with high titres (522 IU/ml, normal <34 IU/ml), Anti NMDA receptor antibody (serum): negative. Hence, a diagnosis of Hashimotos Encephalitis was made.



**Figure 2:** Before treatment



**Figure 3:** After treatment.

### Discussion

Autoimmune encephalitis is a diverse group of neuro psychiatric disorders recognized recently, presenting acutely or subacutely with alteration of consciousness, cognitive decline, seizure, and abnormal movements.

Exact pathogenesis of HE is unknown. It is considered to be an autoimmune encephalopathy because of its higher prevalence in females,

fluctuating course, association with other autoimmune disorders and improvement with corticosteroid therapy. It is associated with anti-TPO and anti-thyroglobulin (anti-Tg) antibodies. But the precise role of antithyroid antibodies is unclear. No shared antigen has been identified between thyroid gland and brain. Alpha-enolase (isoenzyme of enolase, a glycolytic enzyme) has been identified as an auto-antigen for the disease. Antithyroid antibody titers also do not correlate with disease severity.

Diagnosis of autoimmune encephalopathy is based on the clinical course, serologic evidence of autoimmunity, severe but nonspecific slowing on electroencephalography, and evidence of intrathecal inflammation in the cerebrospinal fluid and neuroimaging by MRI. Patients of HE may have subclinical or overt hypothyroidism, or patients may be euthyroid.

CSF usually reveals elevated protein level, Glucose level is normal. Normal CSF examination may be present in up to 25% of cases.

EEG shows diffuse or generalised slowing or frontal intermittent rhythmic delta activity.

MRI may be normal or reveal nonspecific findings, such as diffuse cerebral atrophy, focal mesiotemporal, basal ganglia or white matter abnormalities.

Patients with HE respond dramatically to steroid therapy, High dose intravenous methylprednisolone (1 gm / day) may be given for initial three to seven days, followed by oral prednisolone therapy. Azathioprine, cyclophosphamide, chloroquine, methotrexate may be used as steroid sparing agent. Periodic intravenous immune globulin and plasma exchange are other therapeutic options.

### Conclusion

Young female with sudden onset neurological symptoms of involuntary movements or seizures with or without fever should be suspected of having autoimmune encephalitis after exclusion of other common causes of encephalitis. Very high level of awareness is needed to diagnose HE

because of its rarity, variety of presentations and high chance of misdiagnosis. It is important to recognize HE as it is potentially reversible and treatable disease. The disease is highly responsive to steroid.

### References

1. Reid, A. H.; McCall, S.; Henry, J. M.; Taubenberger, J. K. (2001-07-01). "Experimenting on the past: the enigma of von Economo's encephalitis lethargica". *Journal of Neuropathology and Experimental Neurology*. 60 (7): 663–670. doi:10.1093/jnen/60.7.663. PMID 11444794
2. Adam and victors principles of neurology  
Harrisons principle of internal medicine  
Brain L, Jellinek EH, Ball K. Hashimoto's disease and encephalopathy, *Lancet* 1966;2:512–14.