



Copper Peptides in Acne Scars

Authors

Prem Kumar¹, Sundaramoorthy Srinivasan²

Chettinad Hospital and Research Institute, Kelambakkam, Chennai, India

Email: ¹cpremb4u@gmail.com, ²hamsrini@yahoo.co.in

Abstract

Background: Atrophic facial scars are a most common complication of acne which is difficult to treat, especially deep-seated scars and which involve much of the face. Dermaroller therapy has been proved to be a good treatment option which provides an excellent reduction in acne scars. Copper peptides is a newer treatment option which has been evaluated to give excellent results in scar reduction.

Objective: To compare the efficacy of using dermaroller alone and dermaroller combined with copper peptides and assess the reduction in the severity of acne scars

Methods: Twenty four patients who had atrophic facial acne scars were selected and divided into two groups. One group was treated with dermaroller alone and the other group was treated with dermaroller with copper peptides. Both the group were offered with five sittings at an interval of 1 month between successive sittings. The scars were graded using Goodman and Baron quantitative grading pre-operatively and at each sitting with serial of photographs taken to validate the result.

Results: The mean score of the dermaroller group was 11.42(n=12) and dermaroller with copper peptide was 12.92(n=12) which reduced to 8.50 in the dermaroller group and 6.50 in the dermaroller with copper peptide group which were 26.30% and 50.30% decrease from the mean value respectively. Boxcar scars reduced to 77.78%, rolling scars reduced to 34.79%, ice-pick scars did not change with the copper peptide group. Both the group had a p-value<0.05, which was statistically significant.

Conclusion: Dermaroller remains a safe and effective treatment option, but when compared with copper peptides, it gives better results, most commonly with boxcar scars.

Keywords: Acne scars, Copper peptides, Dermaroller, Goodman and Baron quantitative scoring.

Introduction

In the era of Cosmetic Dermatology, nearly every person wants to look pleasing. Acne vulgaris is a chronic inflammatory condition of the pilosebaceous unit. Owing to the decreased self-confidence, every person tends to pick& scratch leading to acne scars. These scars can physically and emotionally affect the patients. Hence, they tend to visit dermatologists late and will be difficult to treat owing to the chronicity. There is

no effective treatment modality which can deliver 100 percent results. Hence combined procedures are being used or switching over different techniques in between is recommended. Acne's prevalence is 90% with 12-20% having psychological implications. Many studies are not there to denote the severity of acne scar but there are many studies to denote the severity of acne, more the scarring, more the physical and psychological stress to the patient.^[1] Scars are

marks on the skin following healing of a wound. Fibroblasts in dermis helps in granulation tissue development. Masses of granulation tissue forms a scar. Scars are elevations or depressions with the difference in colour, blood supply, nerve supply, skin colour, protective features accounting to the huge difference in the role of skin. More severe the scars, more the time required to treat the disease. In the year 1500, the abrasive features of pumice and alabaster were used by the Egyptians for uneven skin tone which formed the basis for the recent dermabrasion. In 1882, the shedding of the horny layers of epidermis caused by salicylic acid, trichloroacetic acid & phenol were elaborated by Unna. Phenol peel procedure was first done by Eller & Wolff in 1941. Then, came into existence, the 'Workhouse laser'- the CO₂ laser in the year 1964. Subcision was brought by Orentreich in the year 1995.^[2] In the year 2006, derma roller was used for Percutaneous Collagen Induction therapy. It was introduced by Fernandes.^[3]

Methods

Patient who was diagnosed with acne scar and fulfilling the inclusion (Age: 18-35 years, Rolling and boxcar scars) and exclusion criteria (Age below 18 years and above 35 years, Ice-pick, hypertrophic and atrophic scars, Active inflammatory acne) and visiting a Tertiary care hospital were taken into study. A detailed dermatological examination was done by counting the acne scar lesions and grading them. Clinical photographs of the lesions were taken before, during and after treatment completion. Scoring was done pre-operatively by Goodman and Baron quantitative scoring.^[4] Patients were divided randomly into two groups. Patients in Group A were given treatment with dermaroller alone and patients in Group B were treated with dermaroller with copper peptides. Dermaroller used for all patients were 1.5mm sized needles and copper peptide concentration used for 1%. Lignocaine cream 1% was used for all patients and applied for

45 mins before commencing the procedure and the patient was asked to wait. Then lignocaine cream was removed, wiped with sterile gauze and patient was advised to wash the face and then the procedure was done under aseptic precautions.

The dermaroller was rolled over the face in a horizontal, vertical and diagonal direction nearly 10-15 times till superficial pin-point bleeding is seen. The GROUP B were treated with dermaroller as described above, and then copper peptides was applied directly and left off, and the patients were advised to wash their face after 6 hrs. Patients were advised to apply sunscreens daily after the procedure and to avoid using other anti-acne medications or any other topical facial applications and advised to avoid anti-fibrinolytic during the study period. The study period was 18 months with 5 months for each subject (one sitting every month for five months)

Scoring was done pre-operatively and for each successive sessions. In this study, most commonly, the scars were present in between the two imaginary lines, one line is drawn from the lateral canthus of eye to the tip of the helix of ear on the same side and the other line from the angle of mouth to the angle of the mandible, and the remaining area affected were negligible. [Fig 1]

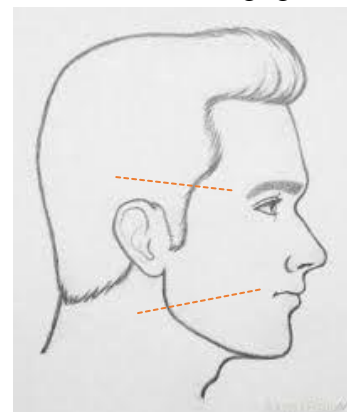


FIG 1: Area of the face taken into study



Figure 2: Dermaroller and Copper peptide used in this study

Both Group A and B patients were advised to review in a time gap of 1 month for the next sitting. A maximum of 5 sittings was done for them. Clinical photographs taken on subsequent sittings to assess the progress using Goodman and Baron grading. (Fig-3a-d;4a-d)

Efficacy of treatment was assessed by the Goodman and Baron grading and scoring was calculated every sitting. The interval between two sessions was 1 month and scoring also was done at successive sessions for 5 sittings.

Derma roller with Copper Peptides

Pre-OP

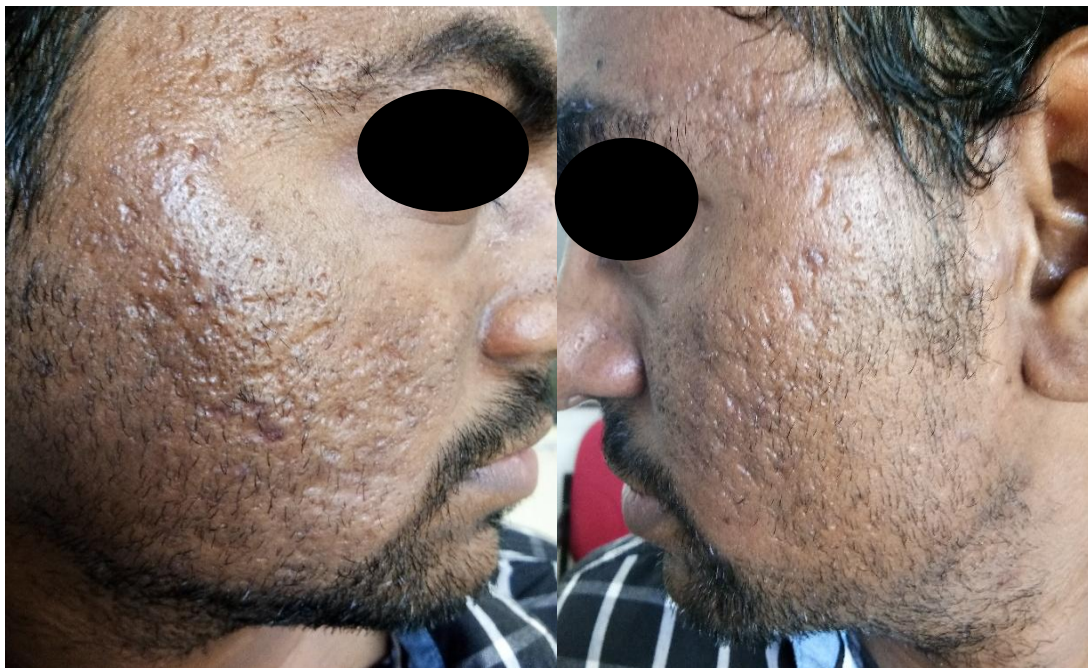

Figure 3a : Right side of the face

Figure 3b : Left side of the face

After 5th Sitting

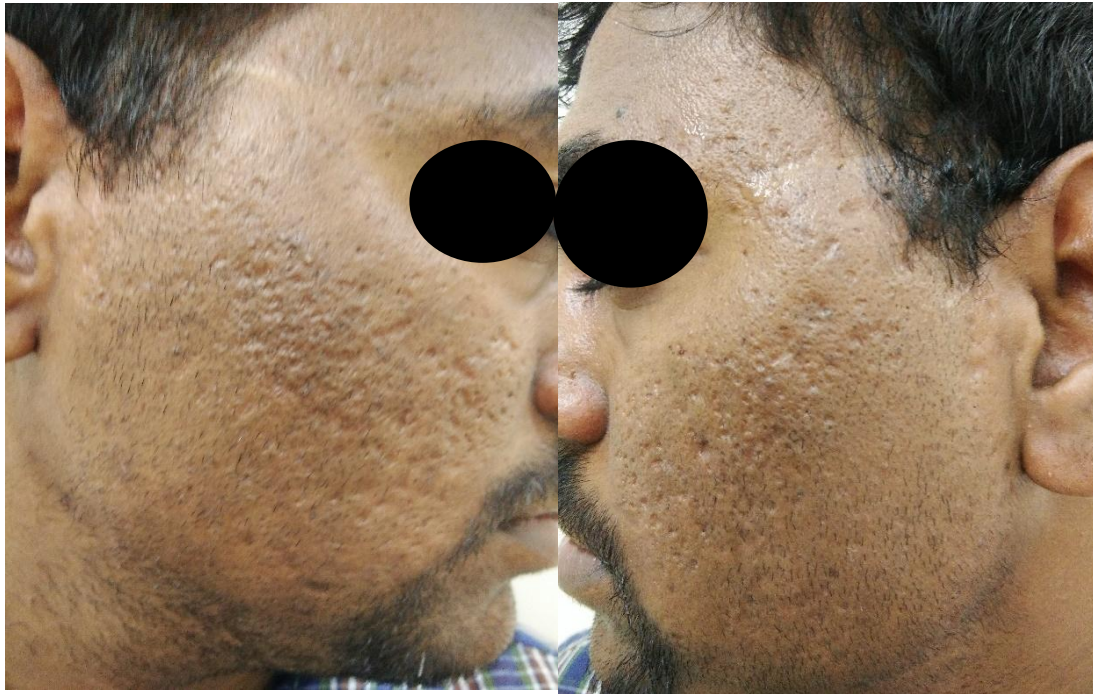


Figure 3c: Right side of the face

Figure 3d: Left side of the face

Derma roller

Patient 17

Pre-OP:-



Figure 4a: Right side of the face

Figure 4b: Left side of the face

After 5th Sitting

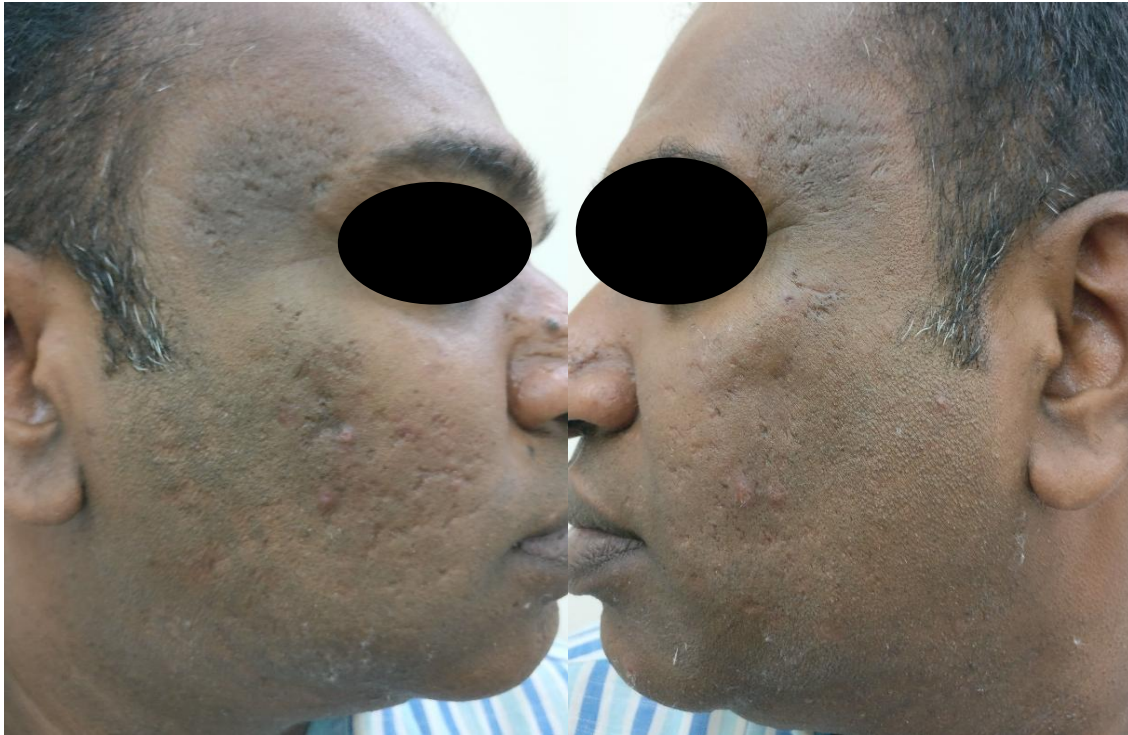


Figure 4c : Right side of the face

Figure 4d: Left side of the face

Statistical Analysis

The mean score of the dermaroller group was 11.42(n=12) and dermaroller with copper peptide was 12.92(n=12). And the mean score was reduced to 8.50 in the dermaroller group and 6.50 in the dermaroller with copper peptide group which were 26.30% and 50.30% decrease from the mean value of dermaroller and dermaroller with copper peptide group respectively. P value was calculated which was 0.167 and 0.159 at the start point for dermaroller and dermaroller with copper peptides group respectively(p>0.05).

At the fourth sitting, p-value decreased to 0.052(p=0.05) for the dermaroller group, which was clinically significant but not statistically, but the dermaroller with copper peptide group's p-value decreased to 0.049(p value<0.05) which was both clinically and statistically significant.

At the end of the fifth sitting, p-value decreased to 0.004(p=0.05) for dermaroller group, which was statistically significant (95%), but the dermaroller with copper peptide group value decreased to 0.003(p value<0.05) which was statistically more significant (99%) than the dermaroller group.

The error bar diagram shows the decrease in mean +/- standard deviation of both groups. Even though the mean value was high initially in the dermaroller group, it declined drastically compared to the dermaroller group at the end of the 5th sitting.

The mean score of the dermaroller group was 11.42 at the start point which decreased to 8.50 at the end of the 5th sitting. Even though, the mean score was 12.92, the mean score was reduced to 6.50 at the end of 5th sitting indicating that copper peptides worked well with acne scars.

The total score of boxcar scars in the dermaroller group was 54 at start point which decreased to 27 at the end of 5th sitting (50% decrease). And the score was 81 at the start point in the dermaroller with copper peptide group which decreased to 18 which is 77.78 % decrease from the start point indicating the drastic decrease in boxcar scars with the help of copper peptides.

The total score of rolling scars in the dermaroller group was 58 at start point which decreased to 46 at the end of 5th sitting (20.69% decrease). And the score was 46 at the start point in the dermaroller with copper peptide group which

decreased to 30 at the end of 5th sitting which is 34.79 % decrease from the start point indicating a moderate decrease in rolling scars with the help of copper peptides, when compared to the dermaroller group.

The total score of boxcar scars in the dermaroller group was 32 at start point which decreased to 29 at the end of 5th sitting (9.38% decrease). And the score was 24 at the start point in the dermaroller with copper peptide group which remained the same at the end of 5th sitting indicating that there is no change in ice-pick scars with the help of copper peptides, although dermaroller had some effect.

The total score of boxcar, rolling and ice-pick scars were summed together and the total score in the dermaroller group was 144 at start point which decreased to 102 at the end of 5th sitting (29.17% decrease). And the score was 151 at the start point in the dermaroller with copper peptide group which decreased to 72 at the end of 5th sitting which is 52.32 % decrease from the start point indicating the decrease in total scars is higher in copper peptides group than dermaroller group.

Discussion

The standard dermaroller has a 12 cm long handle and a 2 × 2 cm wide drum-shaped cylinder at one end with 8 rows and 24 circular arrays of 192 fine microneedles, usually 0.1-0.25 mm in diameter and 0.5-3mm in length⁽⁵⁾ These micro-needles are for one time use and are produced by reactive ion engraving techniques on medical grade stainless-steel and silicon. The pre-sterilization of the instrument is done by gamma irradiation. When the standard dermaroller containing 192 needles of 2 mm length and 0.07 mm diameter is rolled over an area of skin for 15 times results in approximately 250 holes/cm² to the papillary dermis, and it totally depends on the pressure applied.⁽⁶⁾ Each pass/roll produces 16 micropunctures in the stratum corneum/cm².⁽⁷⁾ These micro-punctures causes superficial pin-point bleeding and sets a cascade of wound healing processes with the release of various

growth factors such as Fibroblast Growth Factor(FGF), Platelet Derived Growth Factor (PDGF), Transforming Growth Factor-alpha and beta(TGF- α and β), connective tissue growth factor and connective tissue activating protein.⁽⁸⁾ The old hardened fibrotic scar is broken down by the needles which promote revascularization. Migration and proliferation of fibroblasts and laying down of the intercellular matrix is activated which promotes neovascularization and neo-collagenesis.^(9,10) A fibronectin matrix is formed after 5 days of injury which controls the deposition of collagen which determines the persistence of skin tightening for 5–7 years in the form of collagen III. The depth of neo-collagenesis has been found to be 5–600 μ m with a 1.5 mm length needle. Histology of the skin after 4 micro needling sittings 1 month apart showed a 400% increase in collagen and elastin deposition at 6 months, with a thickening of stratum spinosum and normal rete ridges at 1 year postoperatively.⁽¹¹⁾ Collagen fiber bundles take the normal lattice pattern comparing to parallel bundles as in scar tissue.⁽⁷⁾ Liebl *et al.* have proposed another hypothesis on the pathophysiology.⁽¹¹⁾ The resting electrical membrane potential of cells is around -70 mV, and when needles reaches the cell membrane, the inner potential increases quickly to -100 mV. This will initiate accentuation of cell activity and the release of proteins, growth factors and potassium from the cells into the outer aspect which leads to the migration of fibroblasts to the injured site, and thus promotes collagen induction. Thus, the needles in the real sense do not create a wound.^(10,11,12,13) The increased expression of matrix metalloproteinases (MMP) induced by microneedling is speculated in the reduction of hyperpigmentation.⁽¹¹⁾ In addition, the hyperproliferation of keratinocytes is down regulated by microneedling in acne patients because it overall balances out the cell equilibrium.⁽¹¹⁾ However, more research needs to be done to elucidate the chain of events clearly. This procedure will extrapolate the body's own

physiology of healing and the deposition of new collagen and hence result in skin tightening and filling of atrophic scars with better appeal since ablation of overlying epidermis is not there.

Five types of dermarollers, which are registered with the FDA, have been used in the dermaroller series by Konstantinos, and most of the dermarolling devices are divided into these basic types:⁽¹⁴⁾ C-8 (Cosmetic type), C-8 HE (the Cosmetic type for hair-bearing surfaces, scalp), CIT-8 (CIT: Collagen Induction Therapy, Medical type), MF-8 type and MS-4. The commercially used dermarollers with minor variations available in the market are home care dermaroller, beauty mouse, Dermapen.

In 1973 by Loren Pickart, Copper glycine-histidine-lysine (Cu-GHK) was developed from human albumin that caused old human liver tissue to produce proteins like young tissues^[15]. In the late 80s, the first copper peptide was made an ingredient into skin care products. After that peptide development increased slowly which had a major role in extracellular matrix synthesis, innate immunity, pigmentation, and inflammation. These are used for collagen stimulation and wound healing, wrinkle smoothing effect, as well as antioxidative, antimicrobial^[16], and whitening effects. Owing to the skin barrier, the molecular weight of peptides should always be less than 500 Da, otherwise the peptide cannot penetrate the barrier. Newer studies state that larger molecules can traverse the skin barrier, in the case of dry and aged skin^[17,18]. GHK (glycyl-L-histidyl-L-lysine) is a group of amino acids which are present in human plasma, urine and saliva and goes down with age. It has been stated that GHK always functions as a complex with Cu²⁺ and helps in repairing the skin and acceleration of wound healing. GHK stimulates both the production and destruction of collagen and glycosaminoglycans and also modulates the activity of both metalloproteinases and its inhibitors. It plays a major role in the formation of chondroitin sulfate, dermatan sulfate, collagen and the proteoglycan, decorin. It also restores the replication capacity of

fibroblasts. GHK is a nothing but a tripeptide with the amino acid sequence glycyl-histidyl-lysine. GHK level in plasma is 200 ng/mL (10^{-7} M) at the age of 20 but gradually decreases to 80 ng/ml at the age of 60. This decline in the GHK-level denotes the noticeable decrease in the regenerative capacity of an individual.. The activity of the tripeptide sequence has a strong affinity for copper and it readily forms a complex with copper^[19].

The structure of GHK-Cu is depicted below.

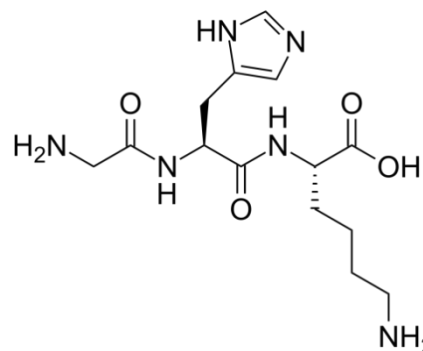


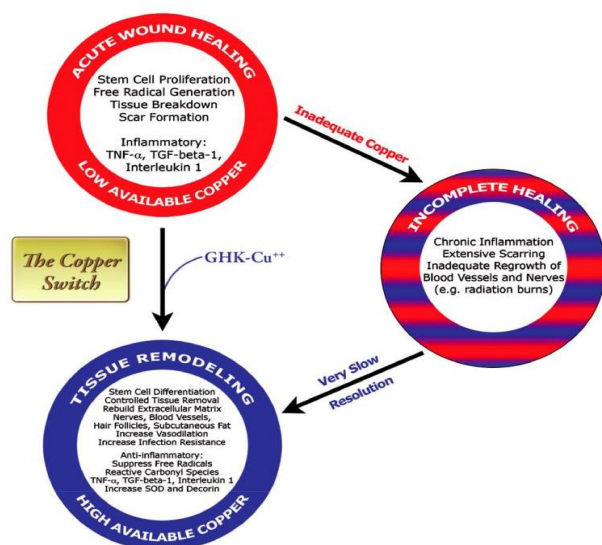
Figure 11: Structure of Copper peptides

Pickart et al stated that GHK-Cu

- increases wound healing and contraction,
- increases the take of transplanted skin
- anti-inflammatory activity^[16,20,21].
- stimulates both synthesis and breakdown of collagen and glycosaminoglycans
- modulates the activity of both metalloproteinases and their inhibitors (TIMP-1 and TIMP-2), thus its the main regulator of wound healing and skin remodeling processes^[17,18].
- Stimulates the formation of collagen, dermatan sulfate, chondroitin sulfate, and a small proteoglycan, decorin^[22].
- Restoration of replicative ability to fibroblasts after anticancer radiation therapy that damages the cellular DNA^[23].
- Attract immune and endothelial cells to the injured site^[24].
- increased angiogenesis and antioxidant enzymes. This molecule also
- Healing of many non-healing wounds like diabetic and ischemic wounds,

- Decreases the level of TNF-alpha and stimulates collagen synthesis.

All these studies led GHK-Cu to be used as a skin remodelling agent.



Derma roller of needle size 1.0mm is used for superficial acne scars. When the scars are deep, 2.0 mm is chosen, so as to provide an equal platform for all scars, all the patients were subjected to treatment with 1.5mm. The same needle depth was used by Cachafeiro T et al⁽²⁵⁾, Baveja S.⁽²⁶⁾. Histological examination of the skin treated with 4 microneedling sessions 1 month apart shows upto 400% increase in collagen and elastin deposition at 6 months postoperatively, with a thickened stratum spinosum and normal rete ridges at 1 year postoperatively.⁽¹⁾ Hence the interval between two sittings in this study was also 1 month.

Out of the 24 patients, from the age group of 18-35, 15 patients (62.5%) were from the age group of 20-25. And from the age group of 30-35, only two patients(8.33%) were enrolled In a study by Dogra et al.(2014) the age group of the study were from 18 to 40 years, and all the patients belonged to skin types IV and V.^[28,29]

Most of the patients in my study were IT Professionals and students with a total number of 8 patients in each, leading to a total of 16 patients (66.67%) out of the total 24 patients.

The patients whose nature of the occupation needs meeting more number of people or attention seeking professions (actor, salesman, students who goes to college meeting many friends, IT professionals) are the ones who were more concerned and gave consent in this study, which included a total of 18 patients (75%), out of which 9 patients (37.5%) were under each group even after randomisation.

There were a total of 22 patients who gave history of manipulating the lesions of acne (91.67%).

The acne scars present in between the two imaginary lines, one line from the lateral canthus of eye to tip of helix of the ear on the same side and the other line from the angle of mouth to the angle of mandible on the same side. The patients who had scars isolated to the above mentioned area were 9 in number (37.5%) and the remaining 15 patients(62.5%) had scars extending beyond the area(most commonly in the temporal area- 13 patients-(54.17%).

The mean score of the dermaroller group was 11.42(n=12) and dermaroller with copper peptide was 12.92(n=12). And the mean score was reduced to 8.50 in the dermaroller group and 6.50 in the dermaroller with copper peptide group which were 26.30% and 50.30% decrease from the mean value of dermaroller and dermaroller with copper peptide group respectively. One clinical trial was conducted by Dogra et al in the year 2014 which evaluated the utility of microneedling for treating atrophic acne scars in Asian populations.^[29] On an objective scale of 18 points, patients' assessments of their scars decreased from 11.73 to 6.5(44.61% decrease) following five microneedling treatments^[29] comparing to 26.30% decrease in dermaroller group in this study. This study was graded using Goodman ad Baron Quantitative scoring system and this study had an increased results compared with the dermaroller group of this study, but a decreased response when compared to dermaroller with copper peptides in this study, indicating the better response of copper peptides in acne scars. Another clinical study was conducted by Majid

where 36 out of the total of 37 patients completed the treatment schedule and were evaluated for its efficacy. Out of these 36 patients, 34(91.89%) achieved a reduction in the severity of their scarring by one or two grades.^[30] In a study done by Garg S and Baveja S^[176], fifty patients with atrophic acne scars were graded using Goodman and Baron Qualitative grading. Subcision, dermaroller and 15% TCA peel were performed alternatively at 2-weeks interval for a total of 6 sessions of each. Grading of acne scar photographs was done pre-treatment and 1 month after last procedure. Out of 16 patients with Grade 4 scars, 10 (62.5%) patients improved to Grade 2 and 6 (37.5%) patients improved to Grade 3 scars. Out of 22 patients with Grade 3 scars, 5 (22.7%) patients were left with no scars, 2 (9.1%) patients improved to Grade 1 and 15 (68.2%) patients improved to Grade 2. All 11 (100%) patients with Grade 2 scars were left with no scars.^[31] This study was based on qualitative decrease in acne scarring when compared with quantitative grading system used in this study, which is more reliable. The adverse effects in this study were minimal. There were 4 patients (16.67%) with post inflammatory hyperpigmentation [three in derma roller group(12.5%) and one in dermaroller with copper peptide group(4.17%)]. This adverse effect were attributed to the poor compliance in applying sunscreens in 3 patients(12.5%)- 2 in dermaroller group(8.33%) and 1 in dermaroller with copper peptide group(4.17%). There were no significant adverse effects in the study done by Majid.(2009). At the end of 5 sittings, each patient were given questionnaire regarding the procedure. They were asked to rate the procedure with a score between 0-5. Out of the 24 patients in this study, 5 patients gave a maximum score of 5(20.83%), 8 patients gave a score of 4(33.33%), 7 patients gave a score of 3(29.16%), 3 patients gave a score of 2(12.5%), and 1 patient gave a score of 1(4.17%). The high score given by patients were 5 were attributed to the minimal expectation of the patient and the knowledge of patient about the expected outcome. In a study done by Majid (2009), the patients who

participated in the study were also asked to evaluate the effectiveness of the treatment received on a 1-10 point scale and more than 80% of patients assessed their treatment as 'excellent' on a 10-point scale.^[30] Thus in both the studies, the efficacy of dermaroller treatment was assessed both subjectively by the patients as well as objectively by a single observer. Patient's own evaluation was also done in Garg and Bavejastudy.^[176]

Boxcar scars were first analysed. The maximum value of a boxcar scar with Goodman and Baron classification is 108. The mean value obtained at the start of the procedure was 4.5(50% of the total value-54) and 6.75(75% of the total value). At the end of 5th sitting, the mean value reduced to 2.25 in both the groups (which is 25% of the total value), thus derma roller with copper peptide group showed a significant decrease in the boxcar scars than compared to dermaroller.

Rolling scars were analysed. The maximum value a rolling scar can have according to Goodman and Baron quantitative classification is 72. At the start of the procedure, the mean score was 4.89 and 3.83 in the dermaroller and dermaroller with copper peptide group respectively which was 80.55% and 63.89% of the total value respectively. At the end of five sittings, the mean value decreased to 3.67 and 2.5 in the dermaroller and derma roller with copper peptide group (61.11% and 41.67% of the total value). This also indicates that the significant decrease was noted more in the copper peptide group.

Ice-pick scars were analysed. The maximum value an ice pick scars can have is 36. At the start of the procedure, the mean score was 2.67 and 2 in the dermaroller and dermaroller with copper peptide group respectively, which was 88.89% and 66.67% of the total value respectively). At the end of five sessions, the mean value decreased to 2.25 and 2 in derma roller and derma roller with copper peptide group respectively, which was 83.33% and 66.67% respectively). Thus, it shows that there is no reduction in the ice-pick scars on

copper peptide group, whereas there is a mild decrease in the value of the dermaroller group.

In this study, P value was calculated which was 0.167 and 0.159 at the start point for dermaroller and dermaroller with copper peptides group respectively ($p > 0.05$). At the fourth sitting, p-value decreased to 0.052 ($p = 0.05$) for the dermaroller group, which was clinically significant but not statistically, but the dermaroller with copper peptide group's p-value decreased to 0.049 ($p \text{ value} < 0.05$) which was both clinically and statistically significant. At the end of the fifth sitting, p-value decreased to 0.004 ($p = 0.05$) for dermaroller group, which was statistically significant (95%), but the dermaroller with copper peptide group value decreased to 0.003 ($p \text{ value} < 0.05$) which was statistically more significant (99%) than the dermaroller group. In a study done by Cachafeiro T et al, forty-six patients with atrophic facial acne scars, which were randomized into microneedling and non-ablative fractional erbium laser 1340nm groups performed monthly for 3 sessions, it was shown that both groups showed a significant improvement, and there was no statistically significant difference between results of both therapies ($p = .264$).^[25]

Conclusion

Dermaroller is a simple, and economical for the treatment of acne scars. It has favourable advantages as the epidermis remains intact, decreasing risks and negative side effects of other invasive modalities. Boxcar scars were reduced much with copper peptides, followed by rolling scars when compared to dermaroller group. Ice-pick scars did not respond much in both the groups. Even though dermaroller give results in treating acne scars, but when copper peptides are added, it is an efficient procedure since, it is cheap and its gives faster excellent results and also gives suppleness to the skin. The adverse effects in this study were minimal. Only post inflammatory hyperpigmentation was seen. Dermaroller with copper peptide procedure for acne scar revision is

cost effective and non-invasive. It is accepted by all patients invariable of age, sex, occupation and social status.

Limitations: nil

Declaration of patient consent: The authors certify that they have obtained all appropriate patient consent forms. In the form the patients have given their consent for their images and other clinical information to be reported in the journal. The patients understand that their names and initials will not be published and due efforts will be made to conceal their identity, but anonymity cannot be guaranteed.

Financial support and sponsorship: Nil.

Conflicts of interest: There are no conflicts of interest.

References

1. Breathnach SM, McGrath JA. Wound healing. In: Bunts T, Breathnach S, Cox N, Griffiths C, editors, Rook's textbook of dermatology. 7th ed. Oxford: Blackwell Science Ltd. 2004, p. 11.1- 11.25.
2. Orentreich DS, Orentreich N. Subcutaneous incisionless (subcision) surgery for the correction of depressed scars and wrinkles. *Dermatol Surg* 1995; 21: 543-9.
3. Fernandes D Minimally invasive percutaneous collagen induction. *J Oral Maxillofac Surg Clin North Am*. 2005; 17:51-63.
4. Goodman GJ, Baron JA. Postacne scarring-a quantitative global scarring grading system. *J Cosmet Dermatol* 2006; 5: 48-52.
5. Camirand A, Doucet J. Needle dermabrasion. *Aesthet Plast Surg* 1997; 21:48-51.
6. Fernandes D. Minimally invasive percutaneous collagen induction. *Oral Maxillofac Surg Clin North Am* 2006; 17:51-63.
7. Bhardwaj D. Collagen induction therapy with dermaroller. *Community Based Med J* 2013; 1:35-7.

8. Nair PA, Arora TH. Microneedling using dermaroller: A means of collagen induction therapy. *GMJ* 2014;69:24-7.
9. Falabella AF, Falanga V. Wound healing. In: Freinkel RK, Woodley DT, editors. *The Biology of the Skin*. New York: Parthenon; 2001. p. 281-99.
10. Fabbrocini G, Fardella N, Monfrecola A, Proietti I, Innocenzi D. Acne scarring treatment using skin needling. *Clin Exp Dermatol* 2009;34:874-9.
11. Aust MC, Fernandes D, Kolokythas P, Kaplan HM, Vogt PM. Percutaneous collagen induction therapy: An alternative treatment for scars, wrinkles, and skin laxity. *Plast Reconstr Surg* 2008;121:1421-9.
12. Liebl H, Kloth LC. Skin cell proliferation stimulated by microneedles. *J Am Coll Clin Wound Spec* 2012;4:2-6.
13. Jaffe L. Control of development by steady ionic currents. *Fed Proc* 1981;40:125-7.
14. Anastassakis K. The Dermaroller Series. http://www.mtoimportadora.com.br/site_novo/wp-content/uploads/2014/04/Dr.-Anastassakis-Kostas.pdf. [Last accessed on 2016 Jun 22].
15. Zelles T, Purushotham KR, Macauley SP, Oxford GE, Humphreys-Beher MG. Saliva and growth factors: the fountain of youth resides in us all. *J Dent Res*. 1995;74(12):1826-32. Review
16. Ehrlich P. Symposium on collagen and skin repair. *Reims*. Sept 1991 (12)
17. Siméon A, Emonard H, Hornebeck W, Maquart FX. The tripeptide-copper complex glycyl-L-histidyl-L-lysine-Cu²⁺ stimulates matrix metalloproteinase-2 expression by fibroblast cultures. *Life Sci*. 2000; 22;67(18):2257-65.
18. Siméon A, Wegrowski Y, Bontemps Y, Maquart FX. Expression of glycosaminoglycans and small proteoglycans in wounds: modulation by the tripeptide-copper complex glycyl-L-histidyl-L-lysine-Cu(2+). *J Invest Dermatol*. 2000;115(6):962-8
19. Pickart L. The human tri-peptide GHK and tis-sue remodeling. *J. Biomater. Sci. Polymer Edn*. 2008; 19(8):969-988
20. Maquart FX, Pickart L, Laurent M, Gillery P, Monboisse JC, Borel JP. Stimulation of collagen synthesis in fibroblast cultures by the tripeptide-copper complex glycyl-L-histidyl-L-lysine-Cu²⁺. *FEBS Lett*. 1988; 10;238(2):343-6
21. Wegrowski Y, Maquart FX, Borel JP. Stimulation of sulfated glycosaminoglycan synthesis by the tripeptide-copper complex glycyl-L-histidyl-L-lysine-Cu²⁺. *Life Sci*. 1992;51(13): 1049-56
22. Sayani K, Dodd CM, Nedelec B, Shen YJ, Ghahary A, Tredget EE, Scott PG. Delayed appearance of decorin in healing burn scars. *Histopathology* 200; 36(3): 262-272
23. Zhang Z, Li XJ, Zhang X, Li YY, Xu WS. Recombinant human decorin inhibits cell proliferation and downregulates TGF-beta production in hypertrophic scar fibroblasts. *Burns* 2007; 33(5):634-641
24. McCormack MC, Nowak KC, Koch RJ. The effect of copper peptide and tretinoin on growth factor production in a serum free fibroblast model. *Arch facial Plast. Surg*. 2001; 3(1):28-32
25. Cachafeiro T et al. Comparison of Nonablative Fractional Erbium Laser 1,340 nm and Microneedling for the Treatment of Atrophic Acne Scars: A Randomized Clinical Trial. *Dermatol Surg*. 2016 Feb;42(2):232-41
26. Garg S., Baveja S. Combination therapy in the management of atrophic acne scars. *Cutan Aesthet Surg*. 2014;7(1):18-23.
27. Sharad J. Combination of microneedling and glycolic acid peels for the treatment of acne scars in dark skin. *J Cosmet Dermatol*. 2011 Dec;10(4):317-23.
28. Simran Chawla. Split Face Comparative Study of Microneedling with PRP Versus

- Microneedling with Vitamin C in Treating Atrophic Post Acne Scars. *J Cutan Aesthet Surg*. 2014 Oct-Dec; 7(4): 209–212
29. Dogra S., Yadav S., Sarangal R. Microneedling for acne scars in Asian skin type: an effective low cost treatment modality. *J Cosmet Dermatol*. 2014;13:180–187.
30. Majid I. Microneedling therapy in atrophic facial scars: an objective assessment. *J CutanAesthet Surg*. 2009 Jan;2(1):26-30.
31. Garg S., Baveja S. Combination therapy in the management of atrophic acne scars. *CutanAesthet Surg*. 2014;7(1):18–23.