



## Soft tissue lasers: A new paradigm for the treatment of Ankyloglossia

Authors

**Navneet<sup>1\*</sup>, Devashish<sup>2</sup>, Oliver Jacob<sup>3</sup>, Manab Kosala<sup>4</sup>**

<sup>1</sup>Junior Resident (Periodontology), <sup>2</sup>Pedodontist,

<sup>3</sup>Junior Resident (Periodontology), <sup>4</sup>Professor (Periodontology)

Dept of Dental Surgery, Armed Forces Medical College, Pune, Maharashtra, India

\*Corresponding Author

**Navneet**

### Abstract

*Lingual Frenum is defined as a triangular tissue fold that creates connection between tongue, lip and buccal musculature to the alveolar bone. It maintains a balance between the growing hard and soft tissues in the development phase of the foetus and also plays a role in limiting the lips, cheeks and tongue movement<sup>(1)</sup>. Ankyloglossia is an anomaly which is congenital in nature and where lingual frenum attachment is abnormal. This is a case series of 3 paediatric cases of ankyloglossia two aged 4 and 5 years respectively and one 14 years of age who were successfully treated by diode laser.*

**Keywords:** Ankyloglossia, diode laser, lingual frenectomy, tongue tie.

### Introduction

Prevalence of ankyloglossia is around 4.4% to 4.8% in new-borns, with a male predilection of 3:1. According to Wallace tongue-tie is “a condition where the tongue tip cannot be moved beyond the mandibular incisor teeth be due to short lingual frenum”<sup>(2)</sup>.

Ankyloglossia is the most common developmental anomaly seen in tongue where a small, thick lingual frenum limits the movement of tongue causes problems in feeding and speech. Delay in early finding of this problem results in social, speech and behavioural problems in suffering individual. If diagnosed and treated early in childhood by frenectomy, problems with speech can be corrected by speech therapy. If not treated on time speech therapy may not improve individual's speech problems.

Ankyloglossia in children may lead to breastfeeding difficulties, poor oral hygiene and speech disorders. With growth milder forms can get corrected by itself but severe forms can require intervention irrespective of age. In children, feeding problems can be a manifestation of ankyloglossia whereas in adult swallowing and speech problems, dental caries may be more prevalent. In elderly, it may cause dentures problems. Spreading of lower incisors, periodontitis, malocclusions such as opening of bite because of pressure created by being tongue-tied and mobile teeth because of long-term tongue thrust.

### Case Report

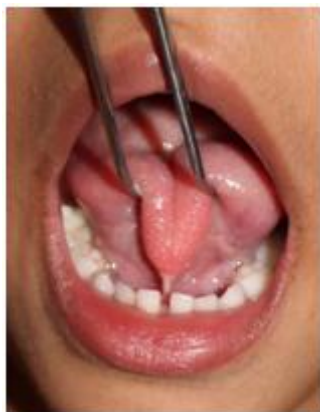Two children aged between 4-6 years and one aged 14 year reported to opd with a complaint of inability to move tongue freely. Intraoral examination revealed complete ankyloglossia (Figures 1 & 2) as per Kotlow's classification it was classified as class

IV (Figure 2). After due informed consent was taken from parents, case was planned for lingual frenectomy with soft tissue diode laser for all the 3 cases in similar fashion.

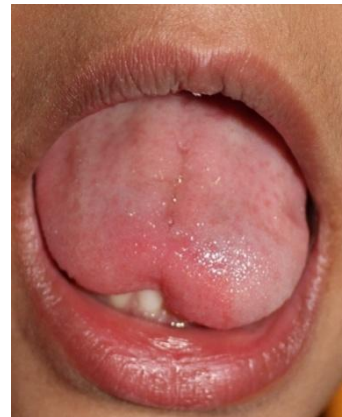Local infiltration was given bilateral to lingual frenum. Substance as well as tip of tongue was also anesthetised. A silk suture was passed as traction suture at tip of the tongue (Figure 3) for ease in tongue retraction.

The procedure of frenectomy was carried out by soft tissue diode laser using wavelength of 810 nm. Laser tip was activated onto a carbon paper at 2 W. Continuous mode was used for activation. The tissue excision was done with 2 W power supply in contact mode (Figure 4). Frenectomy started from the apex of lingual frenum to the base by using brush stroke. Fumes formed were carefully suctioned using high vacuum suction. Post-operative instructions and maintenance care tips were shared with the patient. Post-operative medications including antibiotics and analgesics were prescribed. Patient was recalled at 3 and 6 weeks. Healing was complete at 6 months (Figure 7 & 8).

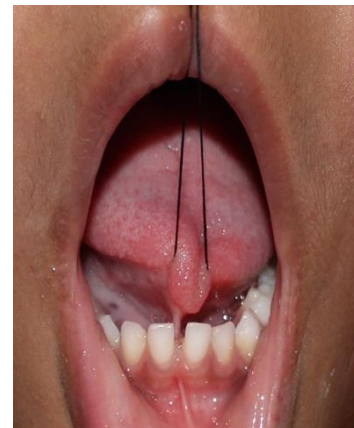Mobility of tongue increased significantly (Figure 8) along with improvement of speech. Patient was advised to undergo speech therapy for better speech articulation.




**Fig 1** - Case 1 Attachment of lingual frenum at tip of tongue



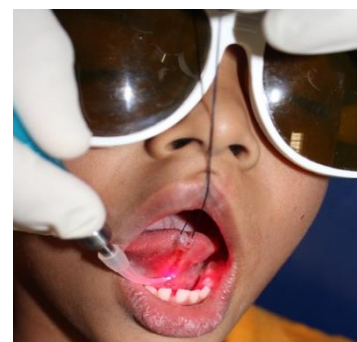
**Fig 2** – Restriction of tongue movement



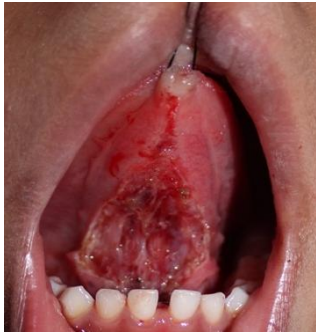**Fig 3** – Traction suture through tip of tongue



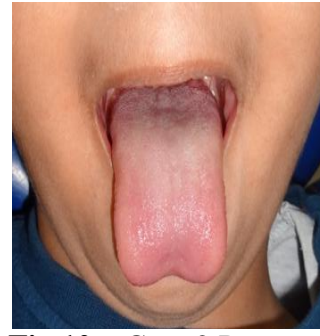**Fig 4** – Syneron Er: YAG Laser system



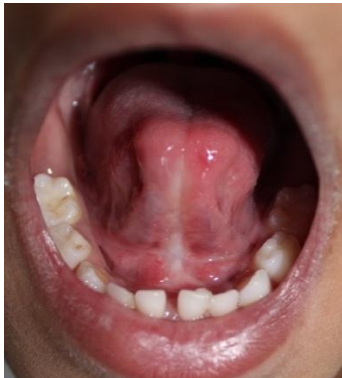**Fig 5** – Use of diode laser



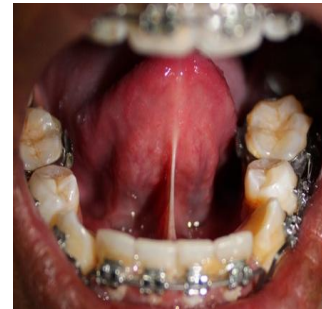**Fig 6** – Tissue after use at 810 nm wavelength of laser



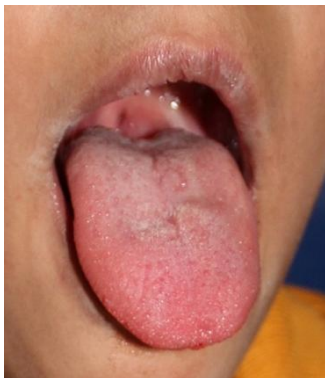**Fig 10** – Case 2 Post-op



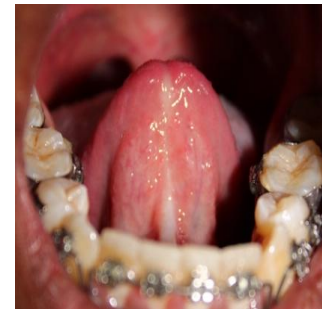**Fig 7** – Post op 6 months



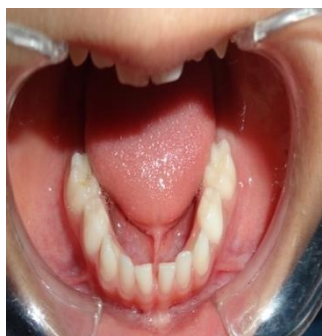**Fig 11** – Case 3 Pre-op



**Fig 8** – Range of tongue movement at 6 months



**Fig 12** – Case 3 Post-op



**Fig 9** – Case 2 – Pre-op

**Discussion**

Treatment of ankyloglossia includes a typical interdisciplinary approach including periodontists, pedodontists, maxillofacial surgeons to speech therapist. It can be observed at any age and an early treatment is recommended. Exact etiology of ankyloglossia is still not known<sup>(5)</sup>.

**Ankyloglossia can be classified according to Kowtow’s assessment as under depending on tongue movement<sup>(6)</sup> (Table 1)**

**Kowtow’s Assessment for ankyloglossia depending on tongue movement<sup>(6)</sup>**

1	Clinically acceptable	>16 mm
2	Class I	12 - 16 mm
3	Class II	8 - 11 mm
4	Class III	3 - 7 mm
5	Class IV	<3 mm (7)

Range of tongue movement can be checked under following criteria (Table 2):

1	Tongue tip should be able to move outside the oral cavity
2	Tongue tip should be able to touch the upper and lower lips easily; with no strain
3	On retrusion, there should not be any blanching
4	There should not be any tendency to create a midline diastema in mandibular teeth

The associated problems with limitation of tongue movement are problem in breast feeding in newly born, occlusion disturbance, periodontal problem and speech difficulty with consonants like I, n, t, and d, and difficult to roll tongue. Hence, treatment of ankyloglossia should be carried out as soon as it is detected.

Various treatment options include conventional scalpel technique (frenotomy, frenectomy, frenuloplasty) and lasers. Various shortcomings of conventional surgical frenectomies are increased intra operative bleeding, retention cyst, damage to lingual nerve leading to tongue tip numbness.

Lasers has many advantages as compared to scalpel. Laser results in less intraoperative bleeding, less patient discomfort and more predictable results, reduced post-operative edema and bleeding<sup>(8)</sup>. In all three cases treated with soft tissue lasers had complete healing with significant increase in tongue movement and better speech with reduced intraoperative bleeding, pain, better visibility during surgery

### Conclusion

Ankyloglossia is one of the most commonly encountered condition which can lead to various problems starting from difficulty in feeding to speech disorders. Soft tissue diode Laser assisted therapy is relatively simple and safe with promising clinical outcome.

### References

1. Northcutt ME. The lingual frenum. *J Clin Orthod.* 2009;43:557–65.
2. Wallace AF. Tongue tie. *Lancet.* 1963; 2:377–8.
3. García Pola MJ, González García M, García Martín JM, Gallas M, SeoaneLestón J. A

study of pathology associated with short lingual frenum. *ASDC J Dent Child.* 2002;69:59–62.

4. Ballard JL, Auer CE, Khoury JC. Ankyloglossia: Assessment, incidence, and effect of frenuloplasty on the breastfeeding dyad. *Pediatrics.* 2002;110:e63.
5. Acevedo AC, da Fonseca JA, Grinham J, Doudney K, Gomes RR, de Paula LM, et al. Autosomal-dominant ankyloglossia and tooth number anomalies. *J Dent Res.* 2010;89:128–32.
6. Kotlow LA. Ankyloglossia (tongue-tie): A diagnostic and treatment quandary. *Quintessence Int.* 1999;30:259–62.
7. Lalakea ML, Messner AH. Ankyloglossia: The adolescent and adult perspective. *Otolaryngol Head Neck Surg.* 2003;128:746–52.
8. Pirnat S. Versality of an 810 nm diode laser in dentistry: An overview. *J Laser Health Acad.* 2007;4:1–9.
9. Zeinoun T, Nammour S, Dourov N, Aftimos G, Luomanen M. Myofibroblasts in healing laser excision wounds. *Lasers Surg Med.* 2001;28:74–9.
10. Haytac MC, Ozcelik O. Evaluation of patient perceptions after frenectomy operations: A comparison of carbon dioxide laser and scalpel techniques. *J Periodontol.* 2006;77:1815–9.