



Uterine Adenomatoid Tumor –A Rare Case, Masquerading As Leiomyoma

Authors

Dr Anchana Gulati, Dr Shalini Kapoor*, Dr Ankita, Dr Sudarshan K Sharma

Department of Pathology, IGMC, Shimla

*Corresponding Author

Dr Shalini Kapoor

Deptt. of Pathology, IGMC, Shimla, India

Abstract

Adenomatoid tumor encountered most often in the male and female genital tracts is a benign neoplasm of mesothelial origin. We report a case of adenomatoid tumour of the uterus in a patient with abnormal uterine bleeding who underwent hysterectomy with a diagnosis of fibroid and which is difficult to recognize on morphology.

Introduction

Adenomatoid tumor is an uncommon slow growing tumor of mesothelial origin which is cured by surgical excision. It has been reported to occur in a variety of extra genital sites including the heart, intestinal mesentery, pleura, peritoneum and adrenal gland. The tumors may be present in up to 1% of hysterectomy specimens.² CT and MR findings of these tumors simulate the findings of uterine leiomyoma and preoperative diagnosis is difficult³. Macroscopically and microscopically it can pose diagnostic difficulty and can even be mistakenly labeled as malignant. We present this case as it gives an insight into the histomorphological findings of this tumor which is exceedingly rare.

Case Report

51 year old patient visited gynaecology department with complaint of excessive bleeding. Total hysterectomy specimen was received in pathology department. On gross examination, It

measured 7 x 3 x 2 cm and. Also received a bisected soft tissue mass 6 cm in diameter? fibroid arising from posterior surface of uterus. Cut section was grey yellow, homogenous, devoid of whorling pattern. Fig1

Cervix, bilateral fallopian tubes and ovary are unremarkable. On cut section myometrium measures 2 cm and endometrium measures 1-2 mm.

Haematoxylin and eosin stained smears of sections from sub serosal mass revealed: circumscribed lesion comprised of dilated gland like spaces lined by flattened to focally cuboidal mesothelial like cells surrounded by nests of epithelial like cells having central to eccentric bland nuclei with fine chromatin inconspicuous nucleoli and moderate amount of eosinophilic vacuolated cytoplasm with focal signet ring appearance.

Stroma reveals scattered lymphocytes, focally present smooth muscle bundles and lymphoid follicles at the periphery along with foci of

xanthoma/foamy histiocytes and occasional psammoma bodies. Fig 2

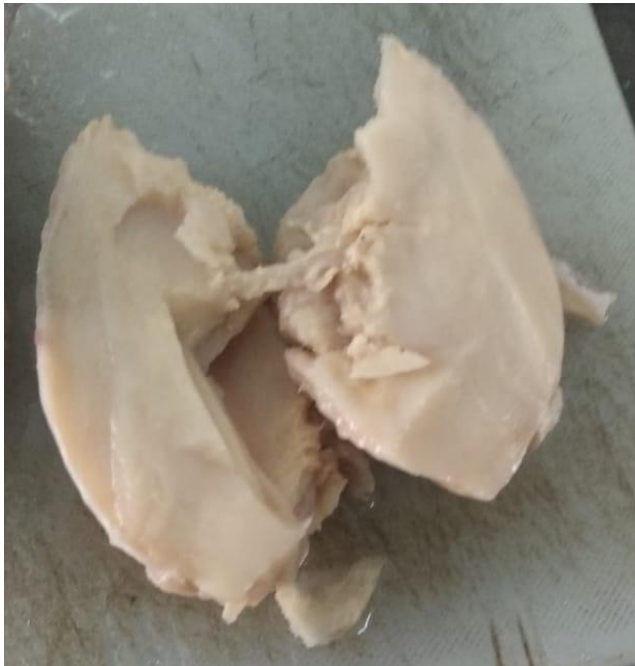

Fig. 1 Gross: Soft tissue mass, grey yellow, homogenous, devoid of whorling pattern

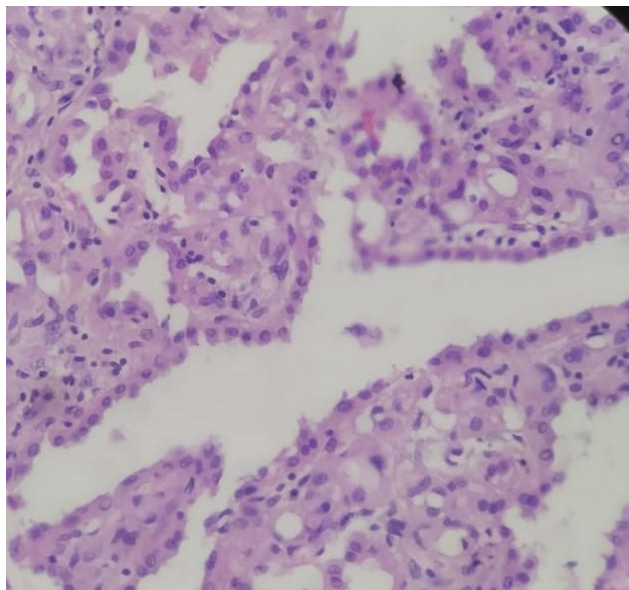


Fig 2: Dilated gland like space lined by flattened to focally cuboidal cells surrounded by nests of epithelial like cells, few cells with focal signet ring appearance

Discussion

Adenomatoid tumor is a relatively uncommon benign neoplasm of mesothelial origin, usually occurring in the male and female genital tracts.

Macroscopically they are usually nodular tan gray resembling a leiomyoma.⁴

Our case showed grossly grey yellow, homogenous mass on cut section, devoid of whorling pattern. Grossly possibility of epitheloid leiomyoma was kept.

Histological appearances are varied with adenoid, angiomatoid, cystic, glandular, solid and tubular patterns. Rare morphologic patterns include oncocytic and reactive ischemia.⁴

Due to the many architectural variations, AT has an extensive differential diagnosis that includes hemangioma, angiosarcoma, lymphangioma, malignant, mesothelioma, yolk sac tumor, and primary as well as metastatic adenocarcinoma. The smooth muscle may predominate such that the tumor appears at first glance to be a leiomyoma or lipoleiomyoma. The cuboidal epithelial cells have cytologically bland, eccentric, round nuclei and abundant pale cytoplasm. The cytoplasm is often vacuolated, sometimes to the extent that some tumor cells resemble signet-ring cells. The growth of the epithelial cells between smooth muscle bundles and the presence of signet-ring-like cells raise the suspicion of metastatic adenocarcinoma.

As tumor cells have clear to eosinophilic vacuolated cytoplasm, possibility of pecoma was also considered. Signet ring cell presence pointed towards adenocarcinoma.

To conclude, this case report gives an insight into the histomorphological findings of this tumor which is exceedingly rare and often overlooked because of its low incidence, lack of awareness and common differentials. The key to an accurate diagnosis is careful observation of findings on routine light microscopy supported by special stains and sometimes immunohistochemical stains.

References

1. Isotalo PA, Keeney GL, Sebo TJ et al. Adenomatoid tumor of the adrenal gland: a clinicopathologic study of five cases and

review of the literature. Am J Surg Pathol, 2003; 27:969-77.

2. Csermi G, Kocsis L, Pusztai Z et al. Endometrial adenocarcinoma with coexisting adenomatoid tumor of the uterus. Gynecol Oncol, 2003;90:207-10.
3. Kim JY, Jung K, Sung NK et al. Cystic adenomatoid tumor of the uterus. Am J Roentgenol 2002;179:1068-70
4. Sangoi AR, McKenney JK, Schwartz EJ, Rouse RV, Longacre TA. Adenomatoid tumors of the female and male genital tracts: a clinicopathological and immunohistochemical study of 44 cases. Mod Pathol. 2009;22(9):1228-35.