



A case of scorpion sting with cardiac manifestations

Authors

Dr Brunda M S^{1*}, Dr S N Padmini², Dr Tanzeem S³, Dr Treesa M D⁴

Department of General Medicine, Aster CMI Hospital, No. 43/2, New Airport Road, NH 44, Sahakar Nagar, Hebbal, Bengaluru, Karnataka 560092.

*Correspondence Author

Dr Brunda M S

Department of General Medicine, Aster CMI Hospital, No. 43/2, New Airport Road, NH 44, Sahakar Nagar, Hebbal, Bengaluru, Karnataka 560092, India

Abstract

Scorpion sting is common in many regions of India and can be a life threatening emergency, sometimes with serious clinical sequelae. We report a case of a 35 year old farmer who presented with scorpion sting to the emergency department initially with only local symptoms at the bite site but eventually developed sudden electrocardiographic changes, elevation of cardiac enzymes and echocardiographic abnormalities simulating early myocardial infarction. The patient was successfully treated in the intensive care unit with vasopressors, oxygen supplementation. The patient improved, repeat echocardiography was normal and was discharged 3 days later. Most scorpion envenomation result in local reaction, but some have systemic involvement that can be fatal. The importance of hospitalisation, intensive care treatment is emphasized.

Keywords: *scorpion sting, myocardial infarction.*

Introduction

Nearly 1500 species of scorpions are known worldwide. Scorpion envenomation is common in our country. Scorpion bites have been frequently reported from Karnataka, Tamil Nadu, Andhra Pradesh, Saurashtra, Uttar Pradesh, Bihar, and Western Maharashtra. In villages it is a common health problem, individuals working in farms being at a higher risk. Among the 86 species found in India, *Mesobuthus tamulus* (Indian red scorpion) and *Heterometrus swammerdami* are of importance.^[1] The predominant clinical effect following the sting vary from species to species. The *Mesobuthus Tamulus*, the Indian red scorpion is the most lethal, cardiovascular effects being predominant and its envenomation is fatal without

timely intervention and appropriate treatment. The black scorpion *Palmanus Gravimanus* is less poisonous. The scorpion belonging to family *Buthidae* secretes neurotoxic venom that is toxic to human.

Scorpion sting causes a wide array of clinical symptoms ranging from severe local skin reactions to neurologic, respiratory and cardiovascular collapse. Most of the envenomation results in local reaction with pain, swelling, pruritus and burning sensation at the site of sting that can be treated with local analgesics. Systemic complications can ensue, some can even be fatal secondary to cardiac or respiratory failure.^[2] We report a case with clinical manifestations following a scorpion sting mimicking acute myocardial infarction.

Case Report

A 35 year old male patient presented with scorpion sting to the right ring finger while working in his farm. Patient had complaints of pain in the right finger extending to his elbow associated with swelling and itching of right hand. Patient was conscious afebrile, right hand was swollen, tender with mild discolouration of right ring finger. Within few hours of hospitalization patient developed chest pain radiating to left arm associated with sweating, vomiting and chills, 7-8hours after the scorpion sting patient developed sudden bradycardia and hypotension. ECG recording showed bradycardia with ectopics (figure 1), 2D Echocardiography revealed: posterolateral wall hypokinesia, mild mitral regurgitation, left ventricular ejection fraction 50%, troponin I level of 775.4 ng/l (normal:17-50ng/l) was elevated. Other blood tests done were as follows: haemoglobin 15g/dl, total leucocyte count 11600/cumm, platelet count 265000/cumm, serum creatinine 1.10mg/dl, urea 33.80mgdl, serum sodium 140mmol/l, serum potassium 4.93mmol/l, liver function test was normal. Patient was managed in the intensive care unit with oxygen supplementation, inotropes, intravenous fluids, antihistamine, steroids and regular blood pressure, vital monitoring. Patient was observed, as the blood pressure improved inotrope was tapered and stopped. Patient condition further improved over the next 2 days, the heart rate and blood pressure normalised, serial Troponin I showed a downward trend, repeat ECG recorded sinus rhythm, on repeat 2D Echocardiography no regional wall motion abnormality was noted, left ventricular ejection fraction was 55%. Patient was discharged, came for follow up a week later and was doing well.

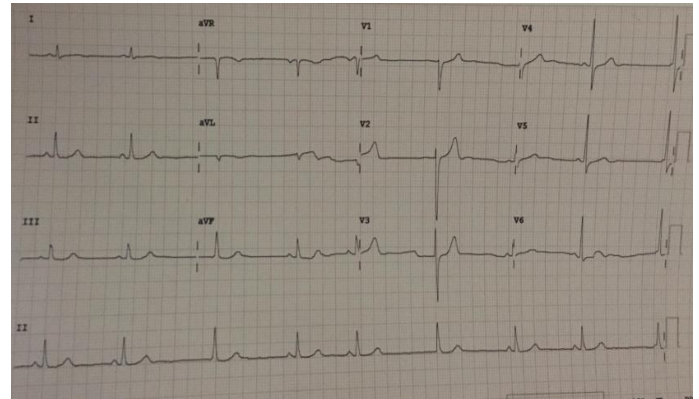


Figure 1 – Electrocardiogram (ECG) of the patient few hours after the scorpion bite showing bradycardia and junctional ectopics.

Discussion

Scorpions live in warm dry regions throughout India. They commonly inhabit the crevices of dwellings, underground burrows, under logs, sugarcane fields, paddy husk, and coconut, banana plantations. Scorpion stings are predominantly due to accidental contact. Scorpions use their stings only when stepped on or roughly handled. Scorpion stings are not always poisonous as it can control the venom ejaculation; thus the sting can be total, partial or non-existent.

Scorpion venoms are species-specific, they are a complex mixtures of cardiotoxin, short neurotoxic proteins (31-64 amino acid sequences), hematoxin, nephrotoxin, histamine, hyaluronidases and other chemicals. The side chains of scorpion venom being positively charged makes voltage-dependent ion channels the primary target for the venom.^[3,4]

Stimulation of alpha receptors by the toxin has a significant effect, resulting in tachycardia, hypertension, myocardial dysfunction, pulmonary oedema and cool extremities. The sudden autonomic nervous system stimulation, the outpouring of catecholamines may lead to accumulation of endo-thelins, vasoconstriction and stress induced cardiomyopathy.

The unopposed stimulation of alpha receptors lead to suppression of insulin secretion, hyperglycemia, hyperkalemia, free fatty acids and free radicals accumulation which is injurious to myocardium. The cardiovascular manifestations are par-

ticularly prominent in cases following Indian red scorpion stings, they infrequently have serious clinical sequelae such as myocardial infarction, cardiogenic shock, acute pulmonary edema and even death.^[5] Bahloul et al. examined the histopathology of two cases of fatal myocarditis resulting from a scorpion sting, mixed features of toxic myocarditis and coagulative myocytolysis, similar to catecholamine-induced cardiomyopathy was observed.^[6]

There are a wide range of ECG changes resulting from scorpion stings that may be recorded at admission or many hours later. Earliest recorded findings are sinus tachycardia. However, some percentage of patients may have bradycardia, rhythm disturbances^[7]. Echocardiography changes could include reduced left ventricular function, enlarged left ventricle and changes in end diastolic volume (EDV), reduced end systolic volume (ESV) and reduced ejection fraction (EF)^[8]. Agarwal et al reported a case of scorpion bite with symptoms, ECG and echocardiographic changes with elevated cardiac enzymes, features mimicking acute myocardial infarction. Coronary vasospasm being a possible precipitating factor in such cases.^[9]

Abdi A et al. studied the ECG and echocardiography changes in 43 cases of scorpion sting, 30.2% of them had abnormal ECGs. The most common ECG abnormality noted was PVC (13.9%) and others changes were ST depression (9.3%), T-inversion (4.6%), Atrial fibrillation (4.6%), U-wave (2.3%) and sinus arrhythmia (2.3%), 11.6% with sinus tachycardia and one case of sinus bradycardia. There is no case of atrial-ventricular blocks.^[10] Our patient presented with local symptoms and signs, but suddenly developed clinical symptoms mimicking acute myocardial infarction with ECG and echocardiography changes and elevation of troponin I. Cardiovascular involvement is a cause of significant morbidity in scorpion sting. High index of suspicion and intensive care management with serial cardiac monitoring is important.

References

1. Erfati P. Epidemiology, symptomatology and treatment of buthinae stings. In: Bettini S, editor. Arthropod Venoms: Hand book of experimental Pharmacology. New York: Spring Verlag; 1978; 312–5.
2. Bawaskar HS, Bawaskar PH. Scorpion sting. J Assoc Physicians India. 1998; 46:388–92.
3. Zlotkin E, Miranda F, Lissitszky S. Proteins in scorpion venoms toxic to mammals and insects. Toxicon 1972; 10: 207-9.
4. Bawaskar HS, Bawaskar PH. Scorpion sting. J Assoc Physicians India. 2001; 46:388–92.
5. Bawaskar HS, Bawaskar PH. Indian red scorpion envenoming. Indian J Pediatr. 1998;65:383–91.
6. Bahloul M, Kallel H, Rekik N, Ben Hamida C, Chelly H, Bouaziz M. Cardiovascular dysfunction following severe scorpion envenomation. Mechanisms and pathophysiology. Presse Med. 2005; 34:115–20.
7. Alan S, Ulgen MS, Soker M, Geyik F, Karabulut A, Toprak N. Electrocardiologic and echocardiographic features of patients exposed to scorpion bite. Angiology. 2004;55(1):79–84.
8. Kumar EB, Soomro RS, al Hamdani A, el Shimy N. Scorpion venom cardiomyopathy. Am Heart J. 1992;123 (3):725–9.
9. Agrawal, A., Kumar, A., Consul, S., & Yadav, A. (2015). Scorpion bite, a sting to the heart! Indian journal of critical care medicine: peer-reviewed, official publication of Indian Society of Critical Care Medicine, 19(4), 233-6.
10. Abdi A, Farshidi H, Rahimi S, Amini A, Tasnim Eftekhari SF. Electrocardiologic and Echocardiographic Findings in Patients With Scorpion Sting. Iran Red Cres Med J.2013;15(5):446-7. DOI: 10.5812/ircmj.2853.