



Original Research Article

A Study of the Efficacy of Microneedling with Topical Autologous Platelet Rich Plasma in the Treatment of Acne Scars in a Tertiary Care Centre

Authors

Priyadharsini R¹, Kaviarasan PK², Prasad PVS³, Kannambal K^{4*}, Poorana B⁵
Abhirami C⁶

¹Post Graduate, Department of Dermatology Venereology and Leprosy, Rajah Muthiah Medical College & Hospital, Annamalai University, Chidambaram, India – 608002.

²Head of the Department, Department of Dermatology Venereology and Leprosy, Rajah Muthiah Medical College & Hospital, Annamalai University, Chidambaram, India – 608002.

³Professor, Department of Dermatology Venereology and Leprosy, Rajah Muthiah Medical College & Hospital, Annamalai University, Chidambaram, India – 608002.

⁴Associate professor, Department of Dermatology Venereology and Leprosy, Rajah Muthiah Medical College & Hospital, Annamalai University, Chidambaram, India – 608002

⁵Assistant professor, Department of Dermatology Venereology and Leprosy, Rajah Muthiah Medical College & Hospital, Annamalai University, Chidambaram, India – 608002

⁶Lecturer, Department of Dermatology Venereology and Leprosy, Rajah Muthiah Medical College & Hospital, Annamalai University, Chidambaram, India – 608002

*Corresponding Author

Kannambal K

Abstract

Background: Acne scars poses a significant psychosocial morbidity in this era of aesthetic concern. Acne scars can be classified into three types—atrophic, hypertrophic & keloidal. Atrophic acne scars are the most common type. Many treatments are available for treating post acne scars. Platelet-rich plasma (PRP) may be useful in atrophic scars by promoting collagen deposition. Microneedling also releases growth factors, which initiates a cascade of wound healing resulting in collagen deposition. Hence, microneedling and PRP should act synergistically to improve acne scars.

Objective: To assess the efficacy of microneedling with topical autologous platelet rich plasma in the treatment of acne scars.

Material and Methods: The study enrolled 20 cases of acne scars. Microneedling with topical PRP was applied over acne scars. They received 4 sequential treatments with an interval of 4 weeks between each session. At first visit, scars were graded according to Goodman and Baron's qualitative acne scar grading system. After 4 sessions objective assessment of physician scores of improvement were determined by Goodman and Baron's qualitative & quantitative acne scar grading system.

Results: Male female ratio was 0.43:1. After completion of 4 sessions, qualitative assessment revealed reduction by 3 grades in 12 patients (60%) and Quantitative assessment showed 8 patients (40%) with very good reduction. Photographs were taken at each visit and compared.

Conclusion: Microneedling with topical PRP was safe, superior and efficacious in treating acne scars.

Keywords: Acne scars, Platelet Rich Plasma, microneedling, Goodman and Baron's qualitative and quantitative acne scar grading system.

Introduction

Acne vulgaris is one of the most common skin disease affecting more than 90% of adolescents and adults with scarring being commonest sequelae.¹ Severe acne results not only permanent scarring but also significant physical and psychosocial morbidity, especially in adolescents. This ultimately results in diminished quality of life.² Scarring usually occurs as a consequence of healing of active acne.

Acne scars can be categorized clinically into three types based on whether there is net loss or gain of collagen as atrophic, hypertrophic and keloidal.³ Jacob et al classified atrophic acne scars into ice pick scars, rolling scars and boxcar scars based on the parameters of width, depth and three dimensional architecture.⁴ The prevalence of ice pick scar is 60%-70%, box car scar 20%-30% and rolling scar 15%-25%.

In the modern era, the management of acne scars is meteoric ranging from subcision, dermabrasion, chemical peeling, tissue augmentation using fillers, ablative and non ablative laser techniques. Though these techniques resulted in varying degrees of success, they have their own consequences and resultant adverse effects. Therefore there is a true demand for newer novel therapeutic modalities that are more efficacious, safe with minimal downtime. In this regard, a recently developed minimally invasive novel technique is autologous platelet rich plasma (PRP) especially in the treatment of atrophic acne scars.

Role of PRP & Microneedling in acne scars

Platelet rich plasma is blood plasma with concentrated platelets. The concentrated platelets contain large reservoir of growth factors, especially epidermal growth factor (EGF), platelet derived growth factor (PDGF), transforming growth factor β (TGF- β), vascular endothelial growth factor (VEGF) which initiates cellular growth, morphogenesis and accelerates the natural healing process.⁵

Microneedling is performed with a derma roller which is a drum-shaped roller with 192 fine micro needles in eight rows, 0.5 – 1.5 mm in

length and 0.1mm in diameter. The microneedles are synthesized by reactive ion etching technique on silicon or medical grade stainless steel. The needles pierce the stratum corneum and create microconduits (holes) without damaging the epidermis.⁶

Hence, combining microneedling with platelet rich plasma has led to substantial improvement of acne scars with good aesthetic results and skin rejuvenation. This study is aimed to assess the efficacy of microneedling with topical autologous platelet rich plasma in the improvement of facial acne scars.

Materials & Methods

The study was conducted in the Department of Dermatology, Venereology and Leprosy, Rajah Muthiah Medical College from November 2017 to September 2019. Ethical clearance was sought from the institutional ethical committee. Patients in the age group of 18-40 years with atrophic acne scars were selected. Exclusion criteria were patients with active acne, history of keloidal scars, bleeding disorders, active skin infection like warts, herpes and bacterial infection.

A total of twenty patients with acne scars were selected on the basis of inclusion and exclusion criteria. A written informed consent was taken from all the patients before enrolling them in the study. A detailed history of the patients as per the prepared questionnaire was taken along with photographs of each patient. Acne scars were classified according to Goodman and Baron's qualitative acne scar grading system as shown in table 1 and the results were assessed using Goodman and Baron's qualitative and quantitative acne scar grading system as shown in table 2a and 2b. Data obtained were tabulated in Microsoft office excel 2007. Descriptive statistics like mean and percentage were used to infer results.

Autologous platelet rich plasma preparation and method of administration

Autologous platelet rich plasma was obtained by a two stage centrifuging process. 10 ml of patient's whole blood sample was drawn from the median

cubital vein and collected in four sterile tubes each containing 1ml anticoagulant (Sodium citrate). The tubes were centrifuged at 1500 revolutions per minute for 10 minutes in the centrifugal machine. At the end of first spin, three layers were formed. The bottom layer consists of RBCs, the middle layer consists of platelets and WBCs and the top platelet-poor plasma layer. Only the supernatant plasma containing platelets were transferred into another sterile tube without anticoagulant. This tube was subjected to a second spin at 3000 revolutions per minute for 20 minutes to obtain a platelet concentrate. After the second spin, approximately ¾ the of the supernatant will be discarded and platelet rich pellet will be resuspended in remaining amount of plasma. 10% calcium chloride will be added as platelet activator (1:9) i.e., 1ml of calcium chloride in 9 ml of PRP. PRP will be thus obtained. Facial skin was disinfected with alcohol swab, then a topical anaesthetic cream was applied, left

for 30 minutes. The skin was stretched and microneedling was carried out in vertical, horizontal and both diagonal directions for about 4- 5 times and platelet rich plasma was smeared over the area. Ice packs was applied over the treated area. Patients were advised to apply broad spectrum sunscreen, emollients and to avoid sun exposure.

Clinical evaluation

At initial visit (week 0) facial acne scars were graded based on Goodman and Baron's qualitative acne scar grading system. Objective assessment of Physician scores of improvement were determined by Goodman and Baron's qualitative and quantitative acne scar grading system by a side by side comparison of pre-operative and post-operative photographs taken at every sessions and at the end of 1 month after the last session.

Table1: Qualitative grading and examples of acne scars by Goodman and Baron⁷

Grade	Level of disease	Characteristics	Examples of scars
1	Macular disease	Erythematous, hyper or hypopigmented flat marks visible to patient or observer irrespective of distance.	Erythematous, hyper- or hypopigmented flat marks
2	Mild disease	Mild atrophy or hypertrophy that may not be obvious at social distances of 50cm or greater and may be covered adequately by makeup or the normal shadow of shaved beard hair in males or normal body hair if extrafacial.	Mild rolling, small soft papular
3	Moderate disease	Moderate atrophic or hypertrophic scarring that is obvious at social distances of 50cm or greater and is not covered easily by makeup or the normal shadow of shaved beard hair but is still able to be flattened by manual stretching of the skin	More significant rolling, shallow "boxscar", mild to moderate hypertrophic or papular scars.
4	Severe disease	Severe atrophic or hypertrophic scarring that is obvious at social distances of 50cm or greater and is not covered easily by make-up or the normal shadow of shaved beard hair in males or body hair (if extrafacial) and is not able to be flattened by manual stretching of the skin	Punched out atrophic (deep box scar), ice pick, bridges and tunnels, gross atrophy, dystrophic scars significant hypertrophy or keloid.

Table 2a: Quantitative grading of acne scars by Goodman and Baron⁸

Grade or type	Number of lesions 1 (1-10)	Number of lesions 2 (11-20)	Number of lesions 3 (>20)
Milder scarring (1 point each)	1 point	2 points	3 points
Macular erythematous pigmented			
Mildly atrophic dish-like			
Moderate scarring (2 points each)	2 points	4 points	6 points
Moderately atrophic, dish like			
Punched out with shallow bases small scars (<5mm)			
Shallow but broad atrophic areas			

Severe scarring (3 points each)	3 points	6 points	9 points
Punched out with deep but normal bases, small scars (<5mm)			
Punched out with deep but abnormal bases, small scars (<5mm)			
Linear or troughed dermal scarring			
Deep, broad atrophic areas			
Hyperplastic	2 points	4 points	6 points
Papular scars	Area<5mm ²	Area 5-20mm ²	Area>20cm ²
Keloidal/Hypertrophic scars	6 points	12 points	18 points

Table 2b: Assessment of improvement using Goodman and Baron’s quantitative acne scar grading system

Grades	Improvement status
0-5	Minimal reduction in GSGS scores
5-10	Moderate reduction in GSGS scores
10-15	Good reduction in GSGS scores
>15	Very good reduction in GSGS scores

Figure 1: Microneedling with PRP

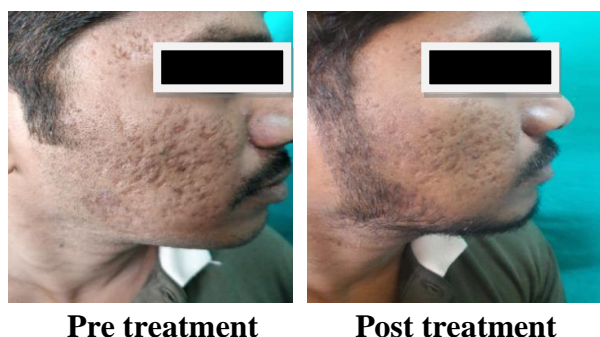
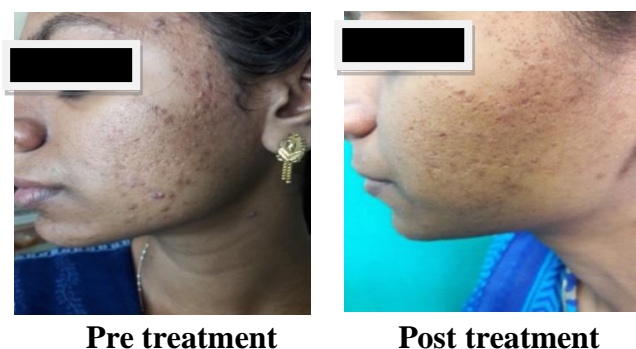


Figure 2: Microneedling with PRP



Results

The mean age of the patients was 25.4 years with the minimum age being 18 years and the maximum age being 35 years. Male: female ratio was 0.43:1. Acne scar duration varied from less than 1 year to more than 10 years. Majority of the patients 60% (n=12) gave history of scar duration of 1- 5 years, followed by 25% (n=5) with acne scar duration of 6-10 years, 10% (n=2) with duration of less than or equal to 1 year and 5% (n=1) with acne scar duration of more than 10 years. According to

Goodman and Baron acne scar grading scale, 10 patients presented with grade III (moderate) and 10 patients with grade IV (severe) on both sides of the face.

At the end of one month after last session (4 sessions), qualitative assessment showed out of 10 patients with grade 3 acne scars, 7 patients (35%) showed reduction by 2 grades and 3 patients (15%) by 1 grade. Out of 10 patients with grade 4 acne scars, 5 patients (25%) showed reduction by 3 grades, 3 patients (15%) by 2

grades and 2 patients (10%) by 1 grade as shown in figure 3. Quantitative assessment showed 8 patients (40%) with very good improvement, 6 patients (30%) with good improvement, 4

patients (20%) with moderate and 2 patients (10%) with minimal improvement as shown in figure 4.

Figure 3: Qualitative assessment of acne scars

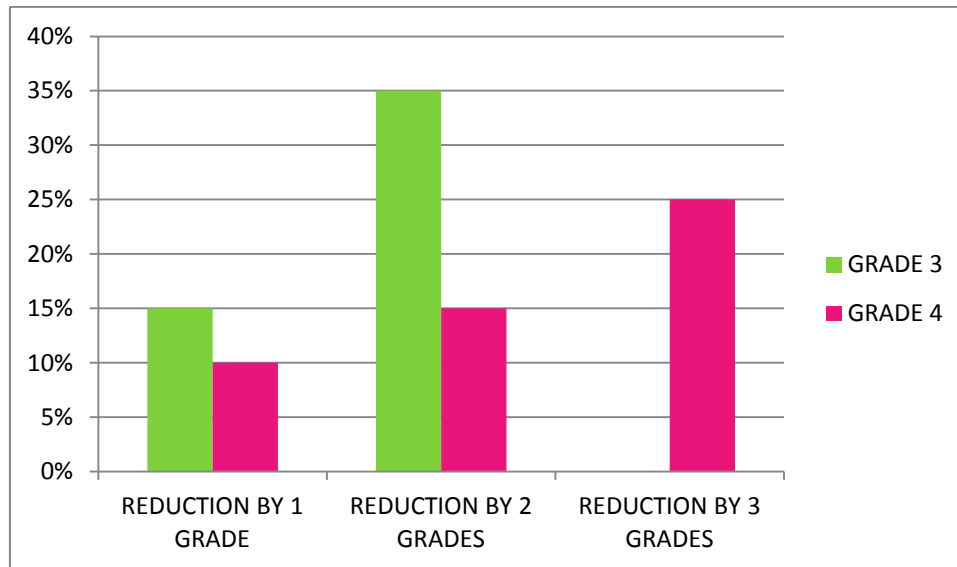
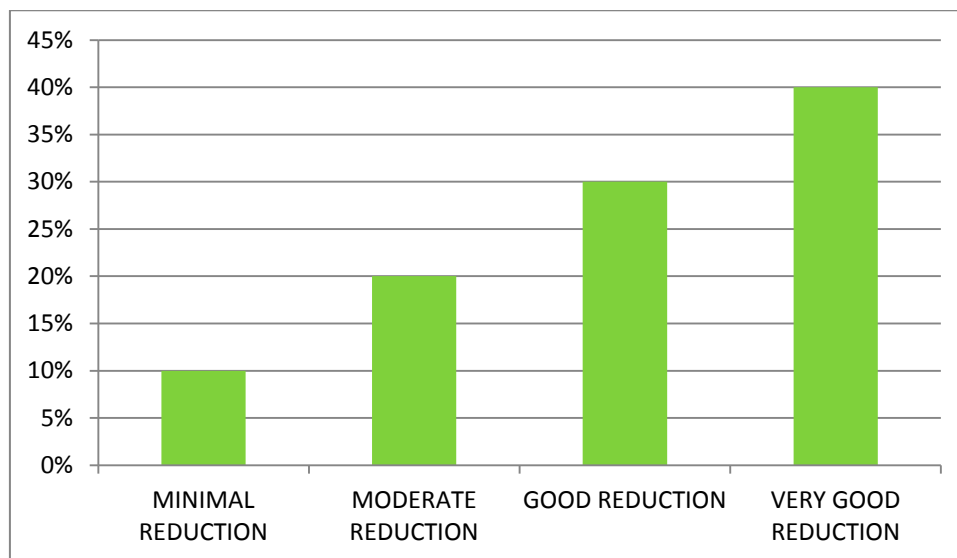


Figure 4: Quantitative assessment of acne scars



Discussion

Acne causes not only facial scarring but also it leads to significant psychosocial implications and emotional distress more so in adolescents. Various modalities have been used to treat scars, but limited efficacy and problematic side effects have restricted their application. PRP effectiveness in wound healing has prompted its use in the treatment of depressed facial scars, along with other available treatment modalities.

The possible mechanism of PRP in the reconstruction of a depressed scar is the induction of growth factors important in tissue remodeling, which promote connective tissue healing by up regulating collagen and protein synthesis.⁹ Growth factors present in PRP promotes & accelerates tissue remodelling with the increased synthesis of collagen.¹⁰ So, PRP holds a promising role in soft tissue augmentation.

Skin needling also called collagen induction therapy¹¹ or needle dermabrasion is the technique of rolling a device comprising a barrel studded with hundreds of needles, which creates thousands of micropunctures in the skin to the level of papillary to mid-dermis. With this technique, the microneedling is usually continued until pinpoint bleeding point occurs, which initiates the complex cascade of growth factors that finally results in collagen production.¹² Also it provides a clear conduit for agents to be absorbed more effectively through the upper layer of skin.

In our study, a statistically significant improvement was noted by combining PRP with microneedling. This finding could be attributed to the synergistic effects of both modalities on all types of atrophic acne scars. None of our patients showed any permanent pigmentary or textural changes. The only side effects noticed were redness and swelling of treated areas after each session of treatment, which subsided in 2 to 3 days.

Limitation of the study

The limitations of our study are small sample size, time constraint and long term follow – up of patients.

Conclusion

In conclusion, our study offers different, effective and safe therapeutic option for the treatment of atrophic acne scars. Combining microneedling with topically smeared platelet rich plasma is more effective in improving the quality of acne scars significantly. There were no significant side effects observed in this study. Three or four sessions of combination treatments are required for patients with moderate to severe acne scars. This technique is less expensive and is most likely useful in areas where there is limited access to laser technology. Further continuation of treatment might help to achieve a better outcome as scars only modify but never disappear completely.

References

1. Ranjan S, Gupta R, Gupta S. A Study of the Efficacy of Skin Needling and Platelet Rich Plasma in the Treatment of Acne Scars. *Nepal J Dermatol Venereol Leprol* 2017; 15:17-23.
2. Shah S, Mehta B, Borkar M, Aswani R. Study of safety and efficacy of autologous platelet rich plasma combined with fractional CO2 laser in the treatment of post acne scars: a comparative simultaneous split-face study. *Int J Res Med Sci* 2017;5(4):1344-1351.
3. Kravvas G, Al-Niimi F. A systematic review of treatments for acne scarring. Part 1: Non-energy-based techniques. *Scars Burn Heal*. 2017;3:1-17.
4. Jacob CI, Dover JS, Kaminer MS. Acne scarring: A Classification system and review of treatment options. *J Am Acad Dermatol* 2001;45(1):109-117.
5. Dohan Ehrenfest DM, Rasmusson L, Albrektsson T. *Trends Biotechnol*. 2009 Mar;27(3):158-67.
6. Doddaballapur S. Microneedling with dermaroller. *J Cutan Aesthet Surg* 2009; 2(2):110–111.
7. Goodman GJ, Baron JA. Post acne scarring: A qualitative global scarring grading system. *Dermatol Surg* 2006; 32:1458-66.
8. Goodman GJ, Baron JA. Post acne scarring: A quantitative global scarring grading system. *J Cosmet Dermatol* 2006;5:48-52.
9. Ganio C, Tenewitz FE, Wilson RC, Moyles BG. The treatment of chronic nonhealing wounds using autologous platelet derived growth factors. *J Foot Anke Surg* 1993;32:263-268.
10. Lee JW, Kim BJ, Kim MN, Mun SK. The efficacy of autologous platelet rich plasma combined with ablative carbon dioxide fractional resurfacing for acne scars: a

simultaneous split-face trial. *Dermatol Surg* 2011; 37(7): 931-8.

11. Fife D. Practical evaluation and management of atrophic acne scars : tips for the general dermatologist. *J Clin Aesthet Dermatol*. 2011; 4: 50–57.
12. Fabbrocini G, Fardella N, Monfrecola A, et al. Acne scarring treatment using skin needling. *Clin Exp Dermatol*. 2009; 34: 874–879.