



## Barium contrast evaluation of lower esophageal sphincter disorders with endoscopic correlation

Authors

**Dr Ankit Bakshi<sup>1</sup>, Dr Birinder Nagi<sup>2</sup>, Dr Sohan Singh<sup>3</sup>, Dr Rupinder Singh<sup>4</sup>**

<sup>1</sup>Resident, Department of Radiodiagnosis and Imaging, M.M. Institute of Medical Sciences and Research, Mullana, Ambala

<sup>2</sup>Ex. Professor, Department of Radiodiagnosis and Imaging, M.M. Institute of Medical Sciences and Research, Mullana, Ambala

<sup>3</sup>Professor, Department of Radiodiagnosis and Imaging, M.M. Institute of Medical Sciences and Research, Mullana, Ambala

<sup>4</sup>Associate Professor, Department of Radiodiagnosis and Imaging, M.M. Institute of Medical Sciences and Research, Mullana, Ambala

Corresponding Author

**Dr Rupinder Singh**

Associate Professor, Department of Radiodiagnosis and Imaging, M.M. Institute of Medical Sciences and Research, Mullana, Ambala, India

Ph: 8059931477, Email: [rupsj@yahoo.com](mailto:rupsj@yahoo.com)

### Abstract

**Introduction:** Lower esophageal sphincter disorders include achalasia cardia, hiatus hernia, peptic stricture, growth gastro-esophageal junction, schkatzki ring, and esophagitis. Barium swallow is an accurate method in the evaluation of these disorders. It is a simple test and is being done since a long period of time.

### Aims and Objectives

1. To evaluate the role of barium examination in assessment of lower esophageal sphincter with related structural and functional abnormalities at this level.
2. To compare the findings of barium studies with endoscopic findings.

**Material and Method:** The present study was carried out in 50 patients who were referred for barium swallow with symptoms suggestive of esophageal disease.

Barium contrast examination with digital cine fluororadiography was performed in all the patients. The patients diagnosed with the lower esophageal disorder were referred for endoscopic examination and the results of both the investigations were correlated.

**Results:** Out of 50 cases, 60% were males and 40% were females. Subjects were in age ranging from 21 to 82 years. Mean age of patients was 49.7 years.

Our study found that patients of lower esophageal sphincter disorder presented most commonly with dysphagia as chief complain and the most common lower esophageal disorder was achalasia cardia followed by hiatus hernia.

In correlation with endoscopic examination most of the diagnosis of barium swallow examination were confirmed by endoscopy while 12% cases were found normal on endoscopy.

**Conclusion:** Barium swallow is a cost effective, rapid, imaging technique to detect lower esophageal sphincter disorders. In this study both the modalities were correlated and barium was found to be more dependable modality than endoscopy in the diagnosis of lower esophageal sphincter disorders.

## Introduction

Esophagus is connected to the stomach by the pharynx. Its measurement in length is 25 cm. It extends from the lower border of the cricoid cartilage to the left dome of diaphragm, here at this point it pierces the diaphragm and ends at the gastro esophageal junction<sup>1</sup>.

Lower esophageal sphincter disorders include achalasia cardia, hiatus hernia, peptic stricture, growth gastro-esophageal junction, schkatzki ring, and esophagitis. Radiology has a very important role in the evaluation of lower esophageal sphincter, gastro esophageal reflux and other structural and functional abnormalities related to LES. Barium esophagram plays an essential role in the assessment and management of patients with GERD and motility disorders. In patients showing reflux symptoms the purpose of barium studies is not only to document the presence of a hiatus hernia or gastro-esophageal reflux but also to detect the morphologic sequelae of reflux, including that of reflux esophagitis and peptic strictures<sup>2,3</sup>. Barium swallow is an accurate method in the evaluation of these disorders. It is a simple test and is being done since a long period of time. Biphasic examinations are performed in esophagus barium studies including erect double-contrast viewing of high-density barium suspension and also single contrast supine/prone viewing of low-density barium suspension<sup>4</sup>.

## Aims and Objectives

1. To evaluate the role of barium examination in assessment of lower esophageal sphincter with related structural and functional abnormalities at this level.
2. To compare the findings of barium studies with endoscopic findings.

## Material and Method

The present study was carried out in 50 patients who were referred for barium swallow with symptoms suggestive of esophageal disease. Barium contrast examination with digital cine

fluororadiography was performed in all the patients. The patients diagnosed with the lower esophageal disorder were referred for endoscopic examination and the results of both the investigations were correlated.

## Inclusion criteria

- Patient of either sex above the age of 18 yrs.
- Patient willing to give informed consent.

## Exclusion criteria

- Pregnant women.
- Any contraindication to endoscopy.

**Sample size:** Fifty patients with abnormalities related to lower esophageal sphincter formed the study group. Detailed clinical history of all the patients was taken. The barium examination was performed in overnight fasting state.

## Technique

Barium studies of the esophagus was performed on digital cine fluororadiography machine as biphasic examinations which included upright double-contrast views with a high-density barium and supine/prone single-contrast views with a low-density barium. Double contrast examination was performed using high density barium (200% w/v) 10-20 mgm. Anterior and lateral views were taken using cineradiography. This was followed by single contrast views in supine and prone oblique positions using low-density barium (40% w/v) to distend the esophagus to show lower esophageal sphincter, rings, strictures, or hiatus hernias and to evaluate esophageal motility simultaneously. Finally, the patient was turned around to look for gastroesophageal reflux. Digital cine fluoro radiography was done and images were stored.

Endoscopic examination of esophagus was done using (KARL STORZ) gastro duodenal endoscope. Endoscopic biopsies were taken if required. Endoscopic findings were correlated with barium findings.

Relevant statistical analysis was done for correlation of barium and endoscopic findings.

**Results**

Out of 50 cases, 60% were males and 40% were females. Subjects were in age ranging from 21 to 82 years. Mean age of patients was 49.7 years.

Our study found that patients of lower esophageal sphincter disorder presented most commonly with dysphagia as chief complain and the most common lower esophageal disorder was achalasia cardia followed by hiatus hernia.

**Table 1:** Incidence of Chief Complaints  
n=50

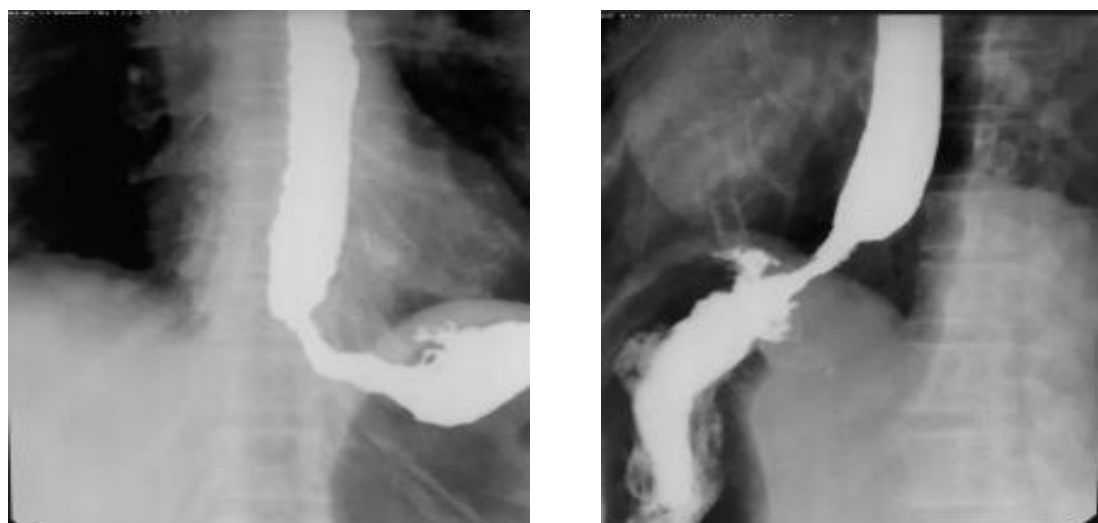
CHIEF COMPLAINTS	PRESENT	ABSENT	Percentage
DYSPHAGIA	42	8	84%
VOMITING	23	27	46%
LOSS OF APPETITE	29	21	58%
LOSS OF WEIGHT	12	38	24%
CHEST PAIN	29	21	58%
RETROSTERNAL BURNING	32	18	64%

In our study, Achalasia Cardia was found to be the most common lower esophageal sphincter disorder on barium swallow and endoscopy. It was found in 32% cases.

**Table 2:** Comparison of Differential Diagnosis on Barium Swallow and Endoscopy  
n=50

	BARIUM SWALLOW	PERCENTAGE	ENDOSCOPY	PERCENTAGE
ACHALASIA CARDIA	16	32%	16	32%
ESOPHAGITIS	2	4%	1	2%
SCHKATZKI RING	3	6%	1	2%
GROWTH GE JUNCTION	8	16%	8	16%
HIATUS HERNIA	15	30%	13	26%
PEPTIC STRICTURE	6	12%	5	10%
NORMAL STUDY	0	0%	6	12%

**Image 1:**



**AP and lateral view: showing growth in the region of lower esophageal sphincter**

Hiatus hernia found in 30% cases on barium swallow and 26% cases on endoscopy. However, 2 cases of hiatus hernia were missed on endoscopy.

Growth gastro-esophageal junction was found in 16% cases on both barium swallow and endoscopy.

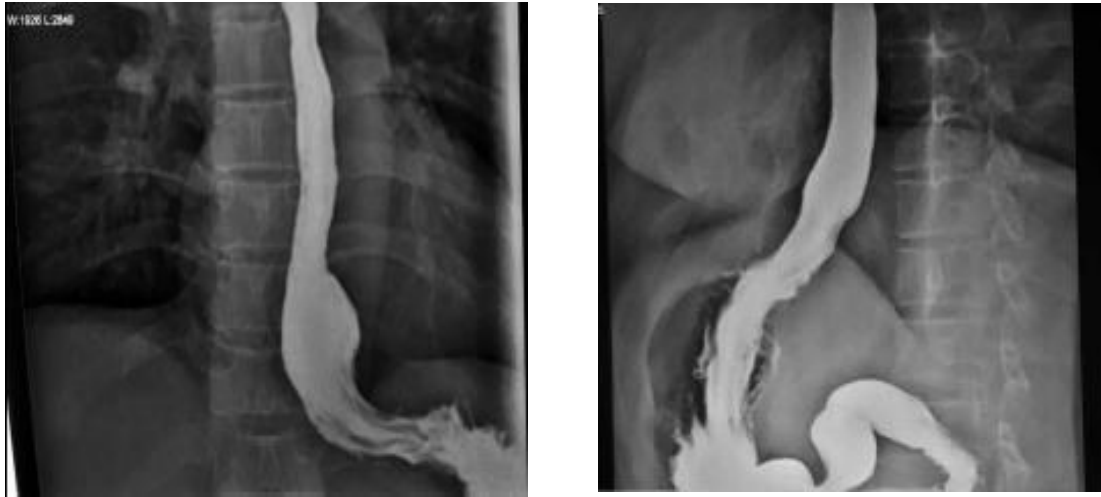
Peptic stricture was found in 12% cases on barium swallow and 10% cases on endoscopy. However, 1 case of peptic stricture was missed on endoscopy.

Schkatzki ring was found in 6% cases on barium swallow and 2% cases on endoscopy. However, 2 cases of schkatzki ring were missed on endoscopy.

Esophagitis was found in 4% cases on barium swallow and 2% cases on endoscopy. However, 1 case of esophagitis was missed on endoscopy.

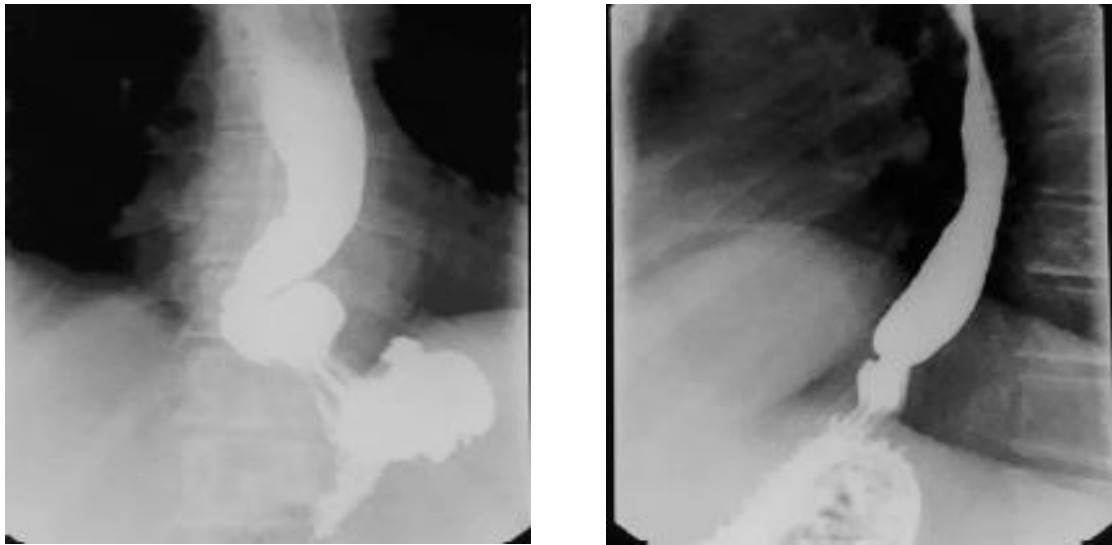
On endoscopy 12% cases were found to be normal which were diagnosed with various different pathologies on barium swallow.

**Image 2:**



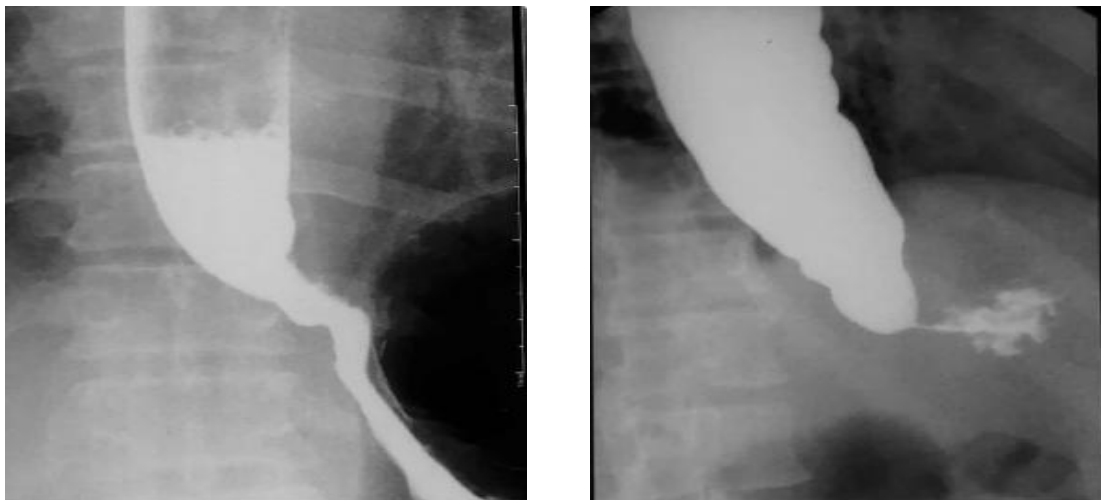
**AP and lateral view: showing esophagitis involving lower esophageal sphincter**

**Image 3:**

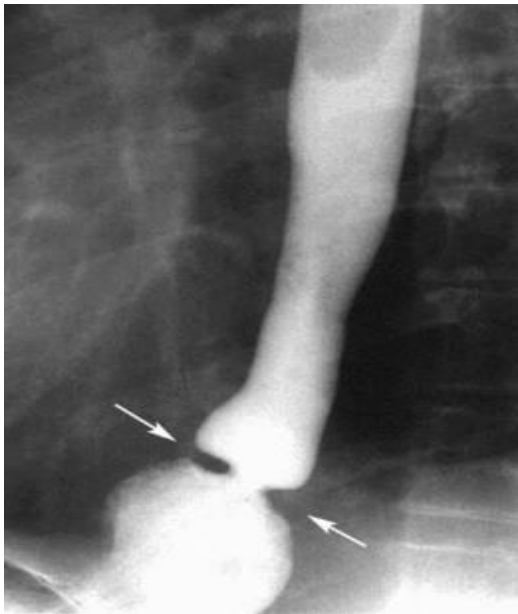


**AP and lateral view: showing Hiatus Hernia**

**Image 4:**



**AP and lateral view: showing Achalasia Cardia**

**Image 5:****Image 5- Lateral view: showing Schatzki's ring**

### Discussion

The present study was conducted in 50 patients. Patients from various different out-patient departments with esophageal symptoms were referred to the department of radio-diagnosis where the study was conducted.

Patients with various esophageal symptoms like dysphagia, vomiting, chest pain, loss of appetite, retrosternal burning and loss of weight were taken for barium swallow examination to rule out various lower esophageal sphincter disorders and were then referred for endoscopy and the results of barium swallow and endoscopy were correlated. Highest number of patients in our study were from 50-60 years and 60-70 years having equal incidence of 22% followed by 40-50 years having incidence of 20%. The least common age group involved was more than 70 years (8%). The youngest patient was 21yrs old and oldest patient was 82yrs old. Mean age observed was 49.7 years among males as well as females.

This was in concordance with study done by Bansal et al<sup>5</sup> who found mean age of patients with motility disorders of 44 yrs. Out of which 67.5% were males and 32.5% were females. Male female ratio was 2:1.

In our study, most of the patients presented with dysphagia (84%) followed by retrosternal burning

(64%), loss of appetite (58%), chest pain (58%), vomiting (46%) and the least common chief complaint was found to be loss of weight (24%).

Barium swallow examination revealed that the most common lower esophageal sphincter disorder was Achalasia cardia found in 32% of cases followed by hiatus hernia (30%), growth gastro-esophageal junction (16%), peptic stricture (12%), schkatzki ring (6%) and least common disorder was esophagitis seen in 4% cases only.

On endoscopic evaluation of these patients we found most common lower esophageal sphincter disorder was Achalasia cardia found in 32% of cases followed by hiatus hernia (26%), growth gastro-esophageal junction (16%), peptic stricture (10%) which were in concordance to our barium swallow examination findings. But, on endoscopic examination 12% cases were found to be normal which were diagnosed with various lower esophageal sphincter disorder on barium swallow. This was found to be in concordance with study done by Bansal et al<sup>5</sup> who found achalasia cardia as the most common lower esophageal sphincter disorder.

On barium swallow examination we found the incidence of various pathologies with gastro-esophageal reflux. We found 42.1% cases of achalasia cardia diagnosed with gastro-esophageal reflux followed by 34.2% cases of hiatus hernia which were diagnosed in gastro-eophageal reflux. Followed by growth ge junction (10.5%), stricture (7.9%), esophagitis and schkatzki ring in 2.6% cases each.

This was found to be in concordance with study by El-Serag HB and Sonnenberg<sup>6</sup> in which 39.1% cases of hiatus hernia were diagnosed in gastro-esophageal reflux disease and 8.4% cases of strictures were diagnosed.

On barium swallow examination, the most common finding found in gastro-esophageal sphincter growth in our study was narrowing, shouldering and filling defect seen in 100% cases of growth ge junction. While reflux which was the most common finding of lower esophageal

sphincter disorders was found in only 50% cases of growth.

On correlation of barium swallow and endoscopic examination we found that achalasia was the most common lower esophageal sphincter disorder diagnosed in 16 patients on both examinations. While hiatus hernia was diagnosed in 15 patients on barium examination, it was diagnosed in 13 patients on endoscopy. Two cases of hiatus hernia were missed on endoscopy. This was in concordance with study done by Weitzendorfer M et al<sup>7</sup> who found that barium examination is more sensitive than endoscopy in detection of hiatus hernia.

Growth of gastro-esophageal junction was diagnosed in 8 patients on both the examinations.

Peptic stricture was diagnosed in 6 patients on barium examination and in 5 patients on endoscopy. One case of peptic stricture was over diagnosed on barium examination. This was in concordance with study done by Hiatt GA<sup>8</sup> who has stated that endoscopy is more sensitive than barium examination in the diagnosis of peptic stricture.

Schkatzki ring was diagnosed in 3 patients on barium examination and in 1 patient on endoscopy. Two cases of schkatzki ring were missed on endoscopy. This is in concordance with study done by Ott DJ et al<sup>9</sup> who found that barium examination is more sensitive than endoscopy in the detection of schkatzki ring.

Esophagitis was diagnosed in 2 patients on barium examination and in 1 patient on endoscopy. One case of esophagitis was missed on endoscopy. This was in concordance with study done by Katzka DA<sup>10</sup> who found that barium examination is more sensitive than endoscopy in detection of esophagitis.

On endoscopy 6 patients were diagnosed as normal study out of which 2 cases were of hiatus hernia and schkatzki ring each and 1 case of peptic stricture and esophagitis each. Hence, Endoscopy confirmed the barium swallow diagnosis in 88% cases.

## Bibliography

1. Demester TR, Peters JH. Oesophagus and diaphragmatic hernia. In: Charlrs F,B runicardi, editors. Schwartz's principle of surgery 8<sup>th</sup> edition. New York:Mcgraw-Hill Professional; 2005.p.836-40.
2. Koehler RE, Weyman PJ, Oakley HF. Single and double-contrast techniques in esophagitis. AJR. 1980; 135:15-9.
3. Creteur V, Thoeni RF, Federle MP, Cello JP, Moss AA, Ominsky SH et al. The role of single and double-contrast radiography in the diagnosis of reflux esophagitis. Radiology. 1983;147(1):71-5.
4. Levine MS, Rubesin SE, Herlinger H, Laufer I. Double-contrast upper gastrointestinal examination: technique and interpretation. Radiology. 1988;168: 593-602.
5. Bansal RK, Nasa M, Patil GK, Shah V, Choudhary NS, Puri R et al. Spectrum of esophageal motility disorders in patients with motor dysphagia and noncardiac chest pain- A single center experience. J Dig Endosc. 2017;8:68-71.
6. El-Serag HB and Sonnenberg A. Associations between different forms of gastro-oesophageal reflux disease. Gut.1997; 41:594-9.
7. Weitzendorfer M, Kohler G, Antoniou SA, Pallwein-Prettner L, Manzenreiter L, Schredl P et al. Preoperative diagnosis of hiatal hernia: barium swallow X-ray, high-resolution manometry, or endoscopy. European Surgery. 2017; 49(5):210-7.
8. Hiatt GA. The roles of esophagoscopy vs. radiography in diagnosing benign peptic esophageal strictures. Gastrointestinal Endoscopy. 1977; 23(4):194-5.
9. Ott DJ, Chen YM, Wu WC, Gelfand DW, Munitz HA. Radiographic and endoscopic sensitivity in detecting lower

esophageal mucosal ring. AJR.  
1986;147:261-5.

10. Katzka DA. The Role of Barium Esophagography in an Endoscopy World. *Gastrointestinal Endoscopy Clinics of North America*. 2014; 24(4):563–80.