



A Clinical Study on Non-Deflatable Foley's Catheter

Authors

Sarath Chandran S, Ashwin Muthukumar R, Vinoth P, Shyam Kiran S. M

Department of Urology, Rajah Muthiah Medical College and Hospital,
Annamalai University, Annamalai Nagar – 608002, India

Abstract

Introduction & Objective: *Bladder catheterisation is a common procedure which is done as a part of management of different illness various catheter can be used for bladder catheterization, Foley's self retaining catheter is commonly used catheter for bladder catheterization. Unlike any therapeutic procedure bladder catheterization has its complications like urethral injury, catheter associated infections, etc., Relatively uncommon complication associated with Foley's catheterization is non-deflatable Foley's which result in unable to remove Foley's catheter. Our objective of the study is to provide protocol plan based on our observation regarding non-deflatable Foley's catheter.*

Material & Methods: *This is a prospective study conducted in Rajah Muthiah Medical College under Department of urology between the period of march 2018 to November 2018. A total of 18 cases reported with difficulty in removal of Foley's catheter following a therapeutic procedure were included in the study.*

Results: *Among 18 patients presented to Department of Urology, 38% of patients treated with simple aspiration along inflation channel was able to solve the problem. In 11.2% of patients cutting the inflation channel and with or without aspiration, Foley's removal was done. In another 11.2% passing ureteral stent was done and successful removal of Foley's achieved and around 38% of patients required invasive procedure.*

Conclusion: *A large number of treatment options are employed in removal of non-deflatable Foley's catheter. Both invasive and non-invasive methods are used. Important history of how long catheter has been placed must be asked and short duration of period less than two weeks defect in inflation channel is the major cause rather than crystallization of inflation fluid and encrustation of catheter which is seen in long standing cases. For short courses invasive techniques are more useful.*

Keywords: *Foley's catheter, Bladder catheterization, Non-deflatable Urethral catheter, Transvaginal Puncture, Cystoscopy.*

Introduction

Bladder cauterisation is done as a part of therapeutic procedure in many circumstances.

Bladder catheterisation is commonly done using self-retaining Foley's catheter, it is most common widely used indwelling catheter.¹ Complications

associated with use of Foley catheter include infection, bladder spasm, catheter encrustation & retained catheter.²

Retained catheter is relatively uncommon complication associated with Foley's catheter. Reasons for non-deflatable Foley's catheter

include malfunction of inflation valve, damage to inflation channel due to crushing during clamping of catheter or crystallization of the inflation fluid.¹² A wide variety of invasive and non-invasive techniques are used removal of non deflatable Foley’s catheter, initially removal by non-invasive method is preferred, if it fails one can resort to invasive method.^{5,6}

Materials & Methods

This is a prospective clinical study on Non-deflatable Foley’s catheter conducted in Department of Urology, in Rajah Muthaiah Medical College and results are analysed.

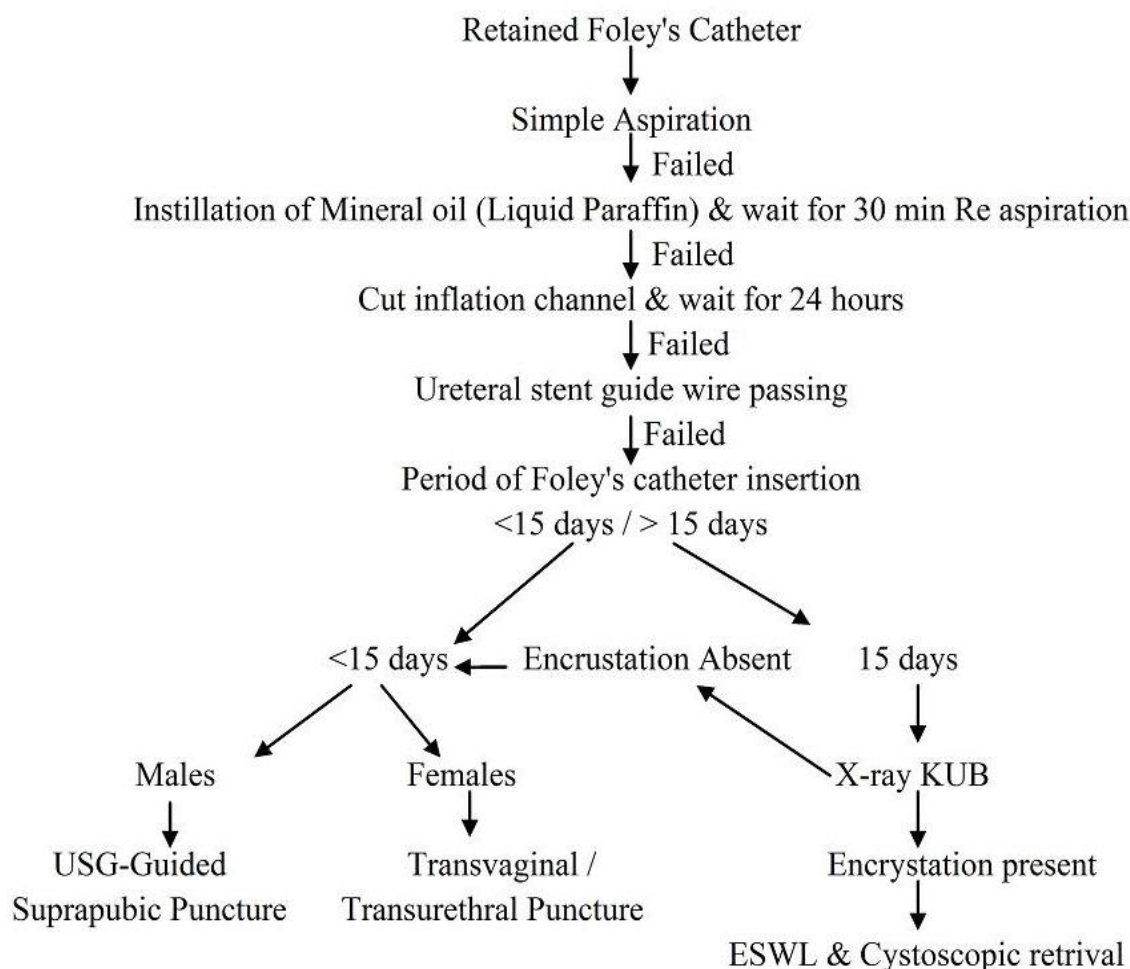
A total of 18 patients were present between the period of March 2018 to November 2018. Out of 18 patients two patients (2) catheterised for benign

prostatic hyperplasia and other patients catheterized for non-urological cause. Other than these two patients all patients presented with a period of catheter placement is within 10 days.

Various methods used to remove non-deflatable Foley’s catheter include, simple aspiration along inflation channel, cutting the inflation channel along with or without aspiration, instillation of mineral oil like liquid paraffin, transabdominal or transvaginal ballon puncture, ESWL of encrusted Folye’s followed by cystoscopic removal are done.^{3,4,5,7,9}

In our study, simple aspiration, instillation of liquid paraffin, cutting of inflation channel, urethral stent guide wire passing, suprapubic & trans vaginal puncture have been employed in removal of Foley’s catheter.

Algorithm used in retained Foleys in our Hospital is given below,



Results

Out of 18 cases presented with non-deflatable Foley's catheter, 15 patients were male and 3 patients were females.

Sex		Total
Male	Female	18
15	3	

In these 18 patients, removal of Foley's catheter is attempted based on algorithm. Out of these different techniques various results are

Method	No. of Patients	Results
Simple Aspiration	7	38%
Mineral Oil Instillation	0	0%
Cutting Inflation Channel	2	11.25%
Ureteral stent guide wire passing	2	11.25%
Transvaginal Balloon puncture	1	5.5%
Suprapubic USG guided balloon puncture	6	33%
Total	18	100%

Out of 18 patients two patients presented with a long period of 35 days and 27 days and all other cases Foley's catheter is placed within a period of 10 days for non-urological cause.

Time	No. of Patients
<15 days	16
>15 days	2
Total	18

Discussion

Non-deflatable Foley's is a common encounter experienced in hospital facility. Lot of invasive and non-invasive methods are used to remove stuck Foley's catheter.¹² Commonly used methods which are not used are rupture of balloon catheter by over inflation and instillation of irritant chemicals like acetone, because of the risk of retained Foley's fragment which acts as infective nidus and irritant chemical causes chemical cystitis and sometimes necrosis of bladder & may end up in nephroureterectomy in undiagnosed reflex patients.¹¹ Only instillation of non-irritant mineral oil like liquid paraffin is used but its success rate was not helpful in our study.¹¹

Other methods which can be used are connecting a syringe to inflation channel and allow it to stay connected for a period of 30 minutes which may result in spontaneous deflation.^{8,10} Aspiration with a 10 ml syringe along the inflation channel was the most successful with success rate of 38% in our study. Cutting the inflation channel and waiting for a period of 24 hours is also helpful in some cases. In cases with catheter placement period more than 15 days mostly due to encrustation and crystallization passing ureteral stent guide wire

along the inflation channel was helpful, in our study 11.25% of patients was treated using this method.

If period of indwelling catheter placement is within 15 days it is most likely due to defective inflation valve or damage to inflation channel due to clamping of the Foley's catheter. In these cases percutaneous or transurethral or transvaginal balloon puncture is done and ureteral stent wire passing was not successful. All patients were treated using treatment algorithm and none of the patients required cystoscopic removal.¹⁰

Conclusion

In management of non-deflatable Foley's catheter rupture of balloon by over inflation & chemical instillation should not be attempted. Least invasive method should be preferred before attempting invasive method. Surgeons should be aware of the techniques and to adopt to technique which is suitable for the patient. While managing a patient with stuck Foley's history of period of catheter placement is important as it point towards the cause of non-deflatable Foley's catheter.

References

1. Cancio LC, Sabanegh ES Jr, Thompson IM. Managing the Foley catheter. *Am Fam Physician* 1993; 48:829-36.
2. Ndirangu K, Ngugi M. Problems of indwelling Foley catheters. *East Afr Med J* 1994;71:132-4.
3. Kleeman FJ. Technique for removal of Foley catheter when balloon does not deflate. *Urology* 1983; 21:416.
4. Vandendris M. How to deflate refractory balloon of a bladder catheter. *Urology* 1985;26:300.
5. Murphy GF, Wood DP Jr. The use of mineral oil to manage the nondeflating Foley catheter. *J Urol* 1993;149:89-90.
6. Ohashi H. [A case of a bladder calculus due to a ruptured balloon fragment of a Foley catheter.] *Hinyokika Kyo* 1997;43:227-8.
7. Anyanwu SN, Apakama IG. Simple methods for the removal of non-deflating balloon bladder catheters suitable for the developing countries. *Trop Doct* 1991;21:84-5.
8. Adebamowo CA, Okeke LI. The retained urinary catheter. *Trop Geogr Med* 1993;45:186-8.
9. Naunton-Morgan TC, Barrett NK, Boulton JE. Simple procedure for the removal of a non-deflating balloon bladder catheter: two cases. *Br J Radiol* 1986; 59:1043-4.
10. Goel MC, Bhaduria RP, Banerjee GK, Kapoor R. A new endoscopic technique for non-deflating Foley balloon. *Arch Esp Urol* 1995;48:973-5.
11. Gattegno B, Michel F, Thibault Ph. A serious complication of vesical ether instillation: ether cystitis. *J of Urol* 1988;139:357-358.
12. Gulmez I, Ekmekcioglu O, Karacagil M. A comparison of various methods to burst Foley catheter balloons and the risk of free-fragment formation. *Br J Urol* 1996;77:716-718.