



Boix-Ochoa Anti Reflux Procedure: An Institutional Experience

Authors

Dr Sunil S Menon^{1*}, Dr Vivek P Sarma², Dr Sivakumar K³, Dr R Hema⁴

¹Additional Professor, ²Associate Professor, ³Professor, ⁴Professor (Retired)

Department of Paediatric Surgery, SAT Hospital, Government Medical College, Thiruvananthapuram, Kerala, India

*Corresponding Author

Dr Sunil S Menon

12 Vasanth Vihar Gardens Kumarapuram, Thiruvananthapuram, Kerala, India, PIN 695011

Email: drsunils@gmail.com, Phone- 9446127448, 04712528390

Introduction

The term GER implies a functional process in a healthy infant with no underlying systemic abnormalities. It is a common condition involving "spitting up" or "throwing up" after eat that does not require treatment. GERD in contrast, is a pathologic process in infants. It manifests with poor weight gain, signs of esophagitis and persistent respiratory symptoms. Careful evaluation and treatment are required. Nissen's fundoplication is the widely used procedure for GERD. Boix-Ochoa procedure for GERD is an alternative to Nissen's fundoplication in the paediatric age group.

Aim of the study

The aim of this series is to study the short term outcome after operative therapy for symptomatic GERD in paediatric patients.

Methods

A retrospective study of 8 patients who underwent Boix-Ochoa procedure for GERD during the period of Dec 2005 to May 2007 was done. This is

a pilot study, as a part of review of all cases that underwent Boix-Ochoa procedure during a ten year period from 2005 to 2015. Operative Indications were either Respiratory disease or Oesophageal disease. Respiratory symptoms were, aspiration pneumonia, reactive airway disease or apnea. Oesophageal symptoms were Hemetemesis and strictures. Pre op evaluation was done with Barium meal study, which showed significant reflux into the oesophagus in all cases.

Results

Eight patients underwent Boix-Ochoa procedure during the period of study. One patient was lost to follow up. Seven patients are on follow up. Mean operating time was 180 minutes. Average blood loss was 75 ml. Average hospital stay was 11.2 days. Ryle's tube was removed on the 3rd post-operative day. One patient had superficial surgical site infection. No patients reported symptoms of gas bloat syndrome. Seven patients on follow up had no reflux on barium meal / cine radiogram taken post operatively. All patients had significant

weight gain at 3 months follow up. None of the patients had recurrence of symptoms.

Principles of the Operation

Boix-Ochoa in his classic paper in Journal of pediatric surgery in 1986 has identified 6 factors which comprise the anti-reflux barrier. All of these operate over the lower esophageal sphincter.

1. Intra-abdominal Esophagus is the key to LES and to successful fundoplication. It determines the length of esophagus exposed to intra-abdominal pressure; and therefore, the length of esophageal valve holding back potential refluxate. A sufficient segment of abdominal esophagus is considered $>2\text{ cm}$ and a mechanically incompetent LES has an abdominal length $<1\text{ cm}$, or an overall sphincter length $<2\text{ cm}$.
2. Pinch-Cock action by the right crus of the diaphragm, which forms a sling-shaped orifice around the esophagus. This pulls the esophagus to the right and downward with deep inspiration.
3. Angle of His locates the junction of esophagus and the stomach. In a child with normal-sized intra-abdominal esophagus this angle is acute.
4. Redundant folds of mucosa referred to as the Mucosal Rosette, at the gastro-esophageal junction, is present only when the angle of His is normal. These folds squeeze together to form a weak valve with increased intra gastric pressure.
5. An area of high pressure zone with increased muscular thickness is present near the gastro esophageal junction. The basal tone of HPZ increases until 45 days of age, at which maturation is complete.
6. Intra-abdominal pressure between 6-8 cmH_2O is necessary to maintain competent LES by collapsing the intra-abdominal segment.

Operative Procedure

The intra-abdominal oesophagus was mobilized. Lower oesophagus was anchored to the esophageal hiatus. Restoration of the angle of HIS was done. Partial anterior plication was done and the fundus stitched to diaphragm. (Refer Figures 1 – 4). Post Op Evaluation was done by Barium meal study /Cine radiogram to ensure complete resolution of GER.

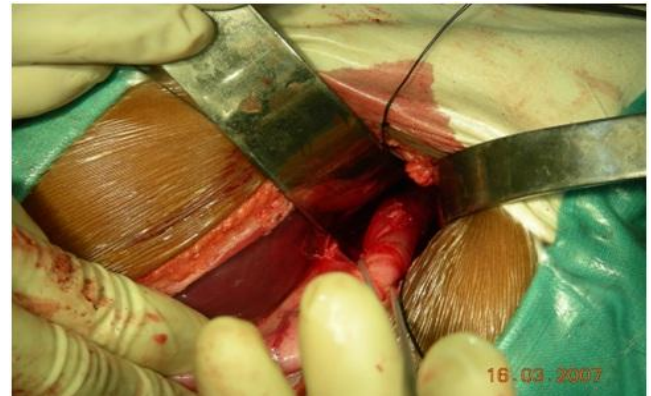

Figure 1: Mobilisation of intra-abdominal oesophagus

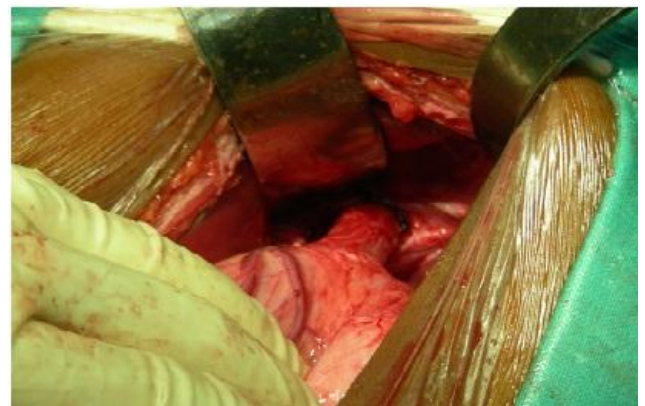

Figure 2 : Anchoring of intra-abdominal oesophagus to crura of diaphragm

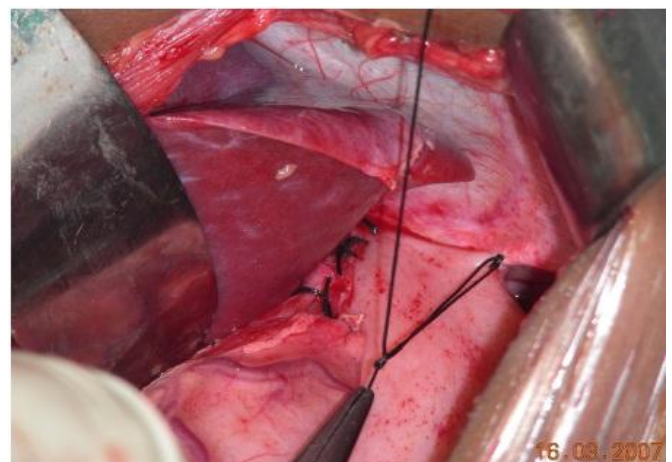


Figure 3 : Fundus of the stomach anchored to the diaphragm

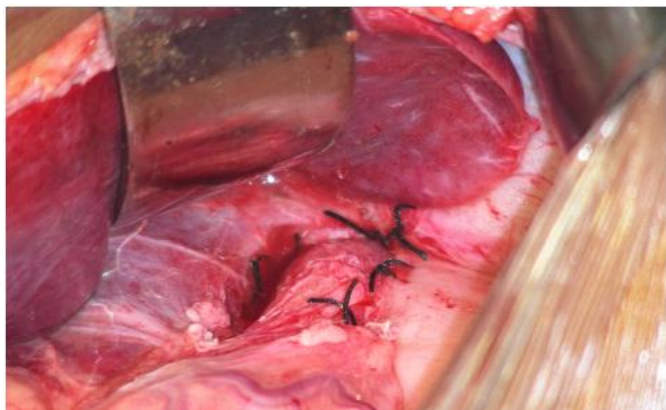


Figure 4 : Partial anterior plication

Conclusion

Problems with the commonly performed Nissen's fundoplication, as per the literature are, belching, retching, inability to vomit and gas bloat syndrome. BOIX-OCHOA procedure is an anti-reflux surgical approach which induces more physiological results, as it enables vomiting, belching and the natural release of the neo-valve during deglutition; all of which are important in children.

References

1. Boix-Ochoa J, Casasa JM (1989) Surgical treatment of gastroesophageal reflux in children. *Surg Annu* 21:97–118
2. Bardaji C, Boix-Ochoa J (1986) Contribution of the His angle to the gastroesophageal antireflux mechanism. *Pediatr Surg Int* 1:172–174
3. Oldham, K, Massey, M. Antireflux surgery. in: *Pediatric Surgery and Urology: Long Term Outcomes*. Saunders, Philadelphia, PA; 1998:189–213.
4. Boix-Ochoa, J. Address of honored guest: The physiologic approach to the management of gastric esophageal reflux. *J Pediatr Surg*. 1986;21:1032–1039.
5. Casasa JM, Boix-Ochoa J (1977) Surgical or conservative treatment in hiatal hernias in children: a new decisive parameter. *Surgery* 82:573–575
6. Boix Ochoa J (1986) The physiologic approach to the management of gastric esophageal reflux. *J Pediatr Surg* 21:1032–1039.
7. Pearl, R, Robie, D, Ein, S et al, Complications of gastroesophageal reflux antireflux surgery in neurologically impaired versus neurologically normal children. *J Pediatr Surg*. 1990;25:1169–1173.
8. Boix-Ochoa, J, Rowe, M. Gastroesophageal reflux. in: *Pediatric Surgery*. Vol. 1., Mosby-Year Book, St Louis, MO; 1998:1007–1017.
9. Cohen Z, et al. (1999) Nissen fundoplication and Boix-Ochoa antireflux procedure: comparison between two surgical techniques in the treatment of gastroesophageal reflux in children. *Eur J Pediatr Surg* 9(5): 289–293.
10. Maxson, R, Harp, S, Jackson, R et al, Delayed gastric emptying in neurologically impaired children with gastroesophageal reflux: The role of pyloroplasty. *J Pediatr Surg*. 1994;29:726–729.