



Bilateral Gonadoblastoma with Extensive Calcification in 46 XX Karyotype Female- A Rare Case Report

Authors

Dr. Sushma Bharti MD, Dr. Shantilal M. Sisodia MD, Dr. Zeba Ali MD

Grant Government Medical College and Sir J. J. Group of Hospitals, Mumbai, India

Corresponding Author

Dr. Sushma Bharti MD

Address: Flat no 1202, B - Wing, Mangaldeep Apartment, In front of Pal Balaji Temple, Pal Road, Jodhpur, Rajasthan 342001, India

Abstract

Gonadoblastomas are rare tumors frequently appearing in the dysgenetic gonads with Y chromosome anomaly. We reported a case of gonadoblastoma in young female of age 16 years, admitted to our hospital for evaluation of early onset secondary amenorrhea since six month. Pubertal development was Tanner stage 3 and had normal 46XX karyotype. MRI Pelvis was suggestive of ovarian endometriomas. She underwent bilateral prophylactic gonadectomy. Pathological assessment found streak ovary with gonadoblastoma and foci of dysgerminoma component with extensive areas of calcification. The prophylactic gonadectomy is needed if patient carry Y chromosome or malignant components like dysgerminoma.

Keywords: Gonadoblastoma, dysgerminoma, calcification, karyotype.

Introduction

Gonadoblastoma (GBY) are rare germ cell sex cord stromal tumor, consisting of mixture of gonadal cells and sex-cord stromal derivatives resembling immature granulosa cells and sertoli cells.^[1] Gonadoblastoma usually arises in dysgenetic gonads with Y chromosome anomaly.^[1,2,3,4] The karyotype of these individuals is mostly 46,XY, mosaic 45,X/46,XY or 45,X.^[2,3] However, rare cases with normal 46, XX karyotype have been reported.^[1] Phenotypically, 80% of patients with gonadoblastoma are females while males occupy the remaining 20%.^[2] Gonadoblastoma have a distinctive histological appearance which distinguishes them from any other gonadal neoplasm and were first described

by Scully^[4] in 1953. In 50%–60% of cases, gonadoblastomas are associated with malignant germ cell tumors, mostly presenting as pure dysgerminoma or less frequently as immature teratoma, Yolk sac tumor, embryonal carcinoma or choriocarcinoma.^[5]

Case Report

A 16 years old young female, nulligravida, admitted to our hospital for the investigation of early onset secondary amenorrhea since six months. She had attained menarche at the age of 13 years. On examination, the girl was short statured with hirsutism. Her built was moderate. Breast development (Tanner stage 3) and pubic hair were normal. Her external genitalia appeared

female. The patient had no endocrine disorders and had no other relevant medical, personal and family history. Ultrasonography showed normal uterus measuring 5.8x3.1x2 cm with large cyst in right adnexa having solid components suggestive of chocolate cyst/ endometriosis/complex cyst. Left ovary appeared to be normal. MRI pelvis showed a well-defined multi-loculated cyst in pelvis of right adnexa and left adnexa also showed altered signal intensity lesions extending from posterior uterus of left side reaching up to left adnexa. Left and right ovaries were not seen separately. Tumor markers showed normal CA-125 with elevation of LDH. Thyroid profile was normal. Karyotyping revealed a normal 46XX karyotype. She underwent an exploratory laparotomy. Specimen was sent for frozen section. We received specimen of bilateral ovo-testis mass measuring 7x5x2 cm and 6x6x2 cm. Externally both masses were encapsulated, smooth and congested. On opening, masses showed solid areas with gritty to cut and firm in consistency. The second mass was cystic. On opening contains thick brownish fluid. No solid areas were seen in second mass. Maximum wall thickness was 0.5 cm. Also received rudimentary ovary, measuring 2x1x0.1 cm, grayish white. On cutting, grayish white and homogeneous. Microscopically, there was nest of intimate mixture of germ cells with abundant clear cytoplasm resembling seminoma or dysgerminoma and smaller epithelial cells of sex cord type resembling immature sertoli cells or granulosa cells arranged in a background of dense connective tissues. Hyaline bodies were also seen. Some of the tumor cells were undergoing changes of dystrophic calcification. Mitotic figures were not seen. Also seen small tubules lined by immature sertoli cells suggestive of testicular mass. Cystic mass was diagnosed as endometriotic cyst. Ovarian tissues and fallopian tubes were also identified. Morphology was obliterated by extensive calcification, which typically appeared laminated spheres or mulberry like masses. Computed tomography scans of the chest, abdomen and pelvis were performed for

metastatic evaluation and did not reveal abnormality. This case was evaluated as gonadoblastoma with malignant component of dysgerminoma in normal 46 XX karyotype female.

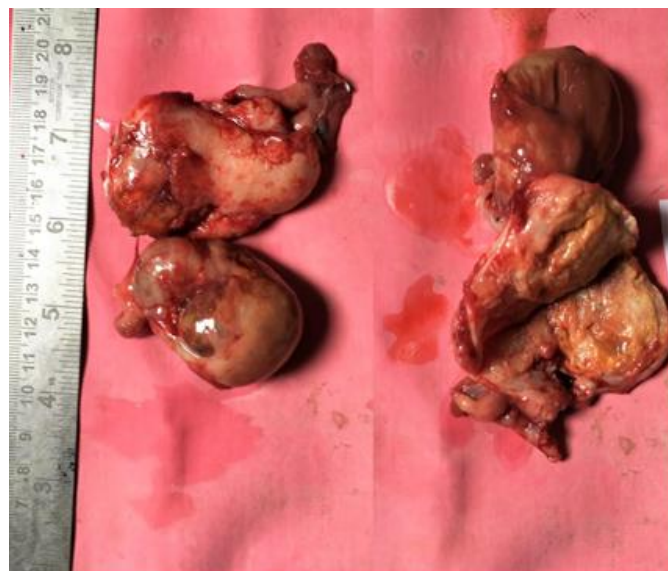


Figure 1: Gross picture of gonadoblastoma and endometriotic cyst

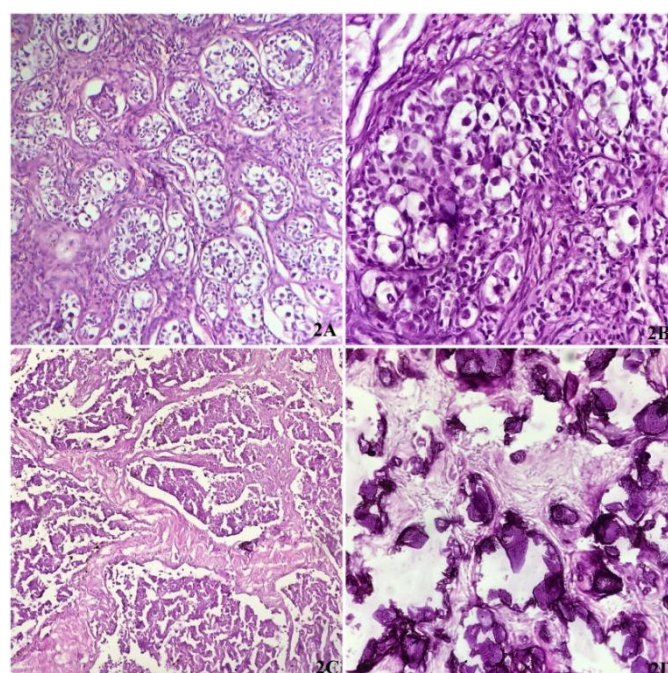


Figure 2: Microscopy of gonadoblastoma showing nest of intimate mixture of germ cells with abundant clear cytoplasm [2A,2B] and smaller epithelial cells of sex cord type [2C] arranged in a background of dense connective tissues. Also seen areas of dystrophic calcification. [2D]

Discussion

GBYs are found in 25%–30% of patients with XY gonadal dysgenesis and in 15%–20% of 45X/46XY individuals.^[6] Only a small proportion of GBYs develops in 46XX females with no evidence of Y chromosome. The GBY locus is the only oncogenic locus on the human Y chromosome.^[6] About 10 cases of GBY have been reported in normal XX karyotype.^[1] Esin et al^[7], in their literature search from PubMed, reported seven cases of GBY in women with normal karyotype from 1990 to 2007 including their case. All cases were in young females, the youngest being 10 years old and the oldest 27 years. All had coexisting germ cell tumor, GBY being common. The incidence of GBY in fertile women continues to be extremely rare.^[5] Yilmaz et al^[8], described bilateral gonadoblastoma with dysgerminoma in a 20 years old girl, who was managed with bilateral salphingo-oophorectomy followed by chemotherapy. The patient was free of disease five years after initial therapy. Gonadoblastomas are usually small and occasionally, they are microscopic findings. Histologically, tumor cells resemble dysgerminoma admixed with sex cord derivatives similar to sertoli or granulosa cells. Calcification, sometimes massive (burn-out gonadoblastoma), can be seen.^[2] In 50% of the gonadoblastoma cases, dysgerminoma overgrowth can be identified and they tend to metastasize and need further therapy.^[9] Pure gonadoblastomas have a low grade clinical course with no risk of metastasis. The prognosis is deteriorated if dysgerminoma overgrowth is present.^[2] We reported one case of gonadoblastoma with malignant component of dysgerminoma in normal 46 XX karyotype female, came in hospital for evaluation of secondary amenorrhea.

Conclusion

Multiple sections and careful histopathological examination is necessary for correctly diagnose underlying component of GBY. This is a unique case of GBY with dysgerminoma in normal women with normal menarche age.

References

1. Kanagal DV, Prasad K, Rajesh A, Kumar RG, Cherian S, Shetty H, et al. Ovarian gonadoblastoma with dysgerminoma in a young girl with 46, XX karyotype: A case report. *J Clin Diagn Res* 2013;7:2021-2.
2. Yi-Che Changchien, Iren Haltrichb, TamasMicsika et al. Gonadoblastoma: Case report of two young patients with isochromosome 12p found in the dysgerminoma overgrowth component in one case. *Pathology – Research and Practice* 2012;628–32.
3. Ozge Yuce, Esra Doğer, Nurullah Celik et al. Gonadoblastoma with Dysgerminoma in a Phenotypically Turner-Like Girl with 45,X/46,XY Karyotype. *J Clin Res Pediatr Endocrinol* 2015;7(4):336-9.
4. Scully RE. Gonadoblastoma – a review of 74 cases. *Cancer* 1970; 25: 1340-56.
5. Gelincik I, Ozen S, Bayram I. Left ovarian gonadoblastoma with yolk sac tumor in a young woman. *Indian J PatholMicrobiol* 2010;53:345-6.
6. Kulkarni MM, Khandeparkar SGS, Joshi AR, Bhayekar PV. Unilateral gonadoblastoma with dysgerminoma in normal fertile woman having a child: Extremely rare occurrence with characteristic immunohistomorphology. *Indian Journal of Pathology and microbiology* 2016;59(4).
7. Esin S, Baser E, Kucukozkan T, Magden HA. Ovarian gonadoblastoma with dysgerminoma in a 15-year-old girl with 46, XX karyotype: Case report and review of the literature. *Arch Gynecol Obstet* 2012;285:447-51.
8. Yilmaz B, Gungor T, Bayramoglu H, Soysal S, Mollamahmutoglu L. Bilateral ovarian gonadoblastoma with coexisting dysgerminoma in a girl with 46, XX karyotype. *J Obstet Gynaecol Res* 2010; 36(3):697-700.
9. Tumours of the breast and female genital organs, IARC Press, Lyon, 2003.