



## Temporalis Myofascial Flap Interpositional Arthroplasty with Bilateral Coronoideotomy for Management of Unilateral TMJ Ankylosis: A Retrospective Study

Author

**Pramod Sharma**

Professor, Department of Dentistry, Chirayu Medical College, Bhopal, MP, India

Email: [drpramodmids@gmail.com](mailto:drpramodmids@gmail.com), Phone: 9300772999

### Abstract

**Introduction:** Temporomandibular joint (TMJ) ankylosis is an extremely disabling condition seen commonly. Surgical management of TMJ ankylosis needs careful planning and thorough evaluation to achieve good results.

**Aims & Objectives:** This study was conducted with the aim to evaluate the role of interpositional arthroplasty using temporalis myofascial flap with bilateral coronoideotomy in achieving maximum interincisal mouth opening (MIO) in unilateral TMJ ankylosis.

**Materials and Methods:** A total of 16 patients with unilateral TMJ ankylosis were included in the study. The patients underwent interpositional arthroplasty using temporalis myofascial flap along with bilateral coronoideotomy under general anaesthesia. Pre and post operative MIO's were measured.

**Results:** The mean MIO after osteoarthrectomy and ipsilateral coronoideotomy was 33.5mm. The mean MIO after bilateral coronoideotomy was 42.1mm. The mean increase in MIO after bilateral coronoideotomy was 8.75mm. There were no recurrences in any patient in this study.

**Conclusion:** The present study shows that temporalis myofascial flap is a good choice for interpositional arthroplasty for management of TMJ ankylosis. Bilateral coronoideotomy in unilateral TMJ ankylosis gives better intraoperative mouth opening which was maintained in the long term.

**Keywords:** TMJ Ankylosis, Temporalis, Myofascial, Arthroplasty, Interpositional arthroplasty, TMJ Surgery.

### Introduction

TMJ Ankylosis is one of the most debilitating conditions affecting the maxillofacial region. Although rare in the developed world, it is an affliction that is quite common in underdeveloped or developing countries.<sup>[1]</sup>

It is an extremely disabling condition which most commonly affects the growing child resulting in difficulty in opening mouth thereby causing

problem in mastication, speech, potential airway obstruction, improper dental care and a progressive facial deformity and its associated psychological and social effects.<sup>[2-5]</sup>

TMJ ankylosis is classified on the basis of location as Intra or extra articular, as bony, fibrous or fibro-osseous based on type of tissue and complete or incomplete based on extent.<sup>[6]</sup>

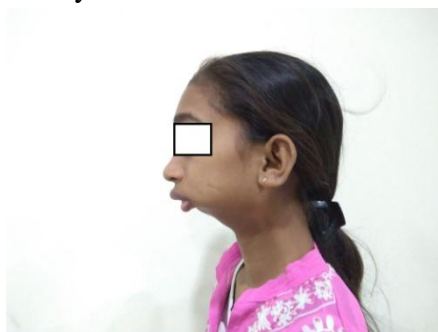The only effective means of correcting this condition is surgery. Various surgical procedures

for the treatment of bony ankylosis have been suggested. The three basic techniques used are:<sup>[2,4,5,10,12]</sup>

- a) Gap Arthroplasty
- b) Joint reconstruction
- c) Interpositional arthroplasty

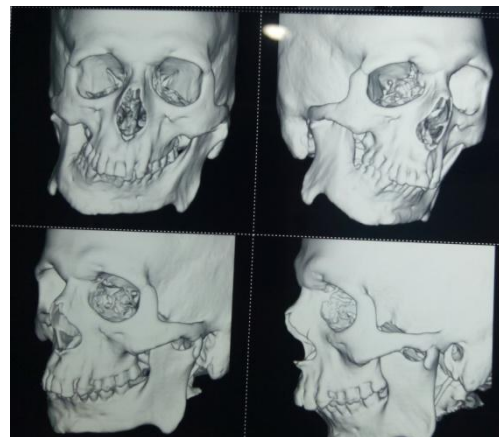### Materials and Methods

This is a retrospective study of the patients with unilateral TMJ ankylosis operated between November 2013 to March 2018 in Department of Dentistry, Chirayu Medical College, Bhopal. A total of 16 patients with unilateral TMJ ankylosis who underwent interpositional arthroplasty were included in the study. Patients with bilateral TMJ ankylosis were excluded from this study. Out of the total 16 cases, 4 cases were recurrent TMJ ankylosis. 11 patients were females while 5 were males. Right side involvement was seen in 9 cases and left side in 7 cases. The age of the patients ranged from 5 years to 21 years. Mean interincisal mouth opening ranged from 0-6mm. Aetiology of the ankylosis was trauma in 15 cases and one case had a history of ear infection. All patients underwent a thorough clinical examination including measurement of the maximum interincisal opening (MIO), chin deviation, range of lateral excursions and severity of facial deformity.

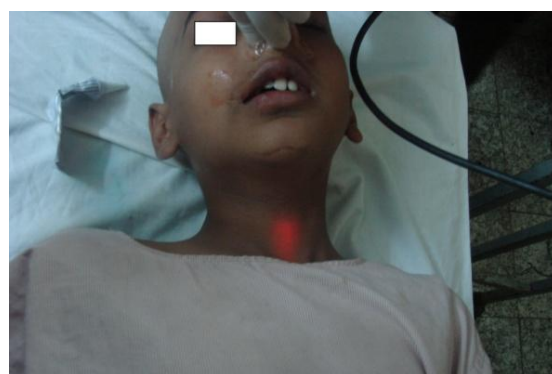


**Figure 1:** Facial deformity in TMJ Ankylosis

CT scans with axial and coronal sections and 3-D reconstruction were done in all patients. All patients underwent surgery under general anaesthesia. Fibre-optic nasal intubation was done in 11 cases, blind nasal intubation in one case and tracheostomy was done in four cases after attempting fibre-optic intubation.

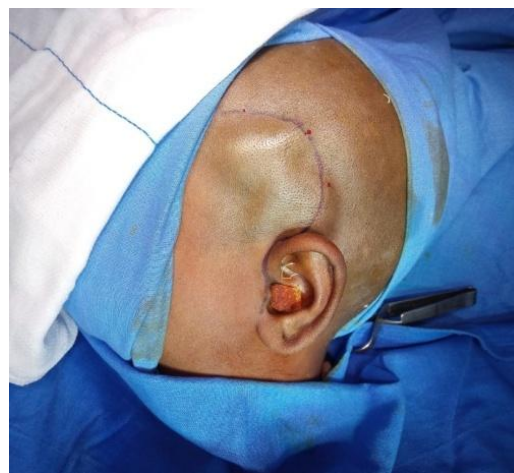

**Figure 2:** CT Scan with 3-D reconstruction



**Figure 2:** Awake fibre optic nasal intubation

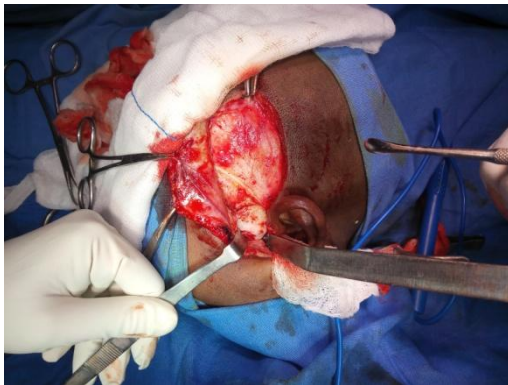**Surgical Procedure:** After nasal intubation or tracheostomy and sterile preparation, the Alkayat-Bramley incision was marked in the scalp and preauricular region.<sup>[7]</sup> 2% Lignocaine with 1:100000 adrenaline was infiltrated along the incision line to aid in vasoconstriction. Incision was started in the scalp with a no.15 B.P blade and flap was raised.



**Figure 3:** Alkayat-Bramley's incision marked

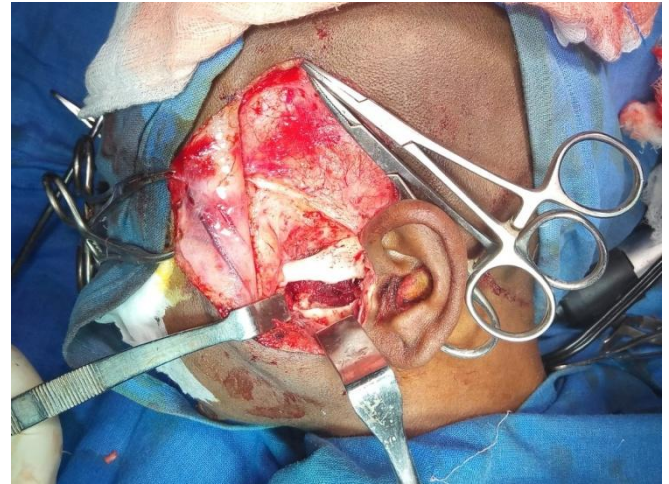

Dissection was carried out in the superficial temporalis fascia plane until about 2cm above the zygomatic arch. Careful blunt dissection was carried out till the root of zygoma and a 45° incision running forwards and upwards was placed over the superficial layer of temporalis fascia. The periosteum of the zygomatic arch was then incised and reflected with the outer layer of temporalis fascia and skin. In the preauricular region sharp dissection was carried along the cartilaginous external auditory canal and the ankylosed mass was exposed. Further subperiosteal dissection along the zygomatic arch was done to expose the ankylosed mass and the coronoid process better. A curved TMJ retractor was introduced from the posterior border of the ankylosed mass to protect the structures lying medial to the ankylosis.

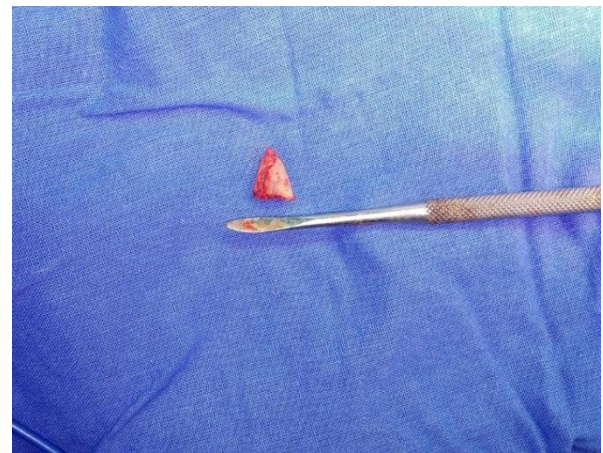

**Figure 4:** Ankylosed mass exposed

A large round bur and osteotomes were used to complete the osteo-arthrectomy and create a gap of about 1.5-2cm. Ipsilateral coronoid which is usually elongated was then exposed by inserting a channel retractor at the anterior margin of the coronoid. Temporalis muscle fibres were detached from the coronoid process using micro-cautery and coronoidectomy was carried out with rotary burs. The coronoid process was removed. In 4 patients with severely elongated coronoid process, the temporalis muscle fibres were split longitudinally to deliver the coronoid process.

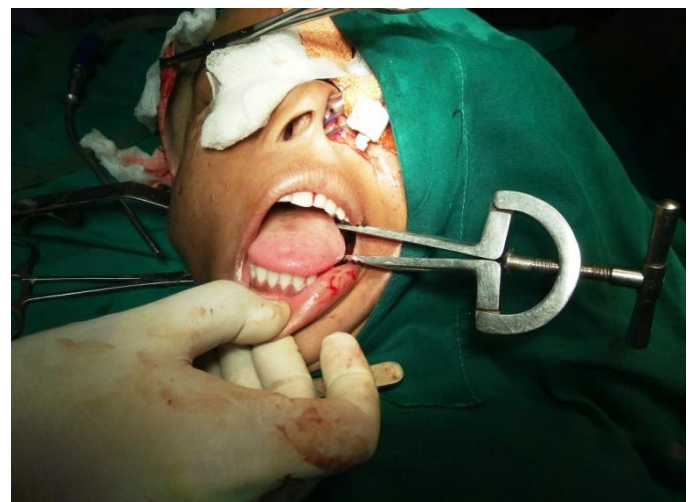


**Figure 5:** Osteo-arthrectomy done with gap of 2cm



**Figure 6:** Ipsilateral coronoidectomy done

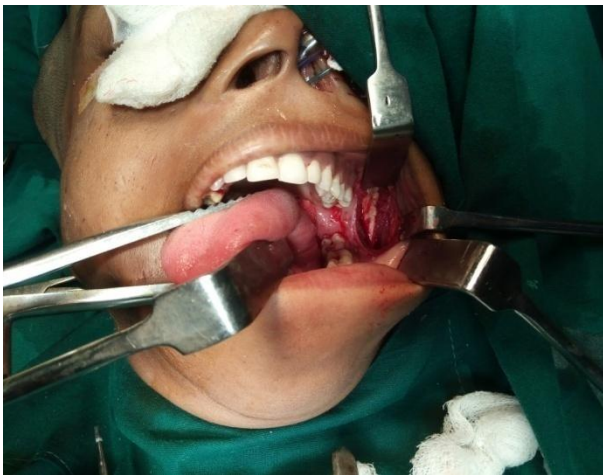Hemostasis was carefully checked and a Heister's mouth gag was introduced between the teeth in molar region and opened gently to maximum inter-incisal opening. The MIO was recorded at this point.



**Figure 7:** Mouth opening after osteo-arthrectomy and ipsilateral coronoidectomy

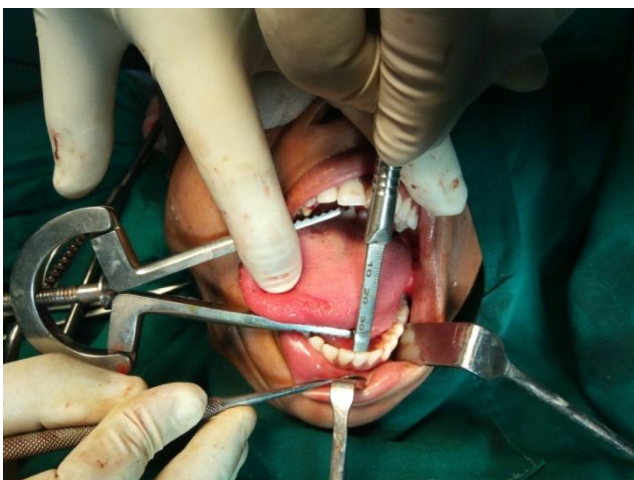

Contralateral coronoidectomy was done transorally. A 3 cm long incision was placed in the buccal mucosa along the anterior border of ramus. Dissection was done till the bone was reached. Using a sharp periosteal elevator, subperiosteal dissection was done superiorly along the anterior border of the ramus till the coronoid process was reached. Insertions of the temporalis fibres were stripped using cautery and a forked ramus retractor was used to retract the tissues. Coronoid process was osteotomised with burs and delivered.



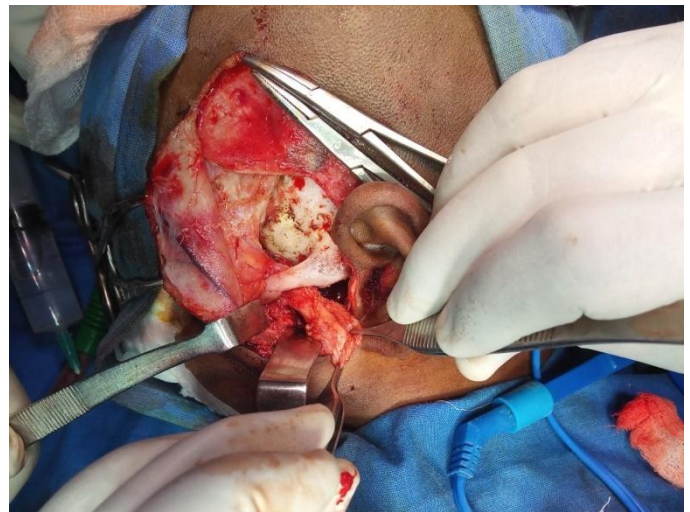**Figure 8:** Transoral exposure of contralateral coronoid

Heister's mouth gag was now activated further to increase the mouth opening and the MIO was recorded. Transoral incision was closed in single layer with 4-0 vicryl sutures.

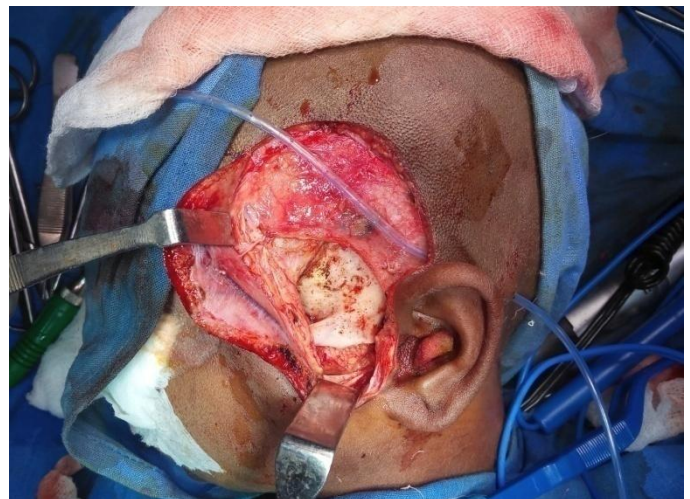

**Figure 10:** Mouth opening after bilateral coronoidectomy

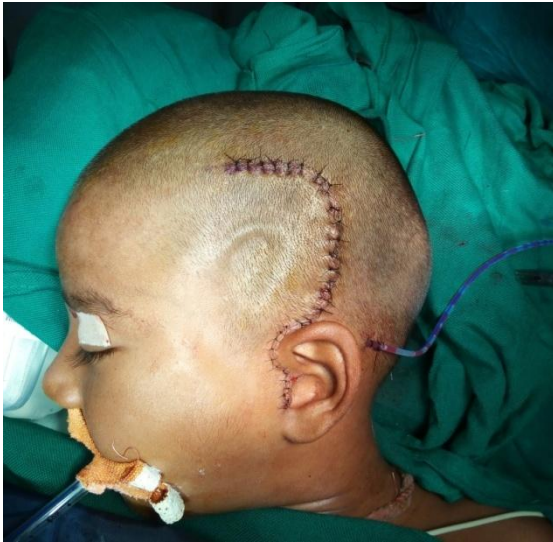A full thickness inferiorly based temporalis myofascial flap comprising of fascia, muscle and the underlying periosteum was marked with methylene blue and dissected with cautery to the bone. A sharp periosteal elevator was used to lift the flap and it was tunneled below the zygomatic arch to reach the gap created. The flap was now placed between the gap and secured with 4-0 vicryl sutures so that it covered the entire bony surface of the gap created. A no.6 or 8 drain was placed and a layer wise closure done with 4-0 vicryl, 4-0 ethilon for scalp and 6-0 ethilon for the preauricular incision.



**Figure 11:** Temporalis myofascial flap tunneled below the zygomatic arch



**Figure 12:** Flap interposed in the gap



**Figure 13:** Incision Closed

Cotton pads were placed over the ears and the frontal eminence and a modified mastoid bandage was applied. Drains were removed after 48 hours. Mouth opening exercises were started from the 4<sup>th</sup> post operative day using wooden spatulas. Preauricular sutures were removed on the 5<sup>th</sup> postoperative day and the scalp sutures on the 10<sup>th</sup> post op day. Careful monitoring of the mouth opening physiotherapy was done. Patients were kept on regular follow up and the MIO was recorded at each visit at 1month, 3 month and 6 months.

### Results

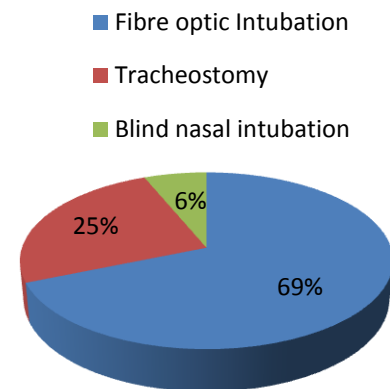
The study comprised of a total of 16 patients with unilateral TMJ ankylosis operated using the same protocol by the same surgeon. All patients underwent Interpositional arthroplasty using temporalis myofascial flap with bilateral coronoidectomy under general anaesthesia.

Out of the total 16 cases, 4 cases were recurrent TMJ ankylosis. 11 patients were females while 5 were males. Right side involvement was seen in 9 cases and left side in 7 cases. The age of the patients ranged from 5 years to 21 years. Mean inter-incisal mouth opening ranged from 0-6mm. Aetiology of the ankylosis was trauma in 15 cases and one case had a history of ear infection. All patients underwent a thorough clinical examination including measurement of the maximum interincisal

opening (MIO), chin deviation, range of lateral excursions and severity of facial deformity.

CT scans with axial and coronal sections and 3-D reconstruction were done in all patients. All patients underwent surgery under general anaesthesia.

Fibre-optic nasal intubation was done in 11 cases, blind nasal intubation in one case and tracheostomy was done in four cases.



**Figure 14:** Methods of Anaesthesia

The intra-operative MIO achieved after gap arthroplasty with ipsilateral coronoidectomy ranged from 32mm to 36mm with a mean MIO of 33.5mm. The intraoperative MIO after contralateral coronoidectomy ranged from 39mm to 47mm with a mean MIO of 42.1mm. The increase in the MIO after contralateral coronoidectomy ranged from 6mm to 12 mm with a mean MIO of 8.75mm. The mean MIO at 1 month, 3 months and 6 months were 37.43mm, 34.5mm and 37.18mm respectively. There were no recurrence in our series.

**Table 1** Demographic data and Clinical results of Patients

Patient	Age	Sex	Pre Op MIO	Intra Op MIO after ipsilateral coronoidectomy	Intra Op MIO after contra lateral coronoidectomy	Increase in MIO after contra lateral coronoidectomy	MIO 1 month	MIO 3 months	MIO 6 months
1	6 yr	M	3mm	32mm	41mm	9mm	39mm	38mm	38mm
2	5 yr	F	0mm	33mm	42mm	9mm	36mm	36mm	37mm
3	11 yr	F	1mm	34mm	44mm	10mm	37mm	36mm	36mm
4	14 yr	F	6mm	35mm	42mm	7mm	38mm	40mm	40mm
5	21 yr	F	3mm	35mm	47mm	12mm	41mm	39mm	39mm
6	19 yr	M	0mm	33mm	44mm	11mm	37mm	35mm	36mm
7	7 yr	M	4mm	34mm	41mm	7mm	35mm	34mm	36mm
8	9 yr	F	2mm	33mm	39mm	6mm	36mm	37mm	38mm
9	8 yr	F	1mm	33mm	40mm	7mm	34mm	33mm	33mm
10	20 yr	F	4mm	34mm	46mm	12mm	41mm	42mm	42mm
11	13 yr	F	0mm	36mm	44mm	8mm	40mm	38mm	38mm
12	7 yr	M	4mm	32mm	39mm	7mm	35mm	36mm	36mm
13	11 yr	F	6mm	33mm	44mm	11mm	40mm	38mm	38mm
14	9 yr	F	2mm	32mm	40mm	8mm	37mm	37mm	37mm
15	17 yr	M	4mm	34mm	42mm	8mm	38mm	35mm	36mm
16	15 yr	F	0mm	31mm	39mm	8mm	35mm	34mm	35mm

## Discussion

The main goal of treatment of TMJ ankylosis is to establish normal mouth opening and function.<sup>[8]</sup>

Normal mouth opening in adults which is measured as the interincisal distance ranges from 40mm to 56mm. In case of children the interincisal distance varies depending on the stature and child's age.

In post traumatic TMJ ankylosis there is displacement or destruction of the meniscal cartilage resulting in bone to bone contact either directly or via blood clot has a potential for osteogenesis resulting in extensive fusion at the level of the joint.<sup>[9]</sup> Trauma and infection are cited as the most common reasons for TMJ ankylosis.<sup>[2,3,10]</sup> In our study of 16 patients, 15 patients (93.75%) had trauma as the cause. In only 1 patient, the cause could be attributed to middle ear infection. It is thus evident that infection as a major cause of TMJ ankylosis is decreasing. This can be attributed to the fact that infections are now being controlled by the advent of the newer antibiotics.

The only treatment option for TMJ ankylosis is surgery. The surgical options include:

- Gap arthroplasty
- Joint reconstruction
- Interpositional arthroplasty.

Several materials have been used for interpositional arthroplasty – temporalis fascia, Temporalis muscle, fascia lata, dermis, full thickness skin, auricular

cartilage, buccal fat pad and a variety of alloplastic materials.<sup>[11-17]</sup> Alloplastic materials have a very high percentage of migration and extrusion resulting in reankylosis.<sup>[11]</sup> In our series, one patient who had undergone interpositional arthroplasty using silastic sheet at another centre had reported to us with a recurrence. We removed the silastic sheet during the surgery and it was found in the pre auricular area in the extra articular zone embedded in the soft tissues. (Fig. 15)

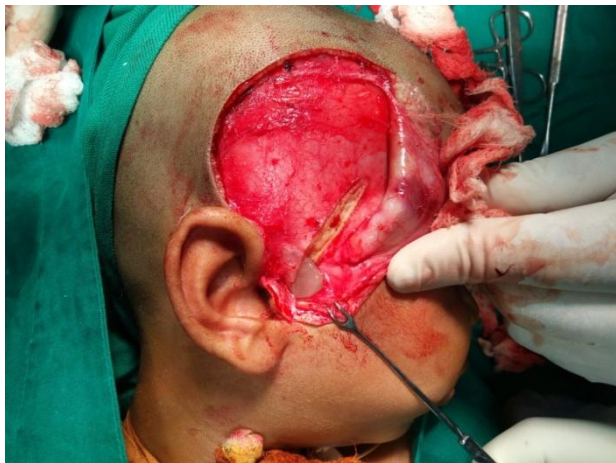Interpositional arthroplasty with temporalis muscle was advocated by Feinberg, Pogrel, Umeda and by Su Gwan.<sup>[5,12,14,15]</sup> I have used a composite temporalis myofascial flap comprised of the temporalis fascia, temporalis muscle and the underlying periosteum. This axial flap can be easily rotated and tunneled below the zygomatic arch which prevents the bulkiness in the region and makes it very easy to reach the complete extent of the created gap.

Umeda et al have demonstrated by magnetic resonance imaging that the temporalis muscle flap used in TMJ ankylosis appears to be viable and the tissue signal compatible with vital muscle/and/or fat as opposed to tissue scarring.<sup>[14]</sup>

Ipsilateral coronoidectomy is advocated in TMJ ankylosis as it helps in increasing the mouth opening.<sup>[5,10]</sup> Contralateral coronoidectomy is



advocated if the mouth opening was less than 35 mm.<sup>[5,10]</sup> But in my series I have done bilateral coronoidectomy in all cases of unilateral ankylosis. There was a mean increase of 8.75mm in MIO following bilateral coronoidectomy. This resulted in achieving a better mouth opening.



**Figure 15:** Silastic sheet removed in a recurrent TMJ Ankylosis case

### Conclusions

The present study shows that temporalis myofascial flap is a good choice for interpositional arthroplasty for management of TMJ ankylosis. Bilateral coronoidectomy in unilateral TMJ ankylosis gives better intraoperative mouth opening which was maintained in the long term.

**Conflicting Interest:** None

**Sources of Support:** None

### Patient Consent

The author certifies that he has obtained all appropriate patient consent forms. In the forms the patients have given their consent for his/her images and other clinical information to be reported in the journal. The patients understand that their names and initials will not be published and due efforts will be made to conceal their identity, but anonymity cannot be guaranteed.

### References

1. Sugar AW, Pradhan R. Temporomandibular joint ankylosis in the growing child:

costochondral grafting as an approach to management. *Ind J Surg.*1984;252-362

2. Chidzonga MM. Temporomandibular joint ankylosis: review of thirty-twocases. *Br J Oral Maxillofac Surg.*1999 Apr;37(2):123-6.
3. Roychoudhury A, Parkash H, Trikha A. Functional restoration by gap arthroplasty in temporomandibular joint ankylosis: a report of 50 cases. *Oral Surg Oral Med Oral Pathol Oral Radiol Endod.* 1999 Feb;87(2):166-9.
4. Güven O. Treatment of temporomandibular joint ankylosis by a modified fossa prosthesis. *J Craniomaxillofac Surg.* 2004 Aug;32(4):236-42.
5. Su-Gwan K. Treatment of temporomandibular joint ankylosis with temporalis muscle and fascia flap. *Int J Oral Maxillofac Surg.* 2001 Jun;30(3):189-93.
6. Kazanjian VH: Temporo-mandibular ankylosis with mandibular retrusion. *American Journal of Surgery*, 1955;90: 905-910.
7. Al kayat A, Bramley P: A modified pre-auricular approach to the Temporo-mandibular joint and molar arch. *British Journal of Oral Surgery*, 1979; 17:91-103.
8. Rowe NL. Ankylosis of the temporomandibular joint. *J Royal College of Surgeons of Edinburgh.*1982;27(2);67-79
9. Laskin DM: Role of the meniscus in the etiology of post traumatic temporomandibular joint ankylosis. *International Journal of Oral Surgery*, 978;7(4):340-345.
10. Kaban LB, Perrott DH, Fisher K. A protocol for management of temporomandibular joint ankylosis. *J Oral Maxillofac Surg*, 1990;48(11):1145-1151.
11. Chossegros C, Guyot L, Cheynet F, Blanc JL, Gola R, Bourezak Z, *et al.* Comparison of different materials for interposition arthroplasty in treatment of temporomandibular joint ankylosis surgery: Long-term follow-up in 25 cases. *Br J Oral Maxillofac Surg* 1997;35:157-60

12. Pogrel MA, Kaban LB: The role of a temporalis fascia and muscle flap in temporomandibular joint surgery. *Journal of Oral and Maxillofacial Surgery*, 1990; 48(1):14-19.
13. Khadka A, Hu J. Autogenous grafts for condylar reconstruction in treatment of TMJ ankylosis: current concepts and considerations for the future. *Int. J. Oral Maxillofac. Surg.* 2012; 41: 94-102.
14. Umeda H, Kaban LB, Pogrel MA, Stren M, Rotskoff KS: Long-term viability of temporalis muscle/fascia flap used for temporomandibular reconstruction. *Journal of Oral and Maxillofacial Surgery*, 1993; 51(5): 530-534.
15. Feinberg SE, Larsen PE: The use of a pedicled temporalis muscle-pericranial flap for replacement of the TMJ disc: preliminary report. *Journal of Oral and Maxillofacial Surgery*, 1989; 47: 142-146.
16. Smith JA, Sandler NA, Ozaki WH, Braun TW: Subjective and objective assessment of the temporal myofascial flap in previously operated temporomandibular joints. *Journal of Oral and Maxillofacial Surgery*, 1999; 57(9): 1058-1065.
17. Macintosh RB. The use of autogenous tissues for temporomandibular joint reconstruction. *J Oral Maxillofac Surg*, 2000; 58: 63-69.