



## A Study of the Cystic Artery in Calot's Triangle by Gross Dissection and during Laparoscopic Cholecystectomy Procedure

Author

**Satyashree Ray**

S.C.B. Medical College and Hospital, Cuttack, Odisha, 753007, India

### Abstract

*Laparoscopic cholecystectomy is the gold standard treatment for cholecystitis and cholelithiasis. But such minimal access surgery requires accurate knowledge of the structures in and around the calot's triangle. One of the structure is the cystic artery, which presents a lot of variation in this region. Ignorance of the variations of this structure during L.C. causes problematic haemorrhage and unnecessary conversion to open cholecystectomy. This study tries to find the variations of distribution of the cystic artery in relation to the CHD and tries to compare it with that found during, Laparoscopic cholecystectomy. The findings are compared with other previous studies.*

**Keywords:** *Laparoscopic cholecystectomy, cystic artery, common hepatic duct, Calot's triangle.*

### Introduction

Laparoscopic cholecystectomy is currently the gold standard treatment for cholecystitis<sup>(1,2)</sup>. Dr Eddie Reddick established the classical four port technique of L.C.

The difficulties encounters in L.C. are in many steps of the operative procedure but the most important step is identifying, Calot's triangle and skeletonization of cystic artery and cystic duct<sup>(3)</sup>.

Accurate knowledge of the Calot's triangle is essential for both open and L.C.<sup>(6,7)</sup>. Calot's triangle which is also known as hepatobiliary triangle, is by current definition is bounded by cystic duct to the right, CHD to the left and the inferior surface of the liver on the superior aspect.

The contents of the triangle include the right hepatic artery, the cystic artery, the cystic lymph node (of lund), connective tissue and lymphatics. The cystic artery is a branch of the RHA and is

usually given off in the Calot's.<sup>(9)</sup> Laparoscopic cholecystectomy can have higher conversion rates, if the surgeon is inexperienced and possible not well acquainted with variations of cystic artery in the Calot's triangle. This leads to problematic haemorrhage and bile duct injury in the attempt to gain rapid haemostasis<sup>(9,10,11,12)</sup>. The procedure could be converted from laparoscopic to open cholecystectomy. Worldwide the accepted conversion rate is 2-6%.<sup>(13)</sup>

Anatomic variations in Calot's triangle are common. Variations in cystic artery anatomy, based on its origin, position and number are well documented.<sup>(14,15,16,17,18)</sup>. There are different variations in different ethnic groups<sup>(19,20)</sup>. This is an attempt to study the cystic artery variations in the Odishan population by both gross anatomical method and Laparoscopic method.

**Material & Methods**

The present study was divided into two parts. 50 livers with gall bladder were collected from the dissecting room of the department of Anatomy, S.C.B. Medical College & Hospital, Cuttack. The Cystic artery was studied by blunt dissection method.

In the second part of the study, the Calot’s triangle was studied from the recorded video tapes of L.C of 100 cases which was conducted in the laparoscopic surgery operations from of

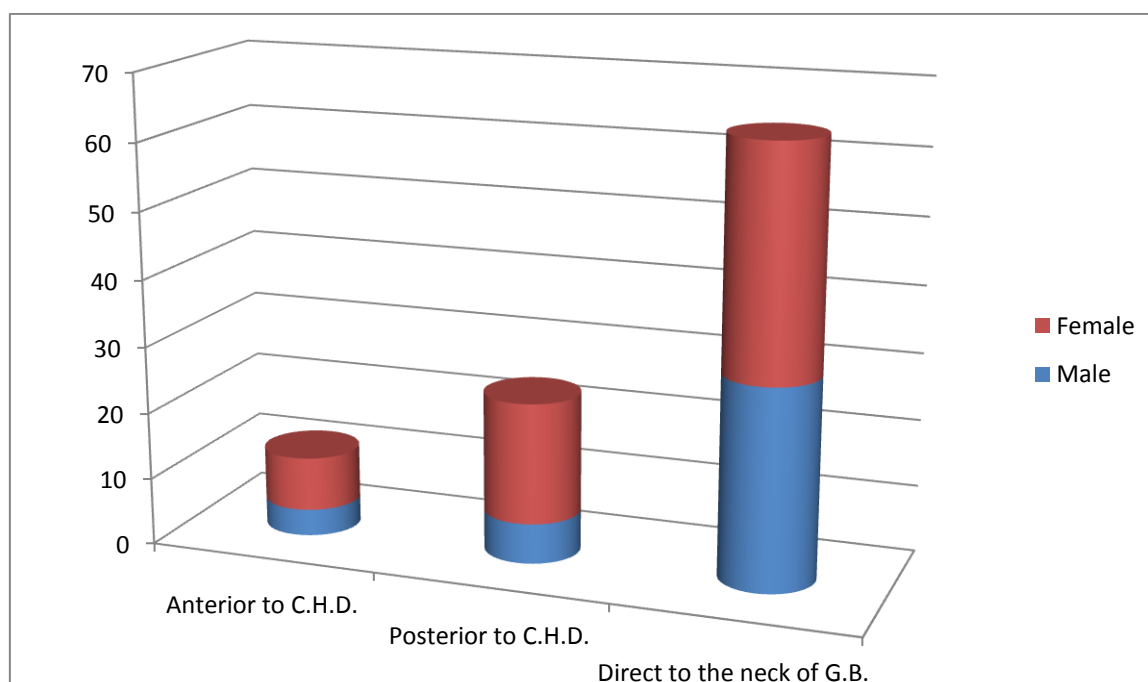
Department of surgery, S.C.B. Medical College, Cuttack

**Observations & Results**

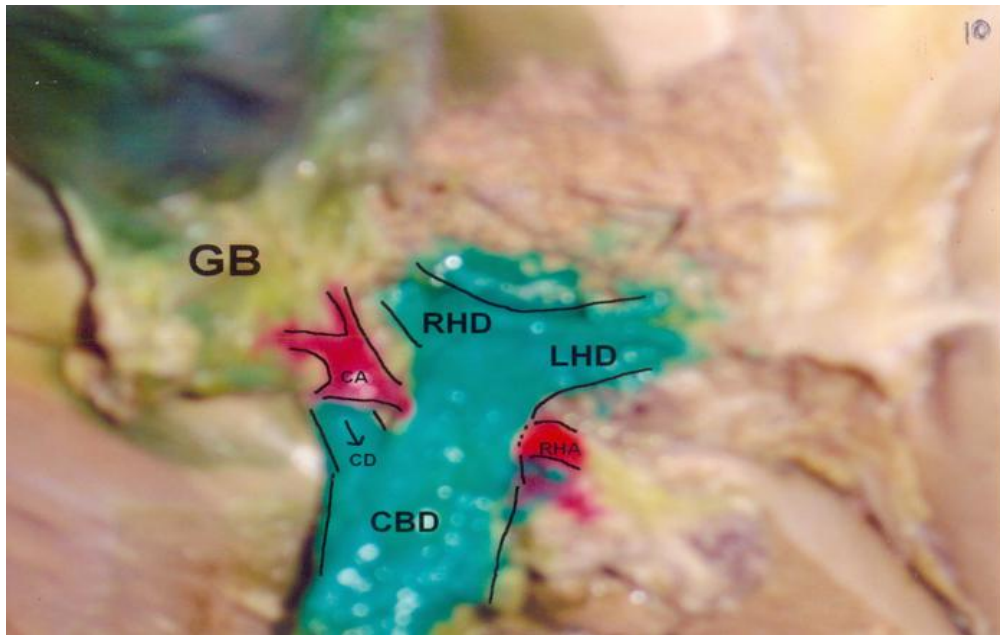
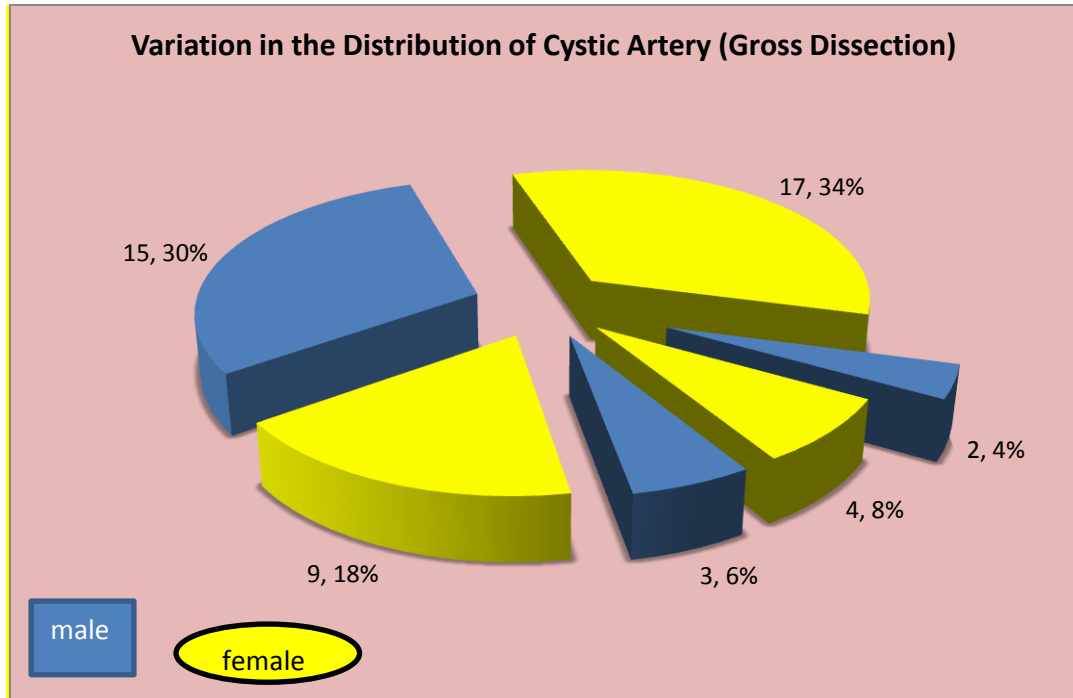
Out of the 50 specimens dissected in the department of Anatomy, S.C.B. Medical college, cuttack; It was found that the variation of the distribution of the cystic artery anterior to the common hepatic duct was 12%, 24% of cystic artery lay posterior to the CHD, 64% of cystic artery supplied directly to the neck of the bile duct.

**Table 1** Variation in Distribution of Cystic Artery (Gross Dissection)

	Total	Male	Percentage Frequency	Female	Percentage frequency	Male to female ratio
Anterior to (CHD	6	2	4	4	8	1:2
Posterior to CHD	12	3	6	9	18	1:3
Direct to the neck of gall bladder	32	15	30	17	34	1:1

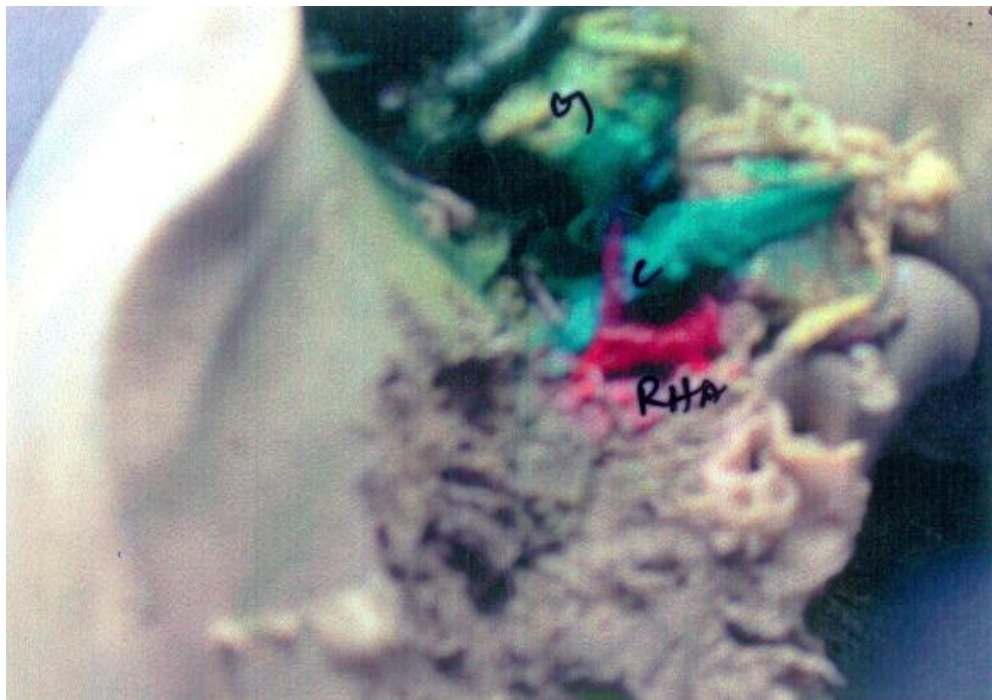

**Fig.1** Bar graph showing the relative percentages of variation in the distribution of cystic artery

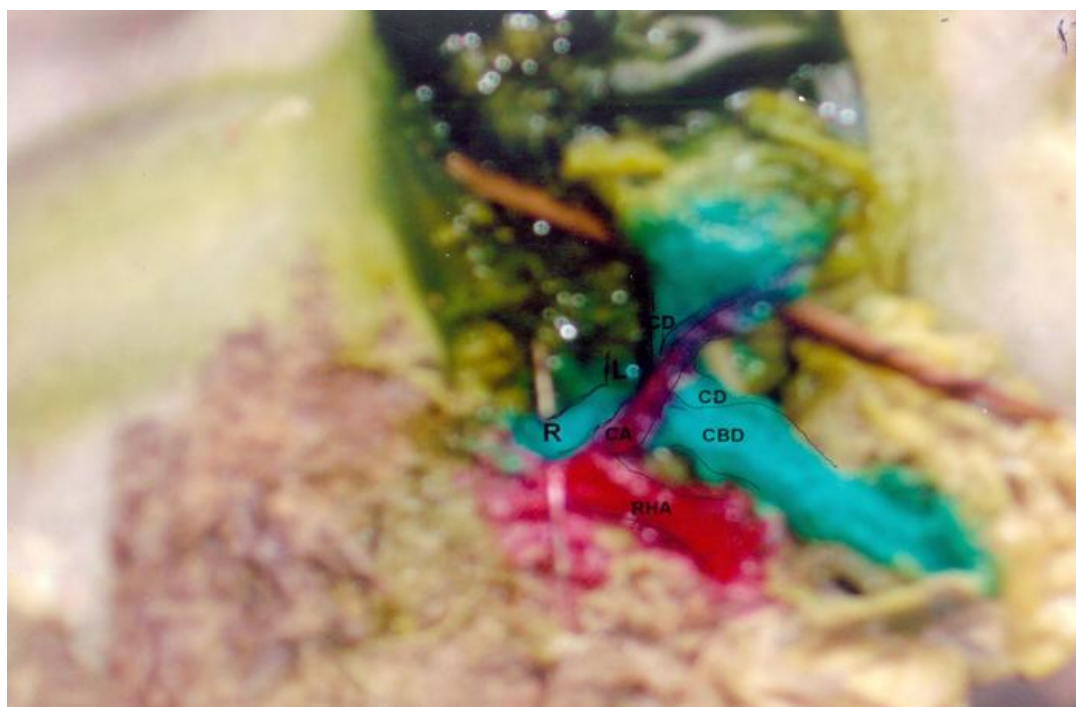


**Plate1:** Cystic artery posterior to common hepatic duct

- R.H.D.- Right Hepatic Duct
- L.H.D.- Left Hepatic Duct
- C.B.D.- Common Bile Duct
- C.D.- Cystic Duct
- C.A.-Cystic Artery
- R.H.A.-Right hepatic Artery
- G.B.-Gall Bladder



**Plate 2:** Cystic artery originating from right hepatic artery and anterior to common hepatic duct  
 G- Gall bladder  
 C-Cystic artery  
 R.H.A.-Right hepatic artery



**Plate no3 .**Cystic artery directly to the neck of gall bladder

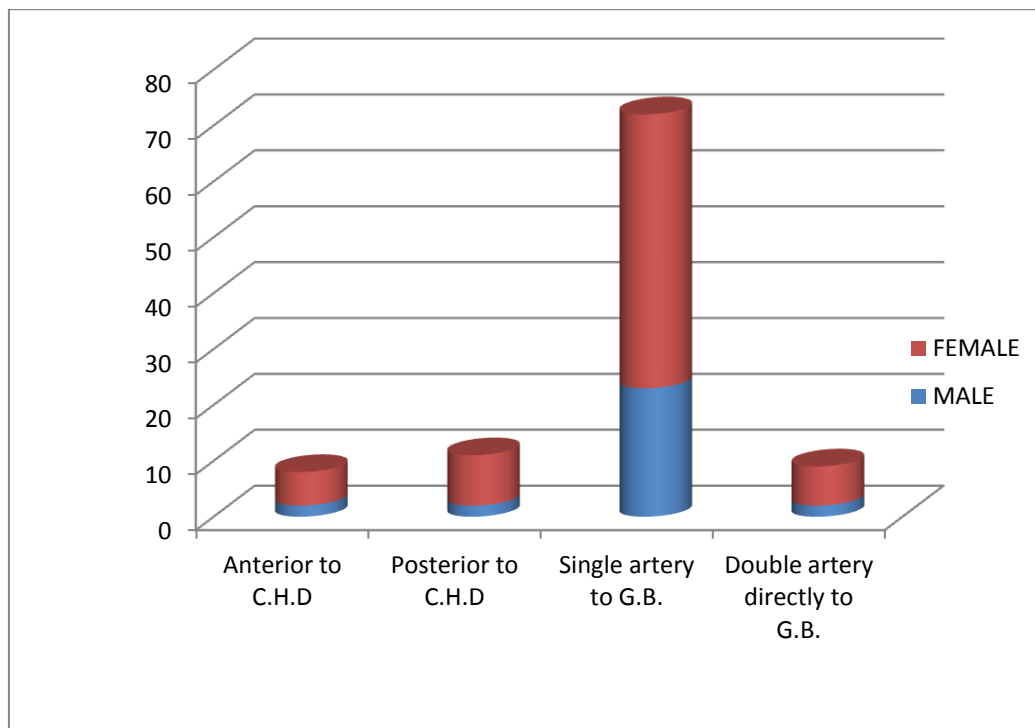
- C.B.D.-common hepatic duct
- R.H.A.-right hepatic artery
- C.A.-cystic artery
- C.D.-cystic duct
- L- left hepatic duct
- R-right hepatic duct

In the L.P. 8% of cystic artery were anterior of the CHD, 11% of cystic artery were posterior to the CHD, 72% of cystic artery were a single branch to

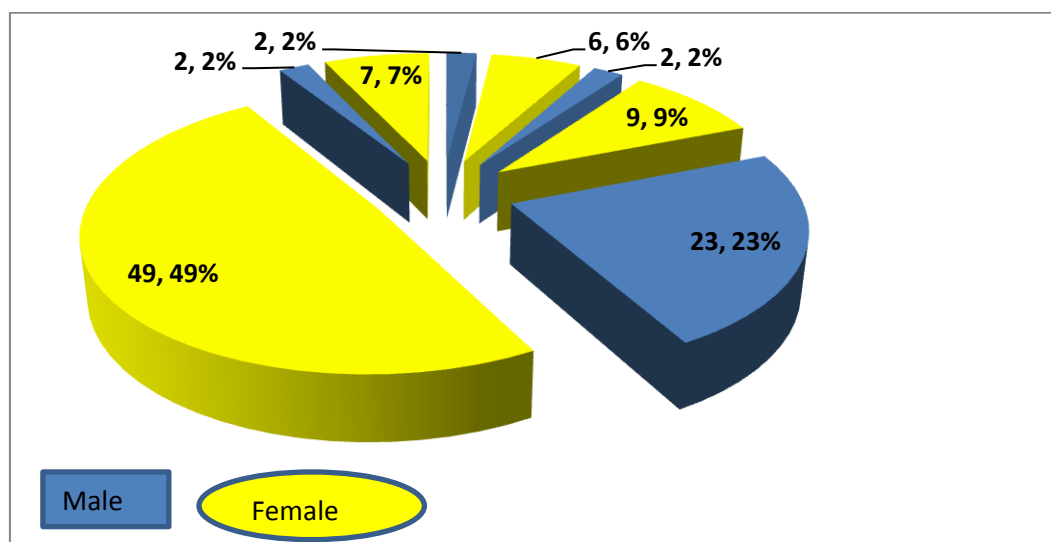
the gall bladder. Double cystic artery accounted for 9% of cases, which supplied the gall bladder.

**Table 2** Variation in Distribution in Cystic Artery (Laparoscopic Surgery)

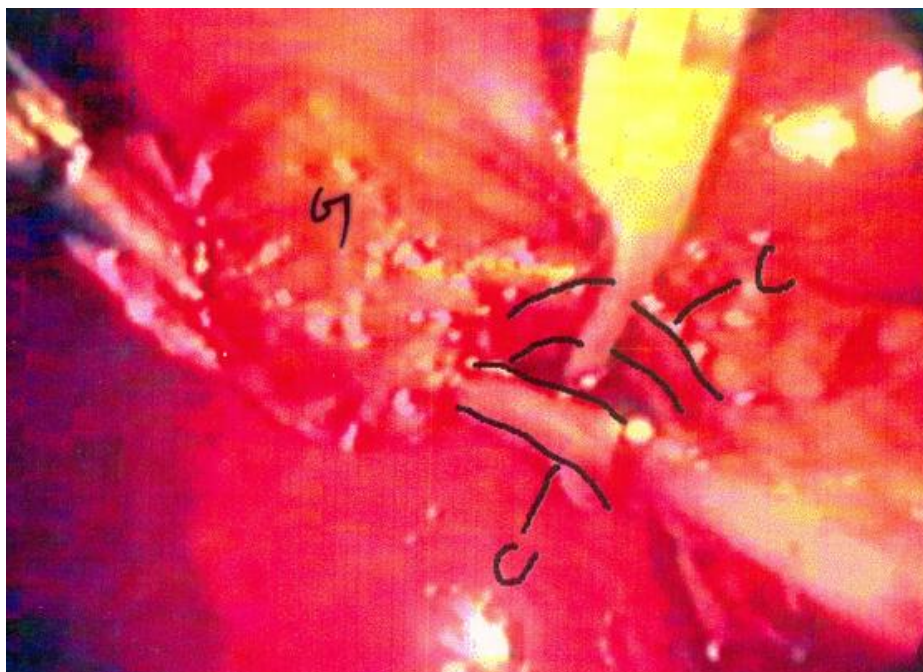
	Total	Male	% frequency	Female	% frequency	M:F Ratio
Anterior to the C.H.D.	8	2	2	6	6	1:3
Posterior to C.H.D.	11	2	2	9	9	1:4 approx.
Single artery to G.B.	72	23	23	49	49	1:2 approx
Double artery directly to the G.B.	9	2	2	7	7	1:2 approx.



**Fig .3** Bar graph showing variation in distribution of cystic artery (laparoscopic surgery)

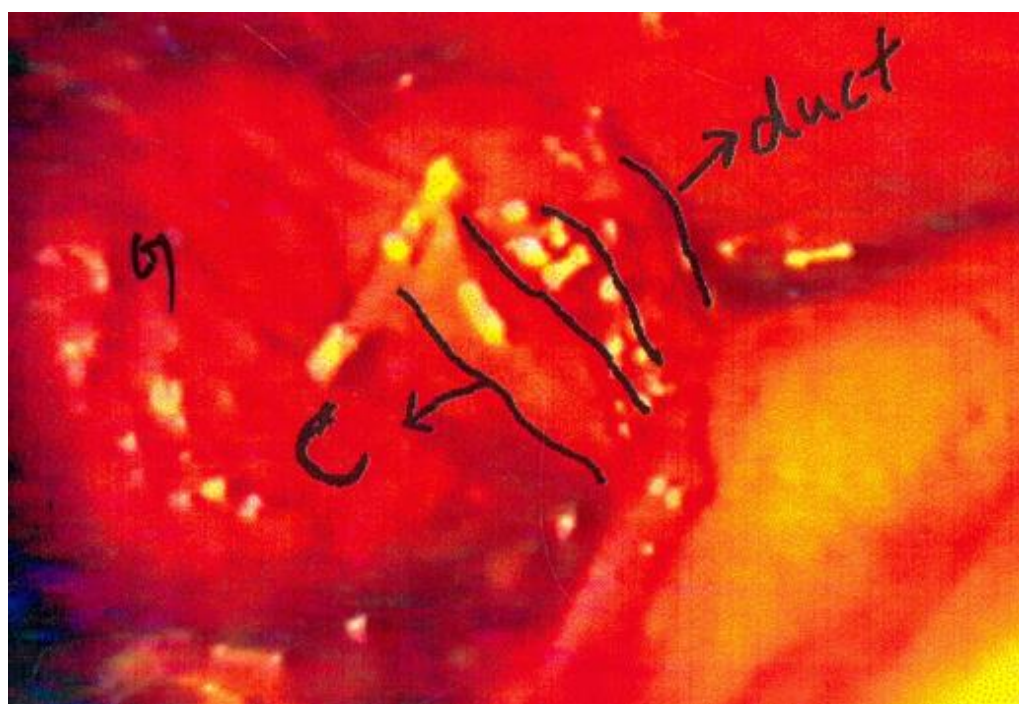


**Fig. 4** Pie chart showing the percentage variation in cystic artery distribution (Laparoscopic surgery)



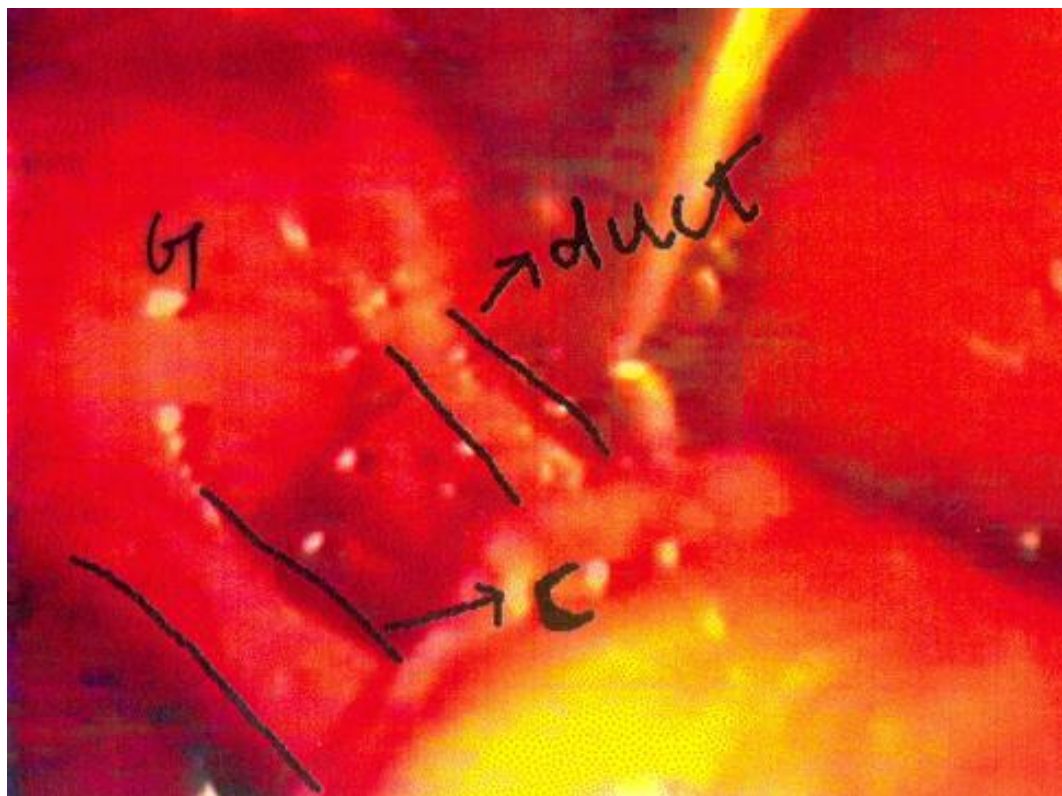
**Plate no4-**Laparoscopic photograph showing double cystic artery

- C-cystic artery 1
- C-cystic artery 2
- G- gall bladder



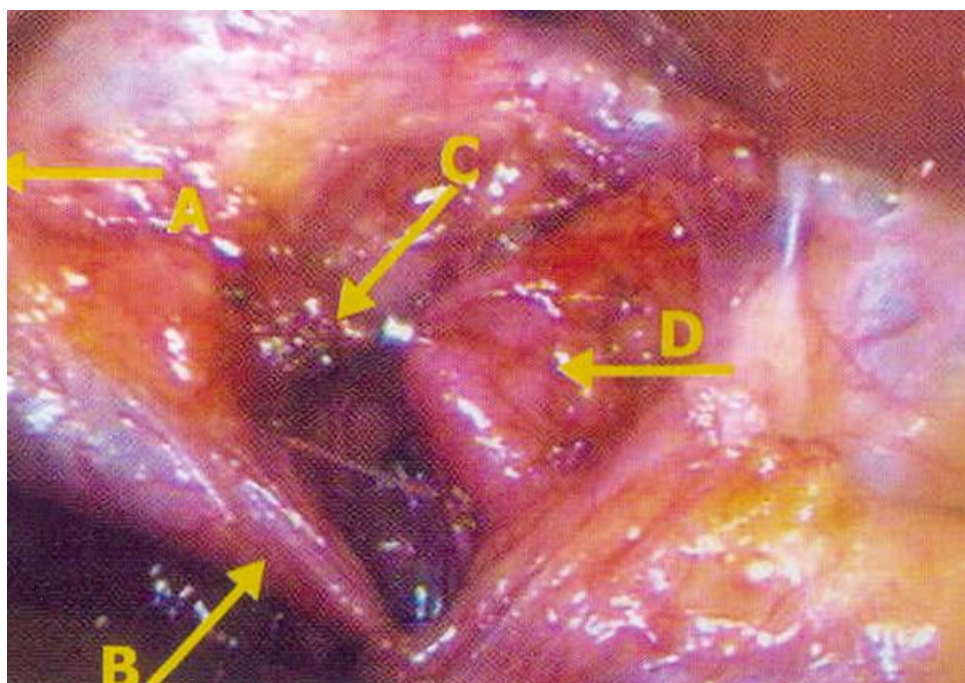
**Plate no 5-**Laparoscopic photograph of cystic artery anterior to common hepatic duct

- C- cystic artery
- Duct- cystic duct
- G-gall bladder



**Plate no6-** Laparoscopic photograph of single cystic artery to gall bladder

- G- Gall bladder
- C-Cystic artery
- Duct-Cystic duct



**Plate no7-** Cystic artery posterior to the common hepatic duct

- A-Gall bladder
- B-Cystic duct
- C-Cystic artery
- D-Common hepatic duct

The present findings differs from the findings of Chen T.H. et. al., Flisinski P. et al., Ahmed et al. where 72.7%, 67.66% and 63% of cystic artery pass posterior to the CHD respectively, which is more than double the findings of the present series. At the same time Touli J. (1993) has stated that the cystic artery remains anterior to the hepatic duct (84%) and posterior in 16% cases. The present series agrees with findings of Touli J. (1993).

In the L.P. method the cystic artery anterior to the CHD is 3 times less than the findings of Michels N.A (1951). (Other papers on the laparoscopic viewing of cystic artery are silent about the position of cystic artery in relation to CHD). The series agrees with the findings of Suzuki M. et al. (2000), Rashid A. et al. (2015), where around 76% of cystic artery supply straight to the gall bladder. Baliya M. et al stated that 73.5% of the cystic artery in his study remain within the hepatobiliary triangle without mentioning its relationship to the C.H.D. Torres K .et al (2009) suggest 4.5% cystic artery lying posterior to the cystic duct. The present series stated percentage is double the above percent of cases.

The doubling of cystic artery as seen through L.P. varies from 2 to 15% (15%). The present series is within the variation, but leans more towards the higher percentage of double cystic artery findings (15,17,24,25).

In the present series the cystic artery observed anterior to the CHD in both procedures were quite similar. The cystic artery observed posterior to the CHD in the gross dissection procedure, is about double the percentage as was observed during L.C. This could be due to less number of gross specimens studied. Double cystic arteries were discovered more in case of L.C. due to magnified picture that the laparoscopic view provided.

### Conclusion

As the present study shows that the cystic artery displays a high degree of variation in terms of its course to the gall bladder and its relation to the C.H.D in the Odishan population, more studies are

required in the population to rule out any ethnic differences. This would be beneficial to the laparoscopic surgeons in operating in this region.

C.H.D.- Common Hepatic Duct

L.C.- Laparoscopic Cholecystectomy

G.B.- Gall Bladder

**Conflict of interest:** The author has none to declare.

### References

1. Nuri A, Kama MK, Reis E, Atli M., Dolapci M. Risks Score for conversion from Laparoscopic to open cholecystectomy. *The American Journal of Surgery*.2001;181:520-5.
2. Singh K, Ohri A. Laparoscopic cholecystectomy. Is there a need to convert?. *J Min Access. Surg.* (2005);1:52-59.
3. Sahu SK, Agrawal A, Sachan PK. *Jurnalul de chirurgie (Iasi)*(2013),Vol 9;Nr 2:149-156.
4. Torres K ,chrościcki A, Goloxka A,Torres A., Staśkiewicz G, Palczak R, Ceja-Sanchez J M , Ceccarorii M, Drop A. The Course of the cystic artery during laparoscopic cholecystectomy . *Folia Morpho l (Waroz)*.(2009)Aug;68(3):140-3.
5. Abdalla S., Pierre S., Ellis H, Clir. *Anat.*(2013)May;26(4):493-501. doi:10.1002/ca.22170.Epub 2013 Mar 21.
6. Standring S. *Gray's Anatomy: The Anatomical Basis of Clinical Practice*.40<sup>th</sup> ed. New York; Elsevier.
7. Hollinshead NH. *Anatomy for surgeons: The Thorax, Abdomen and Pelvis*.2<sup>nd</sup> ed. New York ; Harper and Row:1971.
8. Rocko JM, Swan KG, DiGioia JM:” Calot’s Triangle revisited “. *Surgery, Gynecology & Obstetrics*;(1981) Vol.153, no.3.:410-414.
9. Sabiston *Textbook of Surgery. The Biological Basis of Modern Surgical practice*.18<sup>th</sup> e.d. Philadelphia. Saunders/ Elsevier:2018.



10. Bahlooli A, Hadi S et al. Conversion rate of laparoscopic to open cholecystectomy. YEMENI JOURNAL FOR MEDICAL SCIENCES,[S.I.](Dec.2009);3:3 .ISSN-227-961x.
11. Huang ZQ, Huang XQ. Changing Patterns of traumatic bile duct injuries .A review of forty years experience. World J Gastroenterol (2002);8:5-12.
12. Veen EJ,Bik M,Janssen-Heijnen ML,De Jough M,Roukema AJ.Outcome measurement in laparoscopic cholecystectomy by using a Prospective complication registry. Results of an audit.Int J Qual Healthcare (2008);20:144-51.
13. Way HW,Stewart L,Hunter JG."Causes and prevention of laparoscopic bile duct injuries". Ann.Surg.(2003) Apr;237(4): 460-69.
14. Singh K,Ohri H. Anatomical landmarks: their usefulness,in safe laparoscopic cholecystectomy.(2006) Surg.Endosc ;20:1754-1758.
15. Nagral S.Anatomy relevant to cholecystectomy.J Minim Access Surg.(2005);1(2):53-58.
16. Desilva M.,Ferriando D. . Anatomy of the Calot's triangle and its relevance to laparoscopic cholecystectomy. Ceylon med J(2001) mar:46(1):33-4.
17. Hugh TB, Kelly MD, Li B.Laparoscopic anatomy of cystic artery.Am J.Surg.1992. June;163(6):593-5.
18. Mlakar B.,Gadzijev EM,Ravnik D, Hriberni KM. Anatomical Variations of the cystic artery.Eur J Morphol. 2003Feb;41(1):31-4.
19. Chen TH.,Shyu JH,Chen CH, et.al. Variations of the cystic artery in Chinese adults. Surg .Laparosc Endosc. Perentan Tech .2000;10(3):154-157.
20. Kholdebarin R,Boetto J,Haruish JL, Urbach DR .Risk factors for bile duct injury during laparoscopic cholecystectomy: a case-Control study.Surg Innov. 2008;15(2):114-119
21. Flisińsici P, Szpinda M, Flisiriski M.The cystic artery in human fetuses.Folia Morphol;Vol.63,No.1 : 47-50.
22. Ahmed MK, Sylvania S.Origin of cystic artery and its position in relation to biliary ducts and calot's triangle . Journal of Evolution of Medical and Dental Sciences(2015);Vol.4;issue01,January 01:1-5.DOI:10.14260/jemdo/2015/,.
23. Toonli J. Surgery of the biliary tract . New York;Churchill hivingstone:1993.
24. Balija M, Huis M,Nikolic V,stulhofer M.Laparoscopic visualization of the cystic artery anatomy.World J Surg.1999 Jul;23(7):703-7,discussion 707.
25. Suzuki M,Akaishi S,Rikiyama T,Naitoh T,Rahman M M,Matsuno S (2000). Laparoscopic cholecystectomy , Calot's triangle, and variations in cystic arterial supply.Surg.Endosc;14:141-144
26. Michels NA. The hepatic,cystic and retro duodenal arteries and their relations to the biliary ducts with samples of the entire Coeliacal blood supply. Ann. Surg. (1951);33:503-524.
27. Rashid A, Mushtaq M, Bali RS , Nazir S,Suhail K and Ishaq S. Artery to cystic duct.A Consistent branct of cystic artery seen in laparoscopic cholecystectomy. Anatomy Research International (2015); Article I D 847812:3 .http://dx.doi.org/10.1155/2015/847812.