



Leiomyosarcoma of the IVC: A Case Report

Authors

Pravin Agarwal, Priya Ahire, Ali Zaid Anwar, Kushagra Rahul, Jaini Gala
GMC & JJH Mumbai, India

Abstract

The authors here report a case of 62 year old lady who had pain in right flank as the only symptom. Computerised tomography revealed a segment 2 IVC tumor. The patient underwent radical excision of the IVC mass with right nephrectomy and resection of right caudate lobe, and the specimen was later histopathologically proven to be of leiomyosarcoma.

Introduction

Leiomyosarcoma of the inferior vena cava (IVC) is a very rarely encountered disease, even though it is the most common tumor of the venous system, most frequently affecting the IVC and representing 5% to 10% of all soft parts sarcomas^(6,7). Mild, nonspecific abdominal pain is the most prevalent symptom, which the patient can have for months before a diagnosis is made⁽⁹⁾. It is mostly seen in the sixth decade of life, with predominance in women^(9,10). Complete surgical resection with negative margins represents the only chance for long term survival of the patient^(6,11).

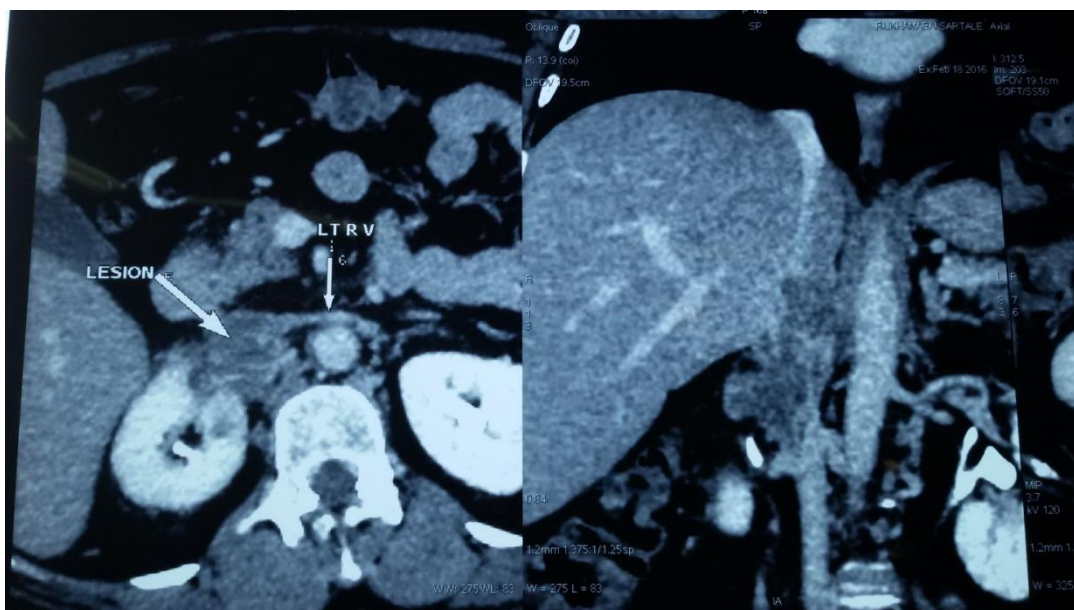
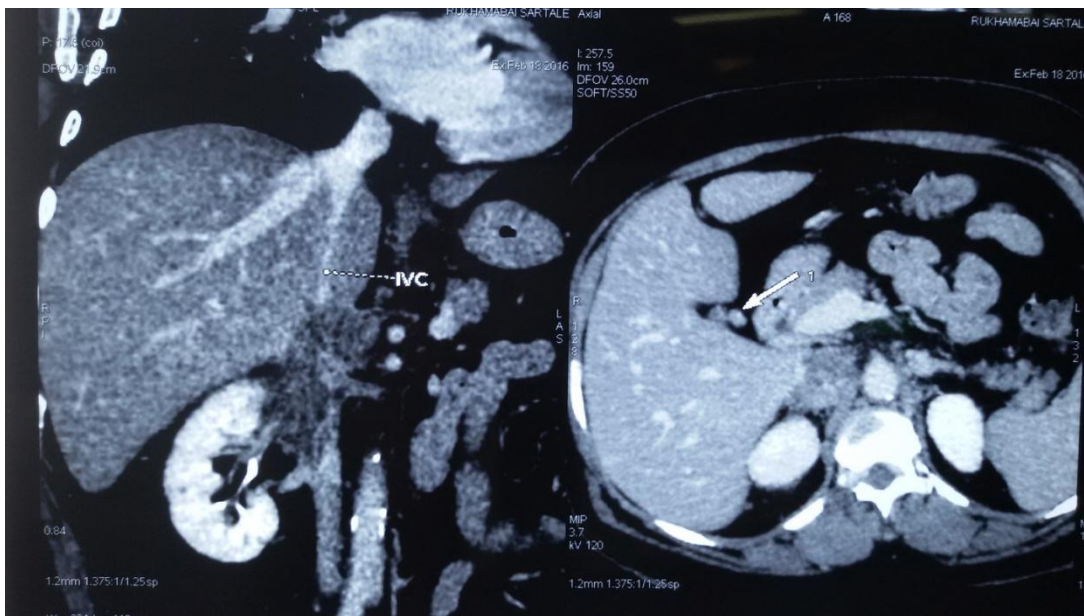
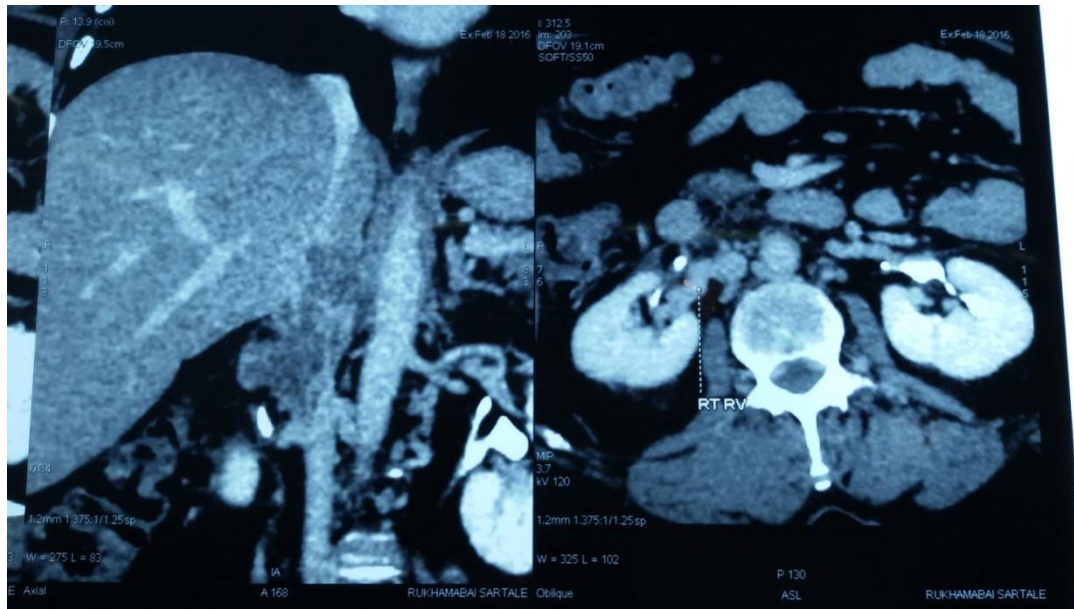
Radio and chemotherapy have not shown very promising results in terms of benefit to patient's survival.

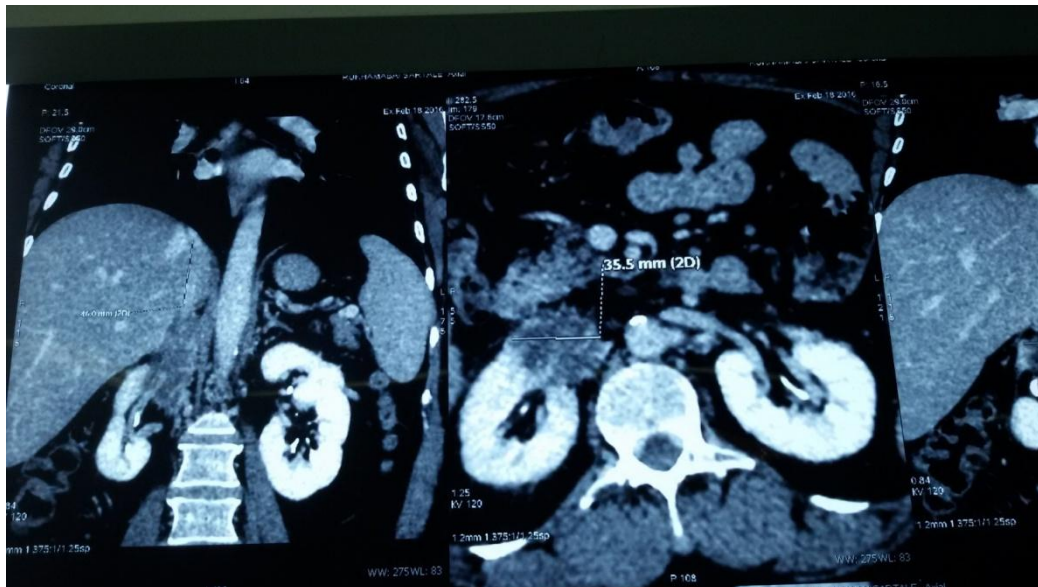
Case Presentation

62 years lady without any known co-morbidity, presented with pain abdomen in right lumbar region since six months, which was continuous, dull aching in nature and was non-radiating.

Abdominal ultrasonography (USG) showed a 4x4 cm mass near the right renal hilum extending into the IVC superiorly.

This was followed up with a Contrast enhanced computerized tomography (CECT) scan, which showed a well-defined minimally enhancing mass lesion measuring 7.6 x 3.6 x 3.5cm seen within the lumen of IVC. Proximal margin of the mass is 4.6cm caudal to hepatic vein- IVC confluence and distal margin is just at the right renal vein insertion into the IVC; anteriorly the mass is infiltrating into the inferior most aspect of caudate lobe of liver and abutting second part of duodenum, postero-medially it is abutting the right crus of diaphragm and coeliac ganglion, postero-laterally it is infiltrating into the upper pole cortex of right kidney and right suprarenal gland.

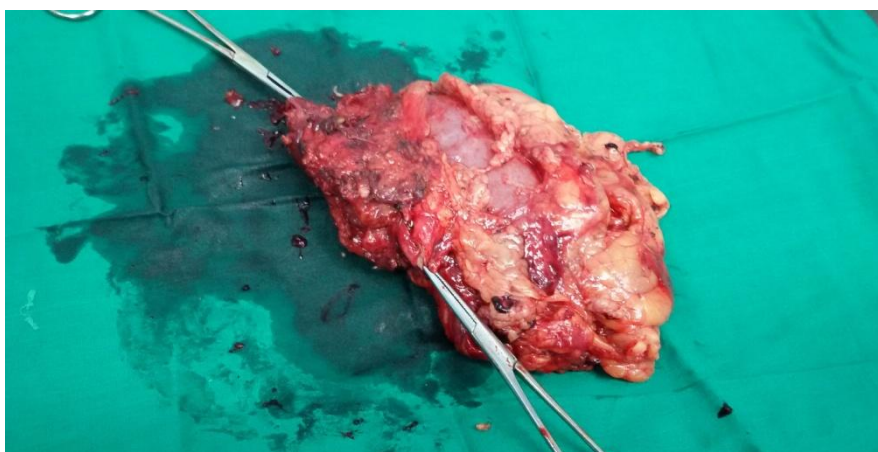
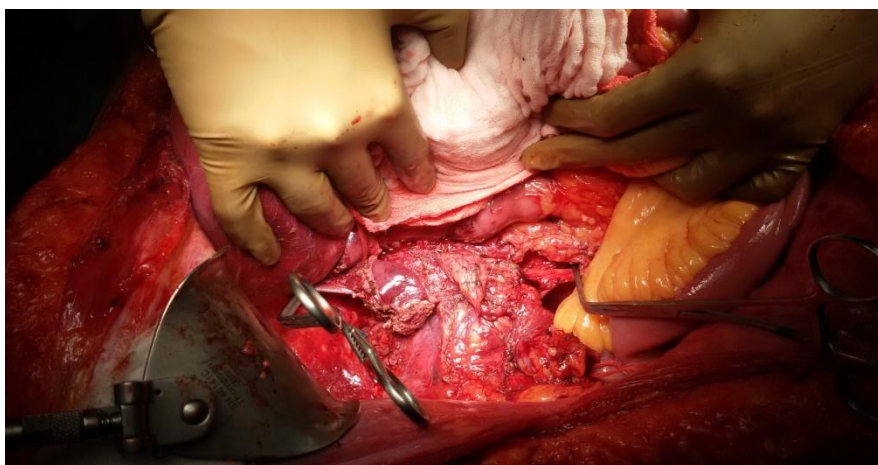




USG guided biopsy was done which IHC suggestive of leiomyosarcoma or sarcomatous sarcoma. A radical resection of the tumor was planned after ruling out distant metastasis via a positron-emission tomography.

IVC 2 cm below the opening of hepatic veins was divided and dissected out from the retrohepatic

portion, the right kidney along with the perinephric tissue, the adrenal glands, the proximal ureter, along with the right renal vein and renal artery was excised en-bloc. IVC was reconstructed with a PTFE graft



Discussion

Leiomyosarcoma of IVC is considered as the primary malignant tumor of IVC and is listed as rare disease by National organisation for rare disorder (NORD)^[1]. Based on the location the tumor is classified as segment 1 when the tumor is infrarenal, segment 2 when its inter and suprarenal up to the main suprahepatic veins but not involving the vein(s) and segment 3 is suprahepatic with or without intracardiac extension. Commonest of these are segment 2 leiomyosarcomas^[3]. Segment 2 and 3 type of tumor are the most difficult to manage operatively because of the adjacent organ involvement and complexities in vascular anatomy at this locations.^[2]

Patients presenting symptoms are pain in right flank, pain is mostly dull nonspecific and misleading which contribute to the delayed diagnosis and treatment. Other symptoms along with or without pain are Budd Chiari syndrome with hepatomegaly, ascites sometimes jaundice.^[2]

Edema of Lower extremities can be inconsistent as mentioned in their original article by Edouard Kieffer et al^[2]. This clinical finding can be explained by the fact that the paraspinal & lienorenal collaterals shunt the blood from IVC and renal veins into the systemic circulation which was a finding in our case too.

Abdominal ultrasound is the initial investigation, but CECT is needed to get details on anatomy and staging of the disease. In cases of diagnostic dilemma FNAC/ biopsy of the mass is warranted. Transesophageal echocardiography is needed in patients where intracardiac extension is suspected^[2].

Currently, for patients with no metastasis in initial presentation, optimal initial treatment strategy would be radical excision with adjuvant chemotherapy. Hines OJ et al^[4] in their series have mentioned regarding increase in the overall survival after receiving adjuvant radiation therapy, especially in segment 2 type of IVC leiomyosarcomas.

Overall survival in leiomyosarcomas is very poor, with newer techniques and advances in vascular, oncosurgery, chemotherapy and radiotherapy have given hope and helped prolonging the 5 year survival^[2,5]. Mingoli A et al^[5] in their series of 218 patients had a better 5 year survival rate of 49.4% and 29.5% 10 year survival in patients which underwent radical tumor resection. The group of patients with upper part of IVC involvement, lower limb edema on presentation, intraluminal tumor growth, complete IVC occlusion and Budd-Chiari syndrome had significantly poor overall survival rates^[5]. Our patient mentioned in the above case report had none of the these signs and symptoms.

Other series with fairly large number of patients and satisfactory follow-up given by Hines et al^[4], Hollenbeck et al^[3] and Edouard Kieffer et al^[2] after radical resection for intent to cure had actuarial survival rates at 5 years of 53.3 %, 33% and 34.8% respectively.

Thus, the natural course of IVC leiomyosarcomas is accompanied with very poor survival rates. Newer advances in surgical techniques and the fields of adjuvant therapy provides the only way of pushing the overall survival rates favorable for patients.

Conclusion

- 1) Upfront radical resection is one main component in optimal care in IVC leiomyosarcoma
- 2) Early identification ,accurate staging and accurately planning the course of treatment will improve the survival rates of patient
- 3) Obtaining a detailed venous anatomy pertaining to segment 2 of IVC is warranted with a venogram to view the status of collaterals which may impact in planning the procedure specially in vascular anastomosis.
- 4) Radical surgery and adjuvant therapy needs to be planned, which needs multidisciplinary team approach (Oncosurgeon, Vascular Surgeon, experienced Pathologist and Oncologist) which helps to gain maximum

tumour clearance while preserving organ resection hence increasing the survival rates

Reference

1. William B. Laskin. *Leiomyosarcoma, Inferior Vena Cava*. <http://rarediseases.org/rare-diseases/leiomyosarcoma-inferior-vena-cava/> (accessed 9 september 2016).
2. Edouard Kieffer, MD, Mustapha Alaoui, MD, Jean-Charles Piette, MD, Patrice Cacoub, MD, Laurent Chiche, MD. Leiomyosarcoma of the Inferior Vena Cava Experience in 22 Cases. *Annals of Surgery* 2006; 244(2): 289-295.
3. Hollenbeck ST, Grobmyer SR, Kent KC, et al. Surgical treatment and outcomes of patients with primary inferior vena cava leiomyosarcoma. *J Am Coll Surg*. 2003;197:575–579
4. Hines OJ, Nelson S, Quinones-Baldrich WJ, et al. Leiomyosarcoma of the inferior vena cava: prognosis and comparison with leiomyosarcoma of other anatomic sites. *Cancer*. 1999;85:1077–1083.
5. Mingoli A, Cavallaro A, Sapienza P, et al. International registry of inferior vena cava leiomyosarcoma: analysis of a world series on 218 patients. *Anticancer Res*. 1996; 16:3201–3205.
6. Imao T, Amano T, Takemae K. Leiomyosarcoma of the renal vein. *Int J Clin Oncol*. 2011;16:76–79.[PubMed]
7. Sokolich J, Mejia A, Cheng S, et al. Retroperitoneal leiomyosarcoma of the inferior vena cava mimicking a liver tumor. *Am Surg*. 2008;74:433–436. [Pub Med]
8. Cantwell CP, Stack J. Abdominal aortic invasion by leiomyosarcoma. *Abdom Imaging*. 2006;31:120–122. [PubMed]
9. Drukker L, Alberton J, Reissman P. Leiomyosarcoma of the inferior vena cava: radical surgery without vascular reconstruction. *Vasc Endovascular Surg*. 2012;46:688–690. [PubMed]
10. Sessa B, Iannicelli E, Caterino S, et al. Imaging of leiomyosarcoma of the inferior vena cava: comparison of 2 cases and review of the literature. *Cancer Imaging*. 2010;10:80–84. [PMC free article][PubMed]
11. Dew J, Hansen K, Hammon J, et al. Leiomyosarcoma of the inferior vena cava: surgical management and clinical results. *Am Surg*. 2005;71:497–501. [PubMed]