



Research Paper

Review of Practice and Complications of Intra Arterial Cannulation in a Tertiary Care Centre-An Observational Study

Authors

Dr Girijanandan D Menon, Mr Basil Paul, Dr Manjit George, Dr Shaloo Ipe

Department of Anaesthesiology, MOSC Medical College, Kolenchery, Kerala 682311

Corresponding Author

Dr Manjit George

Associate Professor, Department of Anaesthesiology, MOSC Medical College, Kolenchery 682311

Tel- 9447411536, Email: manjitgeorge@gmail.com

Abstract

Introduction: *Intra arterial cannulation is a common procedure performed in operating rooms and intensive care units. It aids in continuous monitoring of blood pressure and blood sampling for blood gas analysis. The present study was conducted to evaluate the practice of percutaneous arterial cannulation in our hospital, which is a rural tertiary care centre. Twenty five consecutive cases done over three months were evaluated for the study purpose. The indication for insertion and removal of intra arterial cannulation was noted. Associated complications, if any, during or after arterial line insertion and/or removal were noted.*

Background: *Arterial line placement is a common procedure in various critical care settings. Intra-arterial blood pressure (IABP) measurement is more accurate than measurement of blood pressure by noninvasive means, especially in the critically ill. Intra-arterial blood pressure monitoring permits the rapid detection of blood pressure changes that is vital for patients on continuous infusions of vasoactive drugs. Arterial cannulation also allows repeated arterial blood gas samples to be drawn without injury to the patient.*

Aim of the study: *To assess the practice and complications associated with intra arterial cannulation in a tertiary care centre*

Study Design: *Observational study over a period of three months*

Methods: *25 consecutive cases of intra arterial cannulation were assessed regarding the indications and associated complications if any.*

Results: *Beat to beat observation of blood pressure, use of ionotropes and arterial blood sampling together constituted 48 % of all the indications for intra arterial cannulation. Kinking and or displacement of cannula together formed 48% of the complications, resulting in intra arterial line removal. Haematoma was noted in 16 % cases, while pain and swelling was reported by 4-8% patients.*

Conclusion: *Intra arterial blood pressure monitoring, for all its accuracy and reliability, is associated with minimal complications.*

Keywords: *arterial cannulation, indications, techniques, complications.*

Introduction

Percutaneous radial artery cannulation is a well established procedure that is commonly used in the operating room and the intensive care unit. Physicians performing vascular access procedures require an understanding of the relevant anatomy and awareness of potential complications. Arterial lines are used extensively within critical care and perioperative departments for continuous blood pressure monitoring and for obtaining serial blood samples, preventing the patient from having multiple blood draws. The first recorded cannulation of an arterial blood vessel was performed in 1714 by the English Reverend, Stephen Hales¹. The first description of arterial cannulation in a human occurred in 1856, when the blood pressure was measured in the femoral artery. Continuous recording of arterial blood pressure during the perioperative period with small plastic catheters was first described in 1949 by Peterson who inserted them into the brachial artery through a metal needle. Arterial monitoring allows uninterrupted display of pulse contour and continuous real-time heart rate and blood pressure measurement. The intra-arterial catheter is inserted percutaneously via a superficial arteries, including radial, ulnar, brachial, axillary, and less frequently, the dorsalis pedis and temporal vessels. The radial artery is preferred for securing arterial blood and for cannulation to provide continuous blood pressure (IABP) monitoring and arterial blood sampling (ABG)². If the radial artery cannot be cannulated, the femoral artery offers a viable alternative.

Aim of the study

To review the practice of intra arterial cannulation.

Objective

1. To study the indications for arterial line cannulation and its removal
2. To study the complications of the arterial line cannulation

Materials and Methods

The present study was conducted in our institution, during the period of August 2014 to October 2014. Under aseptic precautions radial artery was cannulated after confirming collateral circulation on the side selected. Non safety 20 gauge cannula or Jelco intraarterial catheter was used for the cannulation in all cases.

Technique of radial artery cannulation

Commonly used techniques are Seldinger technique and Catheter over needle method. In this study catheter over needle method was used as the sets for Seldinger technique is not available in our institution. The procedure was explained to the patient and informed consent obtained. Appropriate sedation and analgesia were given in all cases before arterial cannulation. The patient's wrist was hyperextended and held in place with an arm board and gauze dressing so that the wrist is exposed and facing the roof. The hyperextension of the wrist brings the radial artery more superficial and increases success rate.

The catheter over needle method

The catheter-over-needle approach, the most basic method for placing an arterial line was used^{3,4}. Similar to peripheral intravenous (IV) cannula placement, a needle with an integrated catheter is placed into the arterial lumen, and the catheter is advanced over the needle. This technique is best suited for use when the artery is located superficially, as is the case with the radial artery which is the preferred method for arterial cannulation.

For the catheter-over-needle approach, the artery is identified by palpation. The area is cleaned with povidone-iodine or chlorhexidine, and sterile drapes are used. The artery is palpated with the second and third digit of non dominant hand. And one to two ml of lidocaine 1% without epinephrine is injected at the site of insertion. The anatomy is not distorted with a significant skin wheal. The skin is punctured proximal to our fingers over arterial pulsations, advancing the needle at a 30-45° angle toward the pulsation with its bevel facing up. If the artery is not punctured,

needle is withdrawn back to the skin before repositioning the needle. The hub of the needle is observed for a flash of bright red blood, signifying arterial puncture. Once a flash has been obtained, the needle-catheter assembly is lowered to an angle of 10-20° from the skin and the needle inserted 1-2 mm further to advance the catheter into the lumen of the artery. The needle is stabilised and the catheter is advanced over the needle into the artery until the hub is at the level of the skin. If any resistance is felt, the needle is repositioned until free blood flow is obtained, and then tried to advance the catheter. The catheter is never pulled back over the needle, which may

shear the catheter tip and lead to embolization of the catheter or a foreign body in the subcutaneous tissues. After the catheter has been advanced into the artery, the needle is removed and the catheter is attached to an appropriate arterial line tubing.

Results

A total of 25 cases were analysed over a period of three months from 1 August 2014 to 31 October 2014 at our hospital. Frequency and percentage are computed to describe the indications for arterial cannulation, indication for arterial line removal and complication of arterial line cannulation

Indications for arterial line cannulation

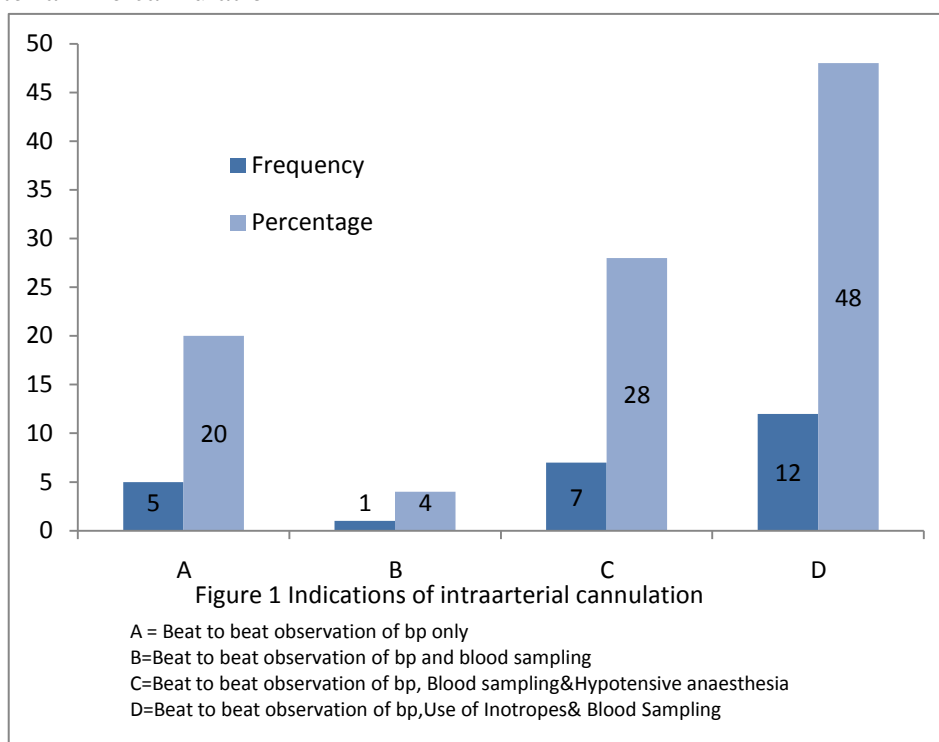


Figure 1

As shown in the above graph almost half of the patients (48%) had intra arterial line placement for beat to beat observation of blood pressure and titration of ionotropes and blood sampling. Twentyeight percent of patients had arterial line for beat to beat observation of blood pressure,

hypotensive anaesthesia and blood sampling while twenty percent of patients had arterial line for beat to beat observation of blood pressure and blood sampling. In the remaining four percent, beat to beat observation of blood pressure alone was monitored.

Indications for arterial line removal

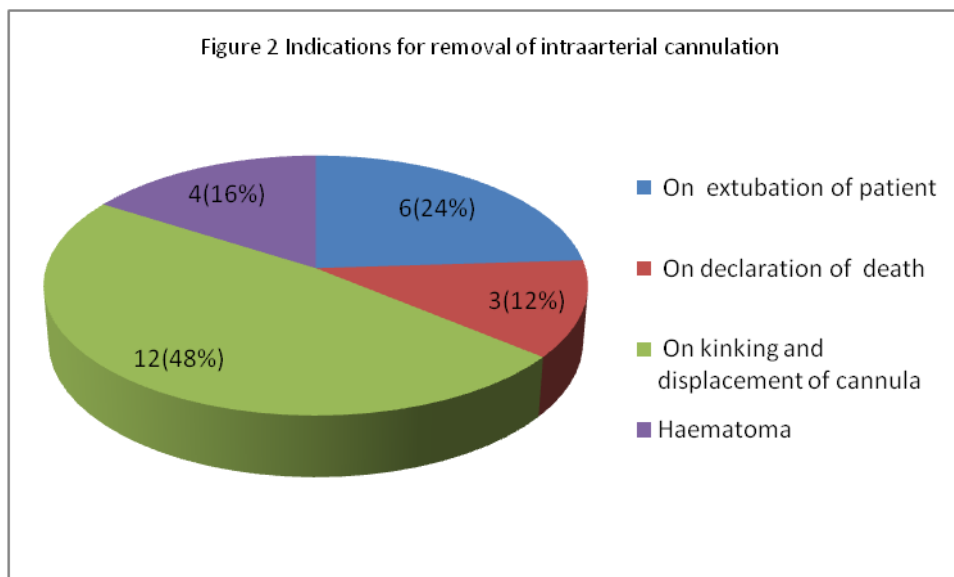


Figure 2

In about half the patients (48%) arterial line cannula was removed due to kinking and displacement. In 24% arterial line cannula was

removed upon extubation of patients. In 16% of patients cannula was removed because of hematoma and in 12% upon on death of patients.

Complications of arterial line cannulation

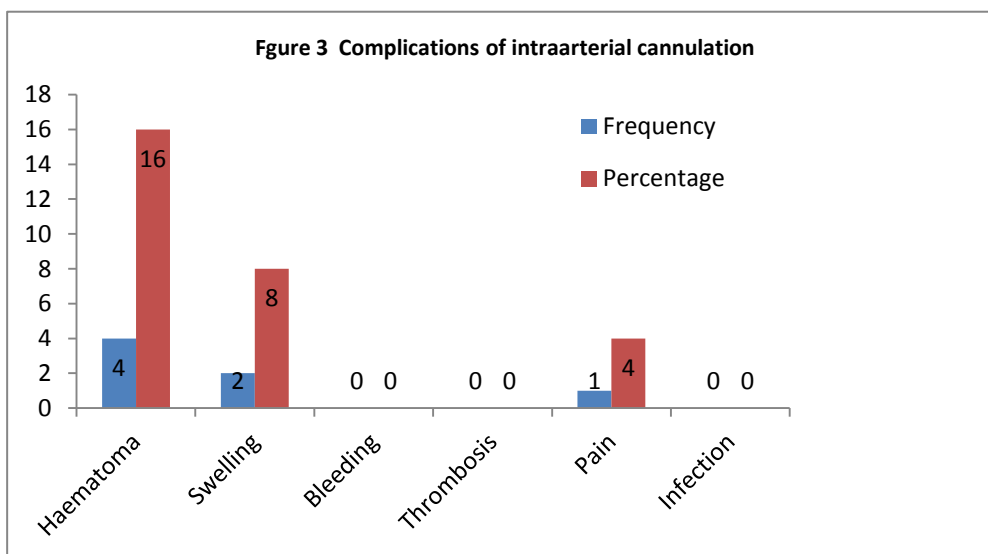


Figure 3

In majority of participants (72%) had no complications reported following intra arterial line cannulations. In 16% of patients intra arterial line complication was due to haematoma. Eight percent of patients had swelling at site of insertion and only 4% reported pain. Other complications are bleeding and thrombosis but these were not reported in this study.

Discussion

Intra arterial cannulation for invasive beat to beat monitoring of blood pressure is a popular technique among anaesthesiologists⁵. This invasive monitoring is commonly used in neurosurgery, neonatal and cardiac icu and in operating rooms where high risk patients are taken up for surgery and anaesthesia. As patients with various comorbidities undergo surgery after early optimization, arterial blood pressure monitoring is

essential for preventing complications due to likely haemodynamic changes and ventilation perfusion mismatch occurring perioperatively⁶. Haemodynamic changes due to the position of the patient during shoulder surgery and neuro surgery, various organ transplant surgery, needing massive transfusion, prolonged cosmetic surgeries, laparoscopic surgery, cardiac surgery and cases where hypotensive anaesthesia are employed mandates intraarterial blood pressure monitoring. Radial artery is the most preferred site, due to the excellent collateral supply of ulnar artery and palmar arch⁷. Contraindications to intra arterial cannulation include peripheral arterial diseases such as thromboangitis obliterans, infection at the site of insertion and full thickness burns². Large multi centric studies have reported very low incidence of complications associated with intra arterial cannulation. The commonly reported complication of intra arterial cannulation include bleeding, haematoma, nerve damage, thrombosis, infection etc⁶. Critical factors in reducing complications were short period of cannulation, use of a Teflon catheter, and a continuous arterial line flush system⁸. Evidence suggest that female sex and preoperative use of clopidogrel were potential predictors of arterial line complications. Catheter diameter size, catheter length, catheter composition or type, number of puncture attempts, and duration of arterial cannulation are associated with an increased risk of an arterial and/or limb injury .Risk factors for complications of arterial cannulation listed by Lipira *et al.* were the use of vasopressors, previous injury to the artery, duration of cannulation (over 48 or 72 h), hematoma, disseminated intravascular coagulation, reduced cardiac output, and the female sex⁹. Multiple attempts at cannulation can increase the chance of haematoma, arterial injury, pseudo aneurysm formation and nerve damage. The size of cannula used can be another factor related to complications. The duration of intra arterial cannulation has a positive association with infection. Techniques of intra arterial cannulation can be 2 types- Seldinger technique/ modified

Seldinger (catheter over wire) and catheter over needle technique. Superiority of Seldinger technique is clearly evident from the literature. In this study catheter over needle technique was used by anaesthesiologists, owing to non availability of set used for Seldinger technique. Intra arterial blood pressure offers beat to beat blood pressure monitoring and is not subject to artefacts such as shivering or arrhythmias. The radial artery cannulation is a low risk high benefit method of monitoring which needs wide clinical use¹⁰. None of the participants in this study developed limb ischaemia since limb was selected based on arterial competency using modified Allen's test. No case of temporary radial artery occlusion was recorded since frequent dilute heparin saline(1 unit /ml) flushing was employed in all cases.

In all patients the cannula was not retained more than 24 hours thus reducing infection and sepsis. The most common cause of removal of cannula was kinking and displacement .This might be due to handling during transport to postoperative care units or poor quality fixing of the cannulae or on repeated blood sampling and haematoma formation.

Limitations

Standard sized, 20 G cannulas are used in our hospital. Hence, the relationship between size of cannula and the complications were not assessed. We did not study the duration of intra arterial cannulation, as it was a cross sectional observational study. The number of attempts at arterial cannulation was not assessed. The duration of intra arterial cannulation and number of attempts have a positive association with incidence of complications. Meaningful conclusions should be drawn with caution, as the sample size studied was small. The comparatively high incidence of complications could also be attributed to this small sample size.

Conclusion

Arterial lines are used for continuous blood pressure monitoring and help to prevent the

patients from having blood sampling from multiple sites. Intra arterial blood pressure measurement is more accurate than measurement of blood pressure by non-invasive means especially in the critical ill patients. The complications of arterial line cannulation are haematoma, swelling, bleeding and thrombosis and the incidence of these are rare.

In our study, a total of 25 cases were analyzed the rate of major complications was below 18%. Seventy two percent of patients had no complication reported after arterial line cannulation. Overall, arterial cannulation is a safe procedure and should be recommended on a case by case basis.

Sources of support- Nil

Bibliography

1. Hales S. Statical Essays: Haemastatics. Innys; 1740. 422 p.
2. Tiru B, Bloomstone JA. Radial Artery Cannulation: A Review Article. J Anesth Clin Res [Internet]. 2012 [cited 2018 Jun 1];03(05). Available from: <https://www.omicsonline.org/radial-artery-cannulation-a-review-article-2155-6148.1000209.php?aid=6615>
3. Adsumelli RSN, Steinberg ES, Schabel JE, Saunders TA, Poppers PJ. Sequential compression device with thigh-high sleeves supports mean arterial pressure during Caesarean section under spinal anaesthesia. Br J Anaesth. 2003 Nov;91(5):695–8.
4. Arterial Line Placement Technique: Approach Considerations, Allen Test, Catheter-Over-Needle Technique [Internet] [cited 2018 Jun 1]. Available from: <https://emedicine.medscape.com/article/1999586-technique>
5. Arterial Line Placement: Background, Indications, Contraindications. 2018 Mar 26 [cited 2018 Jun 3]; Available from: <https://emedicine.medscape.com/article/1999586-overview>
6. Scheer BV, Perel A, Pfeiffer UJ. Clinical review: Complications and risk factors of peripheral arterial catheters used for haemodynamic monitoring in anaesthesia and intensive care medicine. Crit Care. 2002;6(3):199–204.
7. Cousins TR, O'Donnell JM. Arterial cannulation: A critical review. :5.
8. Mandel MA, Dauchot PJ. Radial artery cannulation and complications in 1,000 patients: Precautions. J Hand Surg. 1977 Nov 1;2(6):482–5.
9. Nuttall G, Burckhardt J, Hadley A, Kane S, Kor D, Marienau MS, et al. Surgical and Patient Risk Factors for Severe Arterial Line Complications in Adults. Anesthesiol J Am Soc Anesthesiol. 2016 Mar 1;124(3):590–7.
10. Slogoff S, Keats AS, Arlund C. On the safety of radial artery cannulation. Anesthesiology. 1983 Jul;59(1):42–7.