

**Case Report**

## Kienbock's disease, Avascular Necrosis of Lunate: A Clinico-anatomical Insight

Authors

**Dr Jasbir Kaur (MD, DNB, MNAMS)<sup>1</sup>, Dr Davinder Singh (MS, DNB, MNAMS)<sup>2\*</sup>  
Dr Mangala Kohli (MD, Anatomy)<sup>3</sup>**

<sup>1</sup>Associate Professor, Department of Anatomy, VMMC and Safdarjung Hospital, New Delhi-110029  
Email: [drjasbirspall@gmail.com](mailto:drjasbirspall@gmail.com), Telephone: 9650441064

<sup>2</sup>Professor of Orthopaedics, Central Institute of Orthopaedics, VMMC and Safdarjung Hospital, New Delhi-110029

Email: [davinderdr@gmail.com](mailto:davinderdr@gmail.com), Telephone: 9810882861

<sup>3</sup>Director Professor and Head, Dept of Anatomy, VMMC and Safdarjung Hospital, New Delhi-110029  
Email: [mangalakohli1@gmail.com](mailto:mangalakohli1@gmail.com)

\*Corresponding Author

**Dr Davinder Singh**

VMMC &amp; Safdarjung Hospital, New Delhi, India

**Abstract**

*Kienbock's disease or lunatomalacia is a specific and very rare form of osteonecrosis affecting the lunate bone due to disruption of blood supply. The disease, rarely bilateral mainly affects young males, predominantly manual workers. The disease is manifested as insidious, progressive dorsal wrist pain surrounding lunate bone with or without associated swelling. The patient may provide a history of trauma prior to the appearance of signs and symptoms. Though, the underlying mechanisms of disease are highly controversial, all of them result in compromised blood flow leading to bone infarction and mechanical failure. Thus, emphasizing the importance of in depth knowledge of vascular anatomy of the bone. The diagnosis is based on high clinical suspicion along with radiography and MRI scanning. Modalities of treatment include immobilization with splinting or casting, mechanical unloading of lunate leading to spontaneous revascularization, bone graft procedures, proximal row carpectomy, joint replacement and carpal bone fusion in advanced cases<sup>[1]</sup>. The present report highlights a case of Kienbock's disease in a seventeen year old female, student by profession, with history of trauma and painful wrist movements. Wrist arthroscopy, newest therapeutic modality was performed and multiple drilling of lunate was done.*

**Keywords:** lunatomalacia, Osteosclerosis, Avascular necrosis, Kienbock's disease.

**Introduction**

Kienbock's disease was first described by Austrian radiologist Robert Kienbock in 1910, as traumatic malacia of the carpal bone resulting in

the interruption of arterial supply to the bone<sup>[2]</sup>. It is a form of osteonecrosis characterized radiologically by sclerosis, cystic changes, fragmentation and articular surface collapse<sup>[3, 4]</sup>.

As the etiology of the condition is unknown and similar symptomatology is observed in scapholunate sprain, lunate fracture or lunate dislocation, the management becomes highly controversial posing a challenge to orthopaedic surgeons. The delayed diagnosis might compromise the prognosis of the disease and thus lead to further deterioration. The present report describes a case of Kienbock's disease in a seventeen year old female student presenting with pain and difficulties in wrist movements.

The aim of this case report is to highlight the role of arthroscopy as newer modality in diagnosis and treatment of Kienbock's disease along with emphasis on vascular anatomy.

### Case Report

A seventeen year old female, student had presented with a history of injury to the wrist six months back. She had taken treatment from a local practitioner three months after the incident of injury. The patient developed pain which was dull and constant in character, present throughout the day and exacerbated by wrist movements with special reference to dorsiflexion. On examination there was no swelling, scar and sinus. Tenderness was present on the dorsum of wrist in the region of lunate bone. Dorsiflexion was limited, painful at the extreme. X-rays of the wrist revealed osteosclerosis and minimal fragmentation of the lunate bone. Gilula lines and scapholunate distance was maintained. There was negative ulnar variance. MRI of the wrist confirmed the diagnosis of Kienbock's disease. Arthroscopic wrist examination was performed and multiple drilling of lunate was performed.

### Anatomy and Vascularisation

The lunate bone, semi lunar in shape, distinguished by deep concavity and crescentic outline is situated in the centre of the proximal row carpal bones articulating with scaphoid laterally, triquetral medially and capitate distally. The bone receives blood supply from the palmar and dorsal branches of the radial and ulnar artery.

The dorsal aspect receives the supply from the dorsal intercarpal arch and dorsal branch of the interosseus artery. The palmar surface receives blood supply from the palmar intercarpal arch, palmar radiocarpal arch, communicating branches from anterior interosseus artery and ulnar recurrent artery<sup>[6]</sup>. The palmar supply got contribution from anterior interosseous artery in 72.2% and a branch from palmar intercarpal arch in 69.44% of the cases. The dorsal supply came from anterior interosseous branch in 85.71% and dorsal branch from dorsal intercarpal arch in 50% of specimens<sup>[7]</sup>. The dorsal and volar arterial systems anastomose distal to the mid line of the bone, thus the proximal part being less vascular and more prone to post traumatic avascular necrosis [8]. Moreover, as the blood supply of the bone comes along with various ligaments including scapholunate interosseus ligament, lunotriquetral interosseus ligament and radioscapocapitate ligament, any trauma or strain resulting in tear of these ligaments might disrupt the blood supply to the carpal .

The etiology of the disease remains controversial<sup>[3,4]</sup> and involves biomechanical, traumatic, vascular and anatomical factors. These factors ultimately result in microfractures of the lunate trabecula. Further the disease may deteriorate and cause degenerative changes with progressive collapse of the bone. The most common underlying mechanical factor is the negative ulnar variance. Shortening of ulna, not able to withstand axial loads with radius transmits increased compressive forces from the radius and capitate to the lunate <sup>[4, 8, 9]</sup>. It has been reported that the prevalence of negative ulnar variance in patients with Kienbock's disease is 50-87%<sup>[8]</sup> as compared to the general population with an incidence of 26%<sup>[10]</sup>.

Trauma is another important underlying factor for the necrosis of the lunate. Injury results in rupture of the ligaments related to the bone including scapholunate intersosseus, lunotriquetral interosseus and radioscapocapitate ligaments disrupting the nutrient arteries supplying the bone.

The disruption of venous outflow might also result in the necrosis. Intraosseous pressure within necrotic lunates was found to be much higher compared with the normal ones suggesting impairment of venous outflow<sup>[11]</sup>.

Various other pathologies implicated in Kienbock's disease include septic emboli, sickle cell disease, gout, carpal coalition, corticosteroid use and cerebral palsy<sup>[1]</sup>.

Lichtman classified Kienbock's disease into four stages depending upon necrosis and rotation of lunate. The treatment modalities aiming to relieve the pressure on the bone involve both conservative and surgical modalities, depending upon symptomatology, functional deficits and Lichtman's classification<sup>[4,5]</sup>. Conservative

management includes immobilization with splinting or casting<sup>[1,4,5,12]</sup>. Traditional surgical interventions included radial osteotomy, vascularized bone grafting, carpectomy and total wrist arthrodesis. Arthroscopy lately has been used for diagnosis as well as therapeutic management of the Kienbock's disease.

Arthroscopy allows direct visualization of diseased bone with minimal morbidity. Drilling of lunate works on same principles similar to those involved in avascular necrosis of femoral head theoretically enhancing the blood supply. The present case report is unique as the disease was diagnosed arthroscopically and the drilling of lunate was done the help of arthroscope under vision.

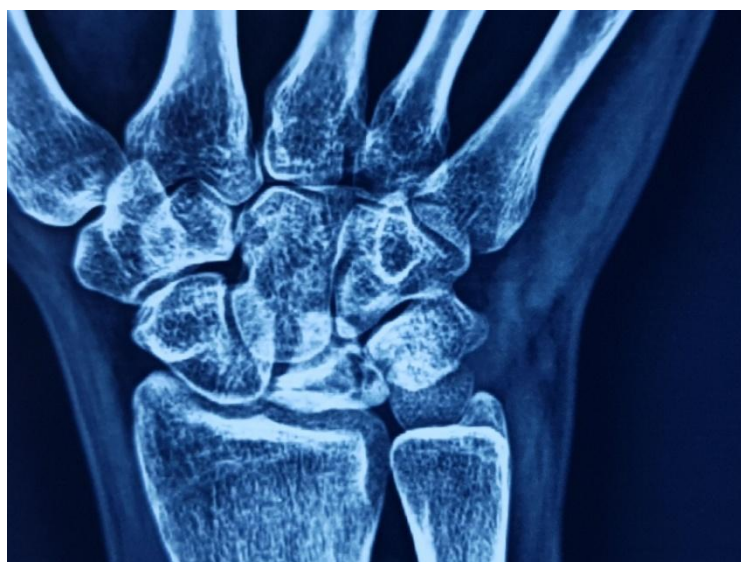

Figure 1: AP view of wrist xray showing Kienbock's Disease of lunate

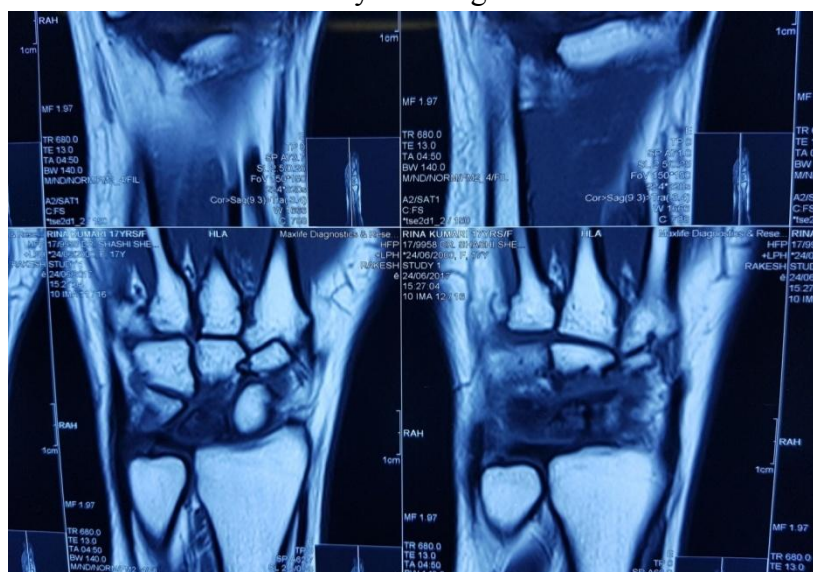


Figure 2: MRI showing involvement of lunate bone.

### Discussion

Kienbock's disease commonly affects adult males between the age group of twenty to forty years, is rarely bilateral with a male to female ratio of 9:1<sup>[5]</sup>. Patients in early stages may not consult a medical practitioner and thus the actual incidence of the disease is unknown. The pathology predominantly affects the manual workers as they tend to sustain repetitive trauma to the carpal bones including lunate. The trauma may disrupt the ligaments around the bone. As the blood supply to the bone comes along with these ligaments, injury in the particular area may result in compromised blood supply and necrosis of the bone. Collapse of the lunate bone occurs with progression of disease<sup>[3, 4]</sup>. A history of trauma prior to the appearance of signs and symptoms is frequently reported. The symptoms of pain in the region of the carpal bone with limited range of wrist movements especially dorsiflexion are the main complaints of the patient. Grip strength and wrist movements may be impaired or weakened due to pain.

### Bibliography

1. Litchman DM, Mack GR, Mac Donald RJ, Gunther SF, Wilson JN, Kienbock's disease: The role of silicone replacement arthroplasty J bone Joint Surg Am 1977 59: 899-908.
2. Kienbock R, Concerning traumatic malacia of the lunate and its consequences: Degeneration and compression fractures Clin Orthop Relat Res 1980 9: 4-8. (Pubmed).
3. Lamas C, Carrera A, Proubasta I, Ilusa M, Majo J, Mir X, The anatomy and vascularity of the lunate: Considerations applied to Kienbock's disease Chir Main 2007 26: 13-20.
4. Schuind F, Eslami S, Ledoux P, Kienbock's disease J bone joint Surg (Br) 2008 90(2): 133-9.
5. Beredjikian PK, Kienbock's disease (Internet) J Hand Surg 2009 Jan 34(1): 167-75(Pubmed).
6. Botte MJ, Pacelli LL, Gelberman RH, Vascularity and osteonecrosis of the wrist Orthop Clin North Am 2004 35(3): 405-21.
7. Dubey PP, Chauhan Nk, Siddiqui MS, Verma AK, Study of vascular supply of lunate and consideration applied to Kienbock's disease Hand Surg 2011 16(1): 9-13.
8. Gelberman RH, Salamon PB, Jurist JM, Posch JL, Ulnar variance in Kienbock's disease J bone Joint Surg (Am) 1975 57(5): 674-6. (Pubmed).
9. Chung KC, Spilson MS, Kim MH, Is negative ulnar variance a risk factor for Kienbock's disease? A metaanalysis. Annals Plastic Surg 2001 47(5): 494-9. (Pubmed)
10. Armistead RB, Linchield RL, Dobyns JH and Beckenbaugh RD, Ulnar lengthening in the treatment of Kienbock's Disease J Bone and Joint Surg 1982 64 a: 170-178.
11. Schiltenswolf M, Martini AK, Mau HC, Eversheim S, Brocai DRC, and Jensen CH, Further investigations of the intraosseous pressure characteristics in necrotic lunates J hand Surg (Am) 1996 21: 754-758.
12. Keith PP, Nuttall D, Trail I, Long term outcome of nonsurgically managed Kienbock's disease J hand Surg 2004 29 (1) 63-66.